



Celiac Artery Compression Syndrome, Case Report

Walter Camilo Mera Romo^{1*}; Juan Pablo Pérez Daza⁴; Karen Yuliana Ramírez Iriarte¹; Sebastian Felipe Navarro Téllez³; Wilmer Aponte Barrios²; Carlos Alfonso Cortes Ortega²

¹Radiology Resident, Department of Diagnostic Imaging, School of Medicine, Universidad Nacional de Colombia, Hospital Universitario Nacional de Colombia, Bogotá D.C. Colombia.

²Radiologist, Department of Diagnostic Imaging, School of Medicine, Universidad Nacional de Colombia, Hospital Universitario Nacional de Colombia, Bogotá D.C. Colombia.

³General Surgery Resident, School of Medicine, Universidad Nacional de Colombia.

⁴Medicine Intern, School of Medicine, Universidad Nacional de Colombia.

***Corresponding Author(s): Walter Camilo Mera Romo**

Department of Diagnostic Imaging, Universidad Nacional de Colombia, Hospital Universitario Nacional de Colombia, Bogotá, D.C. Colombia.
Tel: 57+3146282627; Email: wmera@unal.edu.co

Abstract

Background: Median arcuate ligament syndrome (MALS) is defined by the clinical presentation and radiological findings of compression of the celiac trunk by the median arcuate ligament. The diagnosis is controversial, and generally one of exclusion due to poorly understood pathophysiological processes, variable clinical severity, and unpredictable response to treatment.

Case presentation: to report a case of a 53-year-old man with chronic abdominal pain, imaging evidence of compression of the celiac trunk by ultrasound, tomography, taken to multidisciplinary management for release of the arcuate ligament.

Conclusions: MALS is the most common vascular compression syndrome with significant morbidity. Imaging modalities document and characterize the typical findings, and are considered paramount in the diagnosis and management of this disease.

Received: Dec 17, 2022

Accepted: Jan 07, 2023

Published Online: Jan 09, 2023

Journal: Journal of Case Reports and Medical Images

Publisher: MedDocs Publishers LLC

Online edition: <http://meddocsonline.org/>

Copyright: © Mera Romo WC (2023). *This Article is distributed under the terms of Creative Commons Attribution 4.0 International License*

Keywords: Median arcuate ligament syndrome; Celiac artery stenosis due to compression of the median arcuate ligament of the diaphragm; Celiac artery compression syndrome; Celiac trunk compression syndrome; Dunbar's syndrome; Case report.

Abbreviations: ALT: Alanine Aminotransferase; AST: Aspartate Aminotransferase; CTA: Computed Tomography Angiography; HIV: Human Virus immunodeficiency; MAL: Median Arcuate Ligament; MALS: Median Arcuate Ligament Syndrome; PT: Prothrombin Time; PTT: Thromboplastin time; TSH: Thyroid Stimulating Hhormone; T4: Thyroxinereport.



Background

The Median Arcuate Ligament (MAL) is a strong arch-shaped fibromuscular structure that joins the diaphragmatic pillars with the anterior margin of the aortic hiatus, typically at the level of the T12-L1 vertebrae, generally located above the origin of the celiac trunk. During inspiration, MAL moves ventrally and the celiac trunk presents a caudal displacement, manifested as a tendency to decrease celiac artery compression during deep inspiration and to increase compression during expiration. Due to anatomical variants, MAL can be abnormally located below the celiac trunk in up to 24% of patients. In a smaller group of these patients, the descent of the MAL during expiration inclines and compresses the celiac trunk, causing hemodynamic changes that can lead to intestinal angina. This presentation, along with important diagnostic imaging findings, make up the Median Arcuate Ligament Syndrome (MALS) [1,2].

MALS, also known as celiac artery compression syndrome or Dunbar syndrome, is the most common of the abdominal vascular compression syndromes according to the European Society of Vascular Surgery (ESVS). It was described in 1917 by Lipshutz in cadavers, and later Harjola reported a clinical case of chronic abdominal pain due to ischemia, with clinical improvement after decompression of celiac artery by a fibrous celiac ganglion. Later, Dunbar et al. 1965 reported a series of cases and described the surgical approach to decompression [3-8].

The pathophysiological process of MALS arises from the close relationship and compression of this fibrous band to the celiac plexus. There is a greater predisposition in patients with high origin of the celiac trunk and lower insertion of the diaphragm, long diaphragmatic pillars and MAL, large and fused celiac nodes or a combination of the above [7,8].

Although its epidemiology isn't well-known, It predominates in women in a 2:1 to 3:1 ratio and appears most commonly between 20-50 years, with an incidence of 2/100,000 patients [4,7,8]. Main symptoms include abdominal pain (91%), classically of postprandial onset (62%) or after physical exercise (32%), although it may be unprovoked (33%). Additionally, they may present unintentional weight loss, nausea, vomiting and epigastric murmur on auscultation (amplified on expiration). Psychiatric disorders have been reported to be associated, especially anxiety disorder in up to 46% of patients [2,7].

Case presentation

A 52-year-old man presented to the emergency department due to acute exacerbation of a 4-year clinical history of non-specific abdominal pain, both postprandial and unprovoked. Additionally, he reported unintentional weight loss related to hyporexia and early satiety. He referred history of L5-S1 disc herniation with neuroforaminal involvement and open splenectomy 25 years ago (1997) secondary to an infectious process that he wasn't able to precise. He referred no other relevant history.

He was referred to our institution from a lower-complexity health center with a diagnostic suspicion of median arcuate ligament syndrome. His laboratory tests on admission were normal as complete blood count showed no anemia (17.4 gr/dl Haemoglobin and 52.3% hematocrit), leukocyte (7850 x10⁹/L), nor platelet count anomalies (424,000 x10⁹/L). He also had normal total bilirubin (0.37 mg/dL), ALT (31.5 U/L), AST (64.7 U/L), alkaline phosphatase (75 U/L), serum creatinine (0.65 mg/dL), urea nitrogen (10 mg/dL) values, as well as normal sodium,

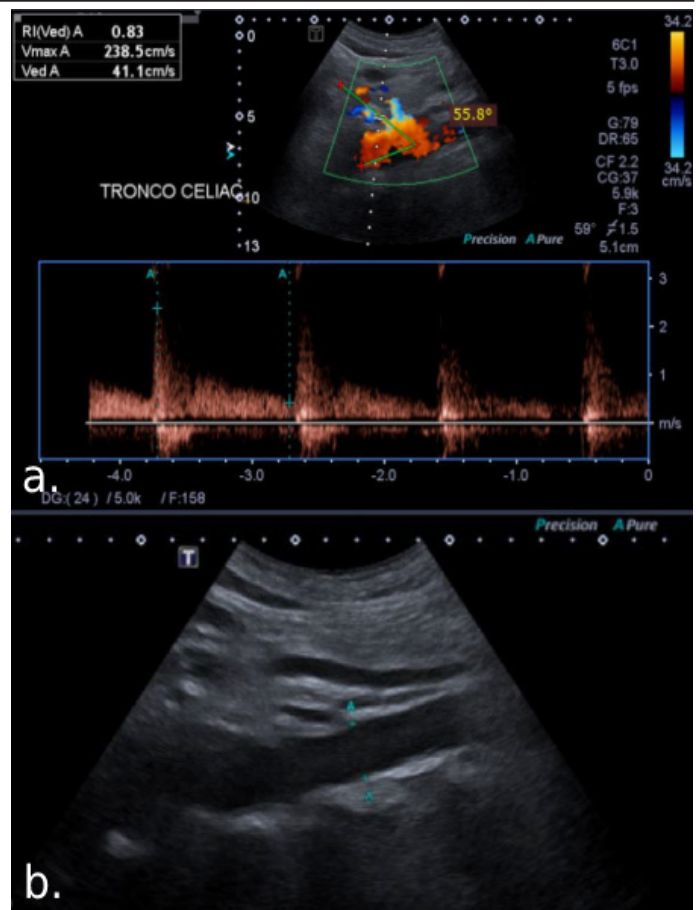


Figure 1: (a). Duplex ultrasound, peak systolic velocity of the celiac trunk in deep expiration of 238cm/sec and aorto-celiac trunk angle increased by 55%. (b). In B-mode, no calcified atherosclerotic plaques, aneurysmal dilations, or areas of stenosis were observed.

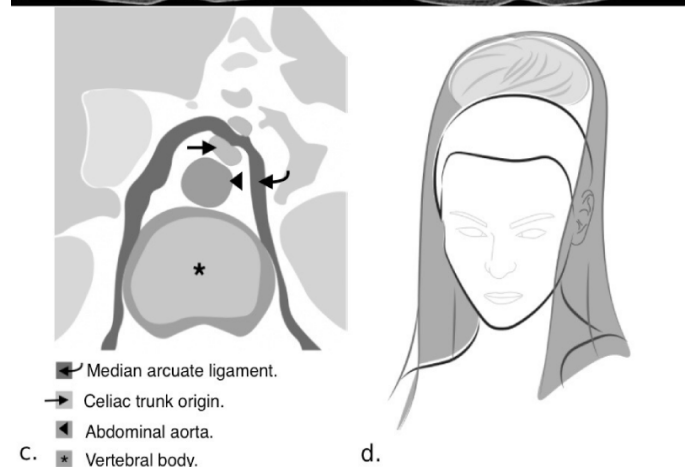
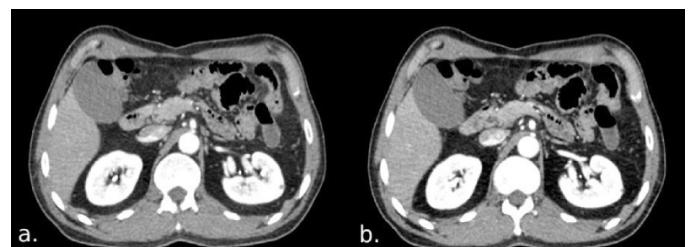


Figure 2: (a) Post-contrast axial images at the level of the celiac trunk in inspiration (a) and expiration (b). (c) Demonstrates the chignon and mantilla sign, the drawing demonstrates the chignon is equivalent to the celiac trunk (straight arrow) and the mantilla is the median arcuate ligament (curved arrow), and their anatomic relation to the aorta (arrowhead) and vertebral body (asterisk). (d) Shows a schematic drawing of the chignon and mantilla hairstyle.

potassium, calcium, phosphorus and chloride electrolyte levels, normal lipid profile, albumin 4.2 g/dL, total protein 7.28 g/dL, BMI: 26.3kg/m², TSH: 1.3 mU/mL, free T4 1.2 ng/dL, normal PT and PTT and a non-reactive HIV antibody assay.

The treating multidisciplinary group ordered Doppler of the celiac trunk, finding a peak systolic velocity of 238 cm/sec during forced expiration and an increased aortic/cealic trunk deflection angle of 55°, associated with verticalization and decreased angle between the celiac trunk and aorta (Figure 1). Subsequently, for better characterization and confirmation of these findings, abdominal angiotomography with 3D reconstruction was performed both during deep inspiration and forced expiration.

Findings during the expiratory phase in sagittal reformatting and 3D reconstruction showed focal narrowing (of at least 50% diameter) of the proximal third of the trunk associated to post-stenotic arterial dilation, with acute angulation and “hook-shaped” deformity of the celiac trunk. There was no collateral circulation nor calcified atherosclerotic plaques (Figure 2). Findings on the the axial images during forced expiration showed the compression and deformity of the celiac trunk forming the chignon and mantilla sign, where MAL simulates the mantilla (a silk cloth) placed anterior to the chignon (a knot-like hairstyle) that the origin of the compressed celiac trunk represents (Figure 3) [10].

Thus, the diagnosis of median arcuate ligament syndrome was confirmed, a multidisciplinary surgical meeting was performed, and laparoscopic surgical management was finally decided.

The surgical team performed median arcuate ligament liberation, adherence lysis and celiac ganglion resection via laparoscopic surgery. The patient had a good post-operative evolution with improvement on abdominal pain, with no acute complications so he was discharged shortly after. At 1 week postoperative check-up appointment, the patient referred pain recurrence while standing and improvement with decubitus.

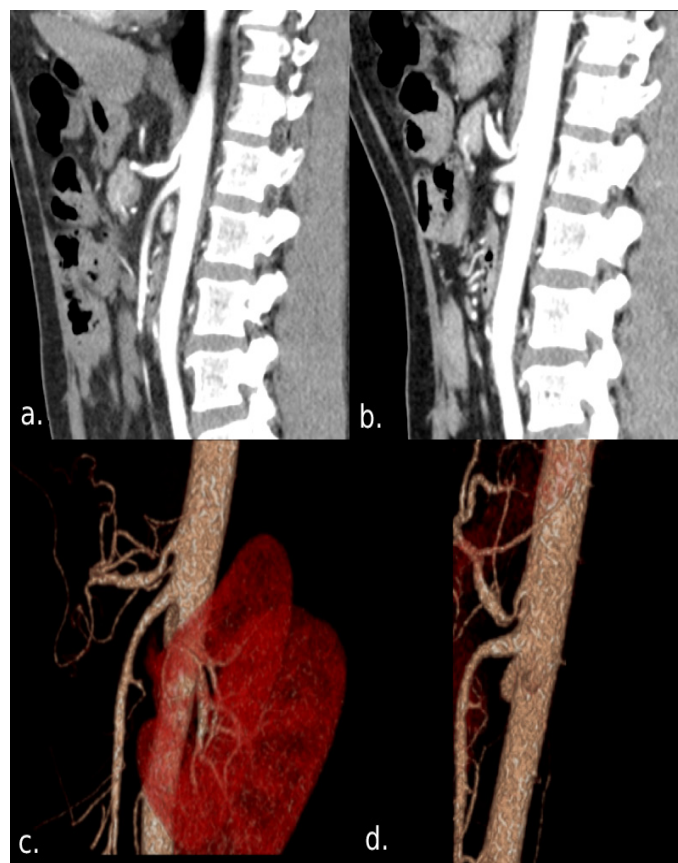


Figure 3: Contrasted sagittal reconstruction of the celiac trunk (CTA) and in 3D, in deep inspiration (a) and forced expiration (b), in (b) and (d) narrowing or imprinting of the celiac trunk secondary to the median arcuate ligament is observed, configuring the origin of the celiac trunk hooked appearance with post-stenotic dilatation. No signs of atherosclerosis or signs of arteriosclerotic disease were observed.

Table 1: Advantages and disadvantages of imaging methods “highlights” [11].

Imaging modality	Advantages	Disadvantages
Duplex ultrasound	<ul style="list-style-type: none"> - Recommended first line of investigation - Cheaper - Non-invasive - Non-ionizing - Hemodynamic assessment 	<ul style="list-style-type: none"> - May not be diagnostic alone
Digital subtraction angiography	<ul style="list-style-type: none"> - Classical standard for diagnosis - Adequate characterization of the findings 	<ul style="list-style-type: none"> - Invasive procedure. - Less availability.
Computed Tomography Angiography (CTA)	<ul style="list-style-type: none"> - High Imaging resolution. - Adequate characterization of the findings. - Non-invasive. - Allows for 3D reconstruction. - Evaluation of direct and indirect findings. - Detect or exclude other intra-abdominal pathologies. - Differentiate stenosis due to MAL vs atherosclerotic narrowing. - Indicated in moderate to high suspicion of chronic mesenteric ischemia. -Allows pre-surgical mapping. 	<ul style="list-style-type: none"> - Ionizing radiation. - Requires specific acquisition protocols.
Magnetic Resonance Angiography	<ul style="list-style-type: none"> - Useful in patients with contrast allergies. - Similar findings as CTA 	<ul style="list-style-type: none"> - Less availability than CTA.

Discussion

Median arcuate ligament syndrome is an infrequent disease that results from the celiac trunk compression secondary to an anomalous insertion of the Median Arcuate Ligament (MAL). Initially recognized by Dunbar et al circa 1965, it has become a complex diagnosis involving clinical presentation and imaging findings [2].

This disease predominates in women in a 4 to 1 ratio against men, it has an incidence peak from 30 to 50 years of age and its real prevalence is unknown. Main symptoms include abdominal pain that begins after food intake or exercise, although it can also appear spontaneously. Additionally, patients may refer unintentional weight loss, nausea and present an abdominal bruit on examination [7].

Breathing is closely related to the degree of celiac artery narrowing. During inspiration, the celiac trunk descends and the MAL ascends, conditioning less external pressure on the artery and greater pressure during exhalation [2]. Applying this knowledge is crucial during the acquisition of different imaging modalities including ultrasound (US), Computed Tomography Angiography (CTA) and angiography, so as to differentiate isolated compression of the artery from clinically relevant one. There's no definite criteria for diagnosis. Nowadays, the disease is considered a diagnosis of exclusion that requires a compatible clinical picture and evidence of celiac artery compression by imaging [4].

Some authors also deem demonstration of the degree of hemodynamic alteration necessary to diagnose this entity. Duplex ultrasound is a non-invasive imaging method, useful for this purpose. Different cut-off points have been found for peak systolic velocity (PSV), a measurement of the blood flow velocity that is directly proportional to the severity of arterial stenosis. A PSV value >200 cm/s has a 75% sensitivity and 89% specificity [4], whereas a PSV >350 m/s with a 50° arterial angle has a 83% sensitivity and 100% specificity for the diagnosis [2,11].

Classically, conventional angiography was the preferred imaging modality to observe celiac artery compression. Nowadays, it's been replaced by angiotomography, since it's more convenient, minimally invasive and more precise [1]. Characteristic findings are a focal stenotic area in the proximal aspect of the celiac trunk, in the shape of a hook, during exhalation. Additionally, CTA imaging allows for evaluation of indirect signs such as collateral circulation, post-stenotic arterial dilation and detect or exclude other intra-abdominal etiologies [4].

Available research shows that the degree of stenosis doesn't correlate with severity of symptoms, but it can guide therapeutic decisions [2]. Surgical management has as its main objective to correct the pathophysiological mechanisms thought to give origin to this disease: decompression of the celiac trunk by liberating the MAL either by an open, endoscopic or laparoscopic approach, with or without celiac ganglionectomy [5]. Some specialized centers use intraoperative laparoscopic ultrasound measurements to evaluate arterial blood flow hemodynamics, where a stenosis of 70% or greater suggests stent placement might be necessary [9].

Although research is lacking, evidence suggests most patients refer immediate postoperative symptom relief, with variable rates of late recurrence that might differ between different surgical approaches. The more robust study to date refers no procedure-related adverse events nor early peri-operative deaths [7].

Conclusion

MALS is a rare syndrome and a diagnosis of exclusion. There is no definitive consensus, diagnostic or treatment criteria, however the clinical and imaging findings are consistent in the literature, for a diagnostic approach, exclude other etiologies, plan a multidisciplinary treatment and follow-up.

Key results

-Rare vascular compression syndrome, there are no diagnostic or treatment criteria, multidisciplinary groups are important to determine behaviors

-Duplex ultrasound is the diagnostic method of choice followed by CT.

Funding

This work has had no institutional or external financial support.

We have no conflicts of interest.

Acknowledgements

We would like to thank all the internal medicine Daniela Fajardo y Naomi Escobar.

References

- Horton KM, Talamini MA, Fishman EK. Median arcuate ligament syndrome: Evaluation with CT Angiography. *RadioGraphics*. 2005; 25: 1177-1182.
- Goodall R, Langridge B, Onida S, Ellis M, Lane T, et al. Median arcuate ligament syndrome. *Journal of Vascular Surgery*. 2020; 71: 2170-2176.
- Narwani P, Khanna N, Rajendran I, Kaawan H, Al-Sam R. Median arcuate ligament syndrome diagnosis on computed tomography: What a radiologist needs to know. *Radiology Case Reports*. 2021; 16: 3614-3617.
- Fong JKK, Poh ACC, Tan AGS, Taneja R. Imaging Findings and Clinical Features of Abdominal Vascular Compression Syndromes. *AJR*. 2014; 203: 29-36.
- Harjola PT. A rare obstruction of the coeliac artery. Report of a case. *Ann Chir Gynaecol Fenn*. 1963; 52: 547-550.
- Dunbar JD, Molnar W, Beman FF, Marable SA. Compression of the celiac trunk and abdominal angina. *Am J Roentgenol Radium Ther Nucl Med*. 1965; 95: 731-744.
- Kim EN, Lamb K, Relles D, Moudgill N, DiMuzio PJ, et al. Median Arcuate Ligament Syndrome-Review of This Rare Disease. *JAMA Surg*. 2016; 151: 471-477.
- Loukas M, Pinyard J, Vaid S, Kinsella C, Tariq A, et al. Clinical anatomy of celiac artery compression syndrome: a review. *Clin Anat*. 2007; 20: 612-617.
- San Norberto EM, Romero A, Fidalgo-Domingos LA, García-Saiz I, Taylor J, et al. Laparoscopic treatment of median arcuate ligament syndrome: a systematic review. *Int Angiol*. 2019; 38: 474-483.
- Martinez Soliva D. Bow and mantilla sign in median arcuate ligament of the diaphragm syndrome. *Rev Argent Radiol*. 2015; 79: 55-57.
- Scholbach T. Celiac Artery Compression Syndrome in Children, Adolescents, and Young Adults. *J Ultrasound Med*. 2006; 25: 299-305.