



An unexpected accidental ingestion of dental crown with loop: A clinical image

Yuh Baba^{1*}; Yasumasa Kato²

¹Prof. of Department of General Clinical Medicine, Ohu University School of Dentistry, 31-1 Misumido, Tomita-machi, Koriyama City, Fukushima 963-8611, Japan

²Prof. of Department of Oral Function and Molecular Biology, Ohu University School of Dentistry, 31-1 Misumido, Tomita-machi, Koriyama City, Fukushima 963-8611, Japan

***Corresponding Author(s): yuh Baba**

Professor, Department of General Clinical Medicine,
Ohu University School of Dentistry, 31-1 Misumido,
Tomita-machi, Koriyama City, Fukushima 963-8611,
Japan

Tel: +81-24-932-9331; Email: y-baba@den.ohu-u.ac.jp

Received: June 26, 2018

Accepted: July 17, 2018

Published Online: July 20, 2018

Journal: Journal of Case Reports and Medical Images

Publisher: MedDocs Publishers LLC

Online edition: <http://meddocsonline.org/>

Copyright: © Baba Y (2018). *This Article is distributed under the terms of Creative Commons Attribution 4.0 International License*

Keywords: Accidental ingestion; Ental crown with loop; Abdominal X-ray imaging

Clinical Image Description

A 23-year-old female with no significant previous medical history presented at the emergency service of our dental hospital following the accidental ingestion of a crown during routine dental treatment. Her general condition was very good, without dyspnea, nausea, vomiting or abdominal pain. Pharyngo laryngo fiberoptic analysis revealed normal, suggesting passage of the foreign body into the esophagus. Plain abdominal X-ray imaging suggested that a sharp crown was in the stomach (Figure 1). Although we performed an urgent esophago-gastroscopy, we failed to retrieve the foreign body because the foreign body had already migrated beyond duodenojejunal flexure. Therefore, we performed the strict observation for the patient till the

foreign body is excreted as stool. Fortunately, we could confirm it two days after the accidental ingestion (Figure 2).

Although ingested foreign bodies usually pass through the gastrointestinal tract uneventfully, it can sometimes cause serious complications [1]. Therefore, as prevention method of accidental ingestion, our hospital is supposed to tether a crown with dental floss ligature using the loop as the attachment, during dental treatment (Figure 3). In this clinical case, during fitting the crown in oral cavity, dental floss was removed before finishing the procedure due to the difficulty the manipulation, and thereafter an accidental ingestion of crown with loop unexpectedly occurred. Thus, we think that dentist should tether dental floss into the loop during dental procedure.



Cite this article: Baba Y, Kato Y. An unexpected accidental ingestion of dental crown with loop: A clinical image. J Case Rep Clin Images. 2018; 1: 1004.

Figures

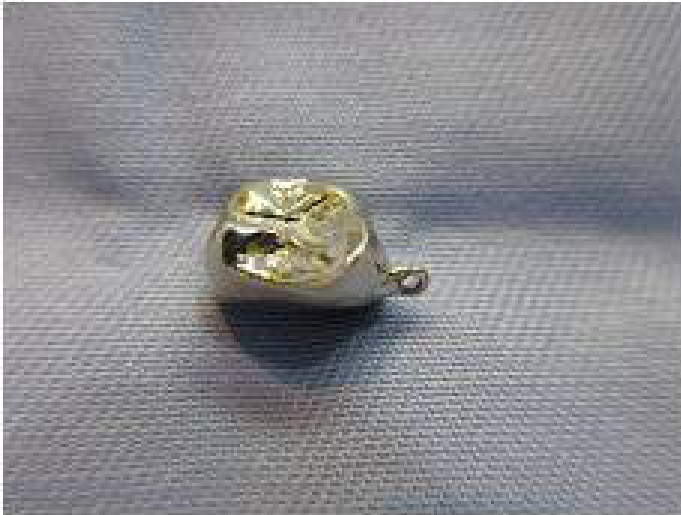

Figure 1: Abdominal X-ray imaging

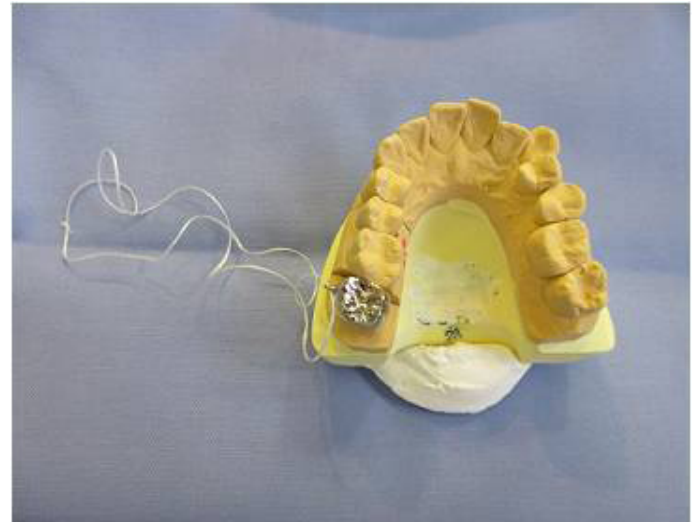


Figure 3: Prevention method of accidental ingestion in our dental hospital

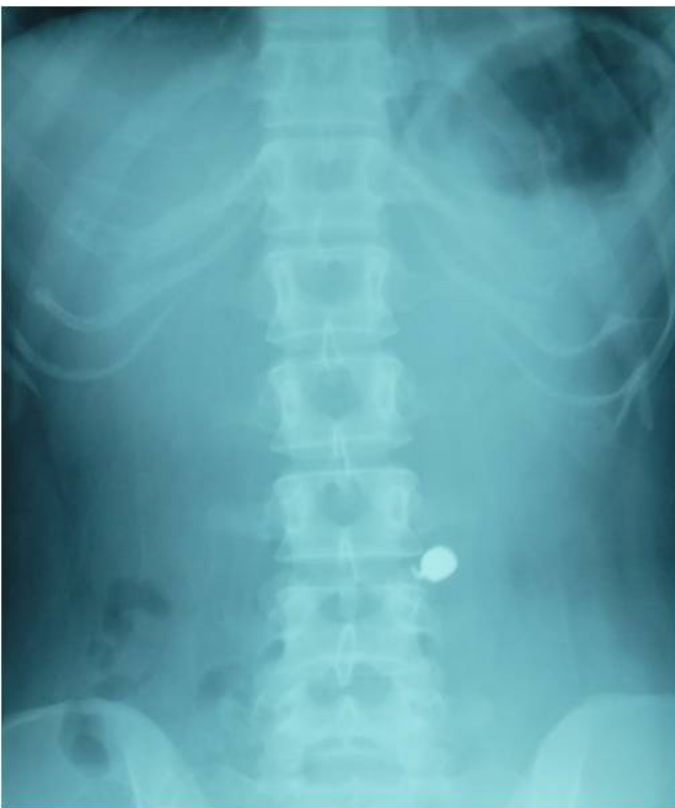

Figure 2: A crown with loop was observed.

References

1. Ambe P, Weber SA, Schauer M, Knoefel WT. Swallowed foreign bodies in adults. *Dtsch Arztebl Int.* 2012; 109: 869-875.