



A “Looped In” Malpositioned Cephalic Venous Catheter

Rohit Jindal^{1*}; Pranav Mohan Singhal¹; Pinakin Patel²; Suresh Singh³

¹Senior resident, Department of Surgical Oncology, Sawai Man Singh Medical College and Hospital, Jaipur, Rajasthan, India.

²Associate professor, Department of Surgical Oncology, Sawai Man Singh Medical College and Hospital, Jaipur, Rajasthan, India.

³Professor & Head, Department of Surgical Oncology, Sawai Man Singh Medical College and Hospital, Jaipur, Rajasthan, India.

***Corresponding Author(s): Rohit Jindal**

Senior resident, Department of Surgical Oncology,
Sawai Man Singh Medical College and Hospital, Jaipur,
Rajasthan, India.

Tel: +91-7973136571; Email: doc_rj24@yahoo.com

Received: May 09, 2022

Accepted: Jun 04, 2022

Published Online: Jun 06, 2022

Journal: Journal of Case Reports and Medical Images

Publisher: MedDocs Publishers LLC

Online edition: <http://meddocsonline.org/>

Copyright: © Jindal R (2022). *This Article is distributed under the terms of Creative Commons Attribution 4.0 International License*

Clinical image description

Chemoports are implantable devices that provide central venous access for chemotherapy, parenteral nourishment, and blood transfusions, among other procedures. They have significantly reduced the morbidity associated with chemotherapy administered peripherally. Cephalic venous cut down technique is a well-known approach for central venous catheter implantation among the several proven procedures. Infection, catheter malpositioning, catheter migration, venous perforation, hemothorax, pneumothorax, venous thrombosis, and stenosis are some of the risks of central venous catheter implantation. A 52 yr old lady, diagnosed with carcinoma of the right breast, underwent right modified radical mastectomy and left cephalic venous chemoport placement as the patient has been planned for adjuvant chemotherapy. After the surgery, the patient was

evaluated with a chest X-ray in the AP view to ensure that the catheter was in the correct location. However, to our surprise, the chest X-ray revealed that the catheter had formed a loop near the point of insertion, producing the erroneous impression of venous rupture and catheter extravasation into the surrounding tissue (Figure 1). To confirm the same, a lateral X-ray was done, which confirmed that the catheter was not “looped in” at the same point, but rather travelled a certain distance from the point of insertion, before getting lost (Figure 2). The chemoport’s venous free input and outflow were confirmed, and it was assumed that the catheter had reached the axillary vein, which is known to happen. The patient received chemotherapy through the chemoport following surgery, and the procedure went uneventful. The distal superior vena cava is the



Cite this article: Jindal R, Singhal PM, Patel P, Singh S. A “Looped In” Malpositioned Cephalic Venous Catheter. *J Case Rep Clin Images*. 2022; 5(1): 1111.

optimal location for the catheter tip. Although venous catheter malpositioning is common, it can lead to serious consequences, therefore making it imperative to undergo a routine postoperative chest X-ray once the chemoport is inserted.

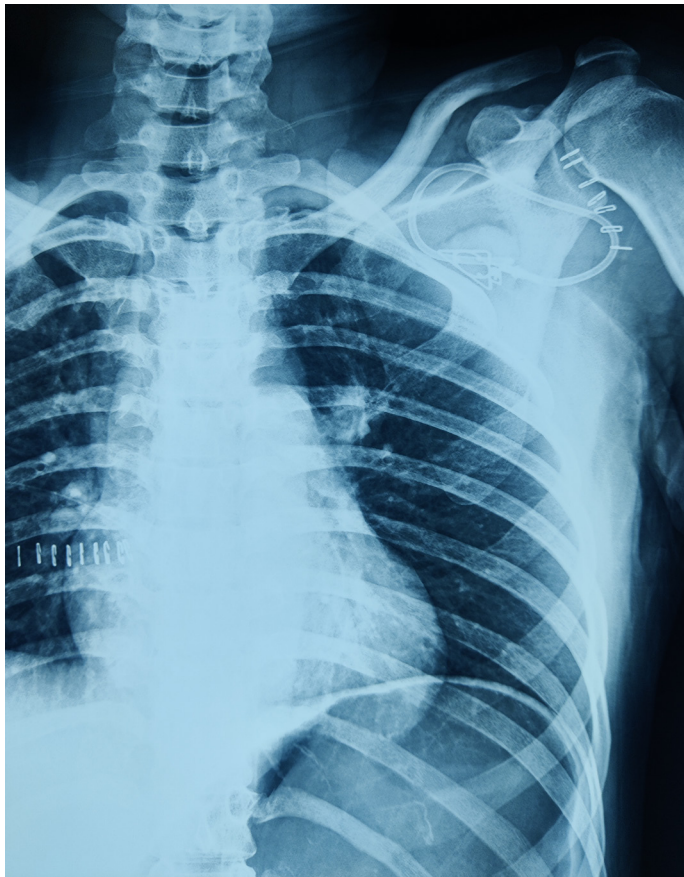


Figure 1: Post-operative AP view of Chest X-ray showing a "Looped In" cephalic venous catheter.

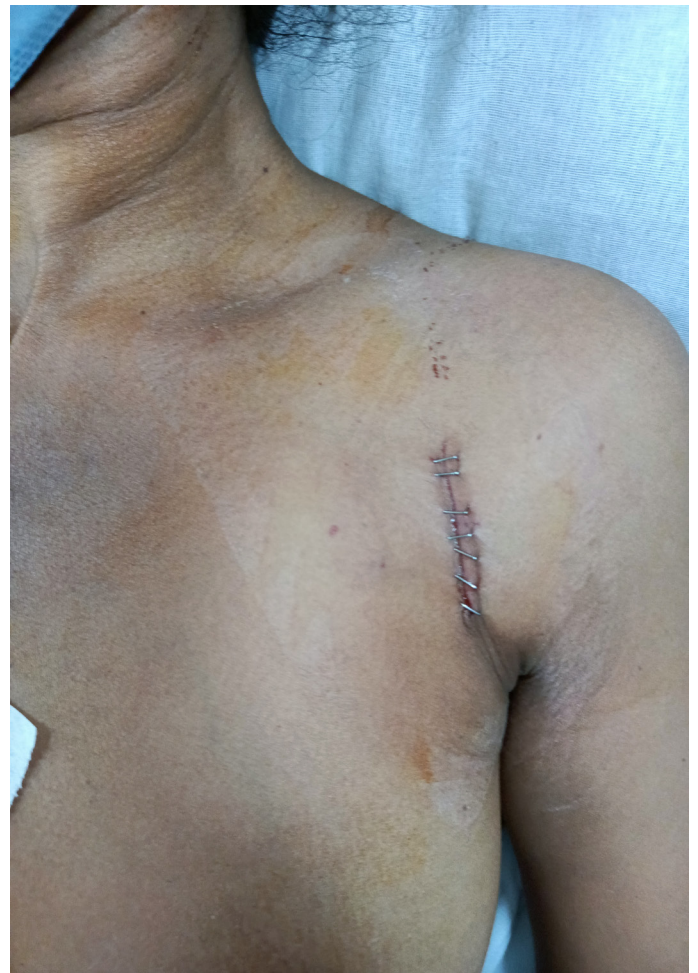

Figure 2: Post-operative picture showing the stapled suture line of the incision used for cephalic venous chemoport insertion.

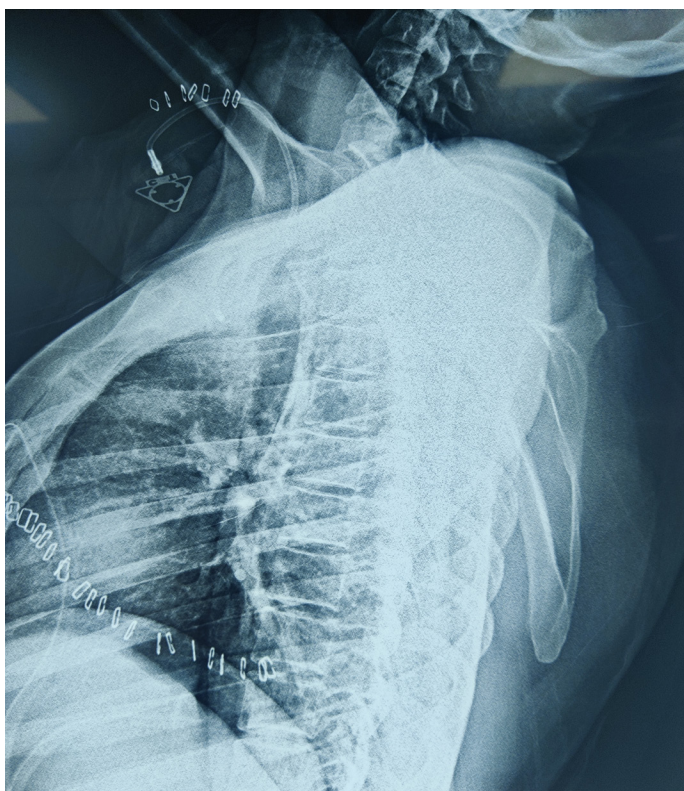


Figure 2: Post-operative lateral view of Chest X-ray confirming that the cephalic venous catheter has not extravasated into the surrounding tissue.