



Complete Avulsion of a Globe: Impact of “Toaka Gasy” Consumption During Lockdown?

Miray Louis de Gonzague^{1*}; Randriamanantena Tahiry²; Andrianomenjanahary Jodelle Willis³; Ramanarivo Norotiana Mihaja⁴; Raobela Lea⁵

¹Department of Ophthalmology, University Hospital Tambohobe Fianarantsoa, Madagascar.

²Department of Oral & Maxillofacial Surgery, University Hospital Andrainjato Fianarantsoa, Madagascar.

³Department of Psychiatry, University Hospital Tambohobe Fianarantsoa, Madagascar.

⁴Department of Public Health and Occupational Medicine Analakely, Antananarivo, Madagascar.

⁵Department of Ophthalmology, University Hospital Joseph Ravoahangy Andrianaivalona Antananarivo, Madagascar.

*Corresponding Author(s): **Mirya Louis de Gonzague**

Department of Ophthalmology, University Hospital Tambohobe Fianarantsoa, Madagascar.

Tel: +26 134 603 5203; Email: miraybabozy@gmail.com

Abstract

The Lock Downs due to COVID-19 pandemic impact negatively the economy, threaten lives, put livelihoods at risk and exacerbate poverty. Alcohol is used by people to manage symptoms of anxiety, depression and stress as a result of unemployment. Alcohol consumptions leads people to have the risk of immediate harms. We report a case of 38 year-old man who sustained left oculo-palpebral injury. Being fed up of job loss, he begun to consume the “Toaka gasy” or Malagasy alcohol since the beginning of lockdown in Madagascar. Ophthalmological finding showed that his left eye ball was missing. Two days after his hospitalization, the enucleated globe was found at his home under the stair. The eye ball deprived of its conjunctiva and muscles was hypotonic but intact. The cornea was cloudy. The mechanism of the trauma remains unknown.

Received: Aug 15, 2020

Accepted: Sep 21, 2020

Published Online: Sep 23, 2020

Journal: Journal of Addiction and Recovery

Publisher: MedDocs Publishers LLC

Online edition: <http://meddocsonline.org/>

Copyright: © Gonzague ML (2020). *This Article is distributed under the terms of Creative Commons Attribution 4.0 International License*

Keywords: Globe avulsion; Lockdown; Toaka gasy; Trauma; Unemployment.

Introduction

The coronavirus pandemic has resulted in an economic contraction of a magnitude and speed that are unprecedented in peacetime [1]. To contain the COVID-19, measures are being taken globally. In Africa, many countries including Madagascar have imposed partial or full lockdowns on the movements and activities of their people. The lockdowns, however, impact negatively the economy, threaten lives, put livelihoods at risk and exacerbate poverty [2]. Madagascar is exposed to the con-

sequences of Covid-19 in several ways. The tourism sector is among the hard hit by this overwhelming economic downturn [3]. Alcohol is sometimes used by people to manage symptoms of anxiety, depression and stress as a result of work shortage. In the UK more than one in five (21%) adults who drink alcohol are drinking more often since lockdown began. However, alcohol's effects on mental health are concerning. Alcohol consumptions leads people to have the risk of immediate harms such as acci-



Cite this article: Gonzague ML, Tahiry R, Willis AJ, Mihaja RN, Lea R. Complete Avulsion of a Globe: Impact of “Toaka Gasy” Consumption During Lockdown?. *J Addict Recovery*. 2020; 3(1): 1021.

dents, fires, quarrel arguments and conflict, but the risk of their alcohol consumption rising as well [4].

History of the "TOAKA GASY"

A "Toaka gasy" means Malagasy artisanal alcohol [5]. The Toaka gasy had long been distilled clandestinely in the bush from various components but especially from sugar cane [6].

The peasants do not control the percentage of alcohol contained in the drink. Thus, a liter of this beverage can contain nearly 75% pure alcohol (75°), which can be very dangerous for uninformed consumer [7]. Its consumption increases the risk of mortality, mental illnesses and traumatism by accidents or suicides [5]. This cheapest alcoholic drinks is still present in the Malagasy culture, traditional rites and customs. Recently, the legalization of Toaka gasy raises debate. This constitutes a subjects of many criticisms [7].

Alcohol was reported to be involved in 5% of ocular injuries in southern Finland [8]. Orbital wall fracture showed a significant association with alcohol consumption [9]. Avulsion of the globe is a rare condition that results from an extreme form of trauma and leads to a total vision loss [10]. Here we report a case of complete avulsion of a left globe following Toaka gasy intake-associated trauma during lockdown.

Observation

A 38 year-old man former tourism sector dealer, father of 4 children sustained left oculo-palpebral injury. She had no history of familial conflict nor drug smoking. Being fed up of job loss, he reportedly has begun to drink the "Toaka gasy" since the beginning of lockdown in Madagascar, in March 2020. According to his family, he took at least 1 liter of Toaka Gasy a day and became to speak to himself. The patient could not remember the mechanism of the trauma that happened at night time. At admission, the patient is conscious with glasgow score of 15/15. On ophthalmologic examination, the right eye was normal with 20/20 vision. Visual acuity of the left eye was no light perception. The upper eyelid of left eye was slightly edematous and there was a small wound near the internal canthus (Figure 1).

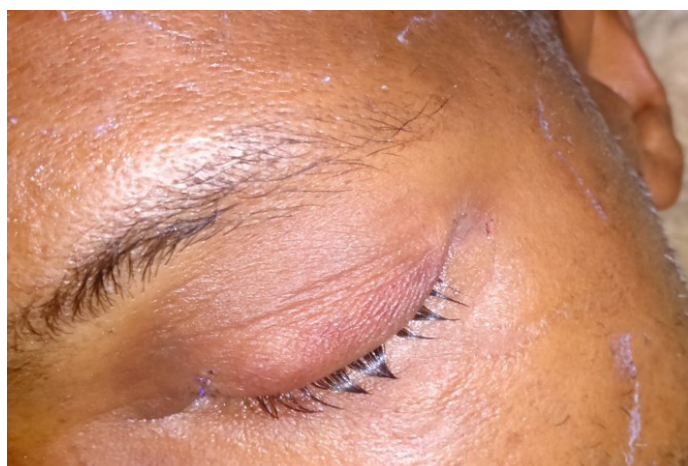

Figure 1: Slightly edematous left upper eyelid with small wound near the internal canthus.

We didn't felt orbital wall cracking on palpation. Due to the hemorrhage, slit lamp examination appeared to be difficult. We proceeded an exploration at operating room under local anesthesia. We found that the left ocular globe was missing. Amazingly, the bulbar conjunctiva remained on its place and the muscles conserved their movements (Figure 2).

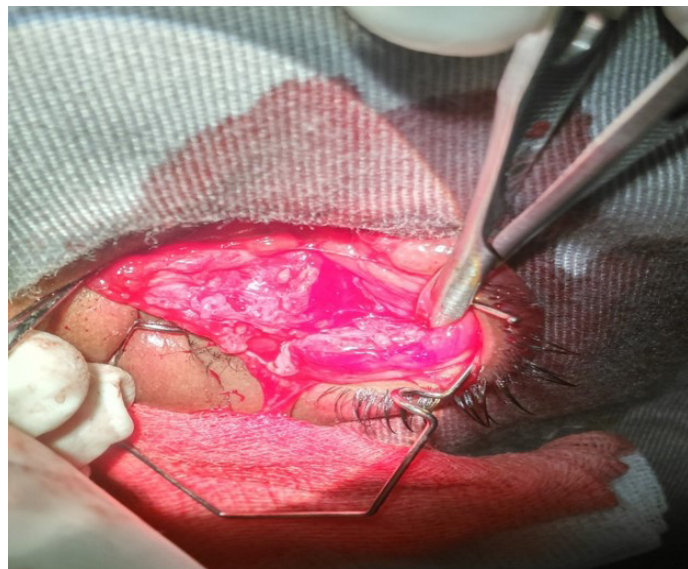


Figure 2: Exploration that found no eye ball.

Then we closed the conjunctiva with absorbable suture vicryl 6/0 (Figure 3).

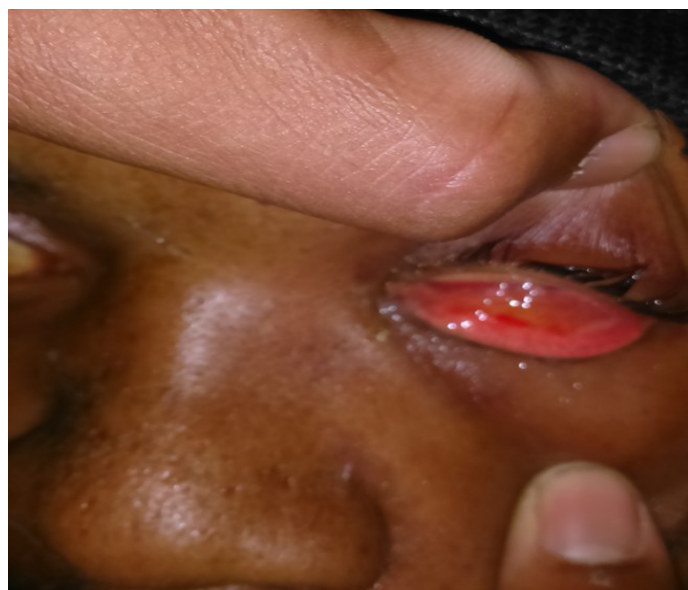

Figure 3: The conjunctiva is sutured.

To prove the absence of eyeball, we prescribed a CT scan of the soft tissue of the orbit but it was not done because of financial issue. Two days after the admission to the hospital, the enucleated globe was found at his home under the stair and was brought to us at the hospital. The eye ball deprived of its conjunctiva and muscles was hypotonic but intact. The cornea was cloudy (Figure 4). The optic nerve is sectioned completely (Figure 5).

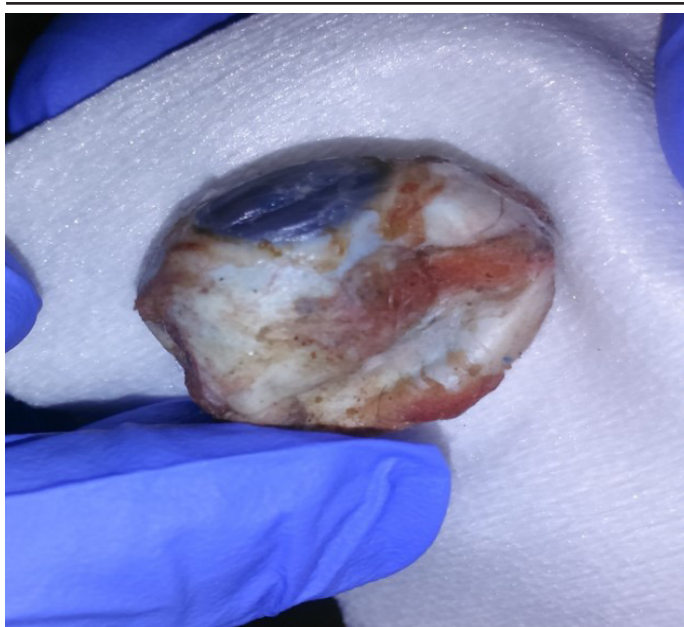

Figure 4: Hypotonic eye ball deprived from its conjunctiva and muscles.

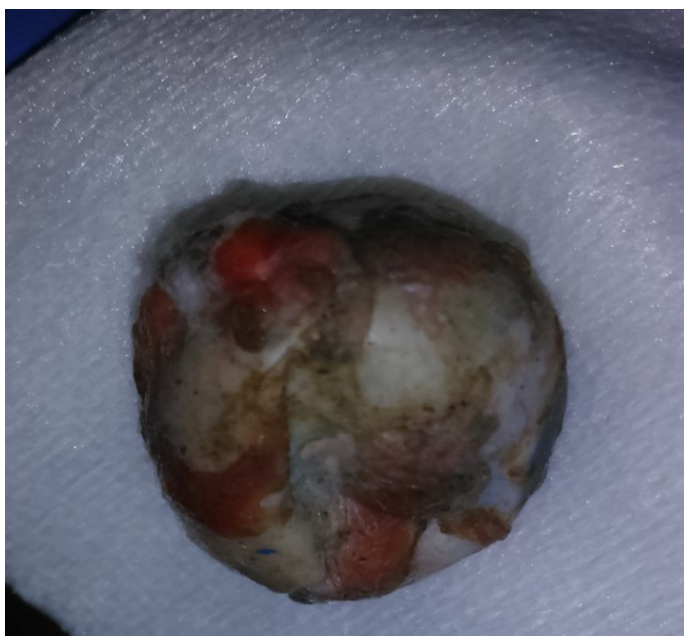

Figure 5: Optic nerve completely sectioned.

Discussion

Avulsion of the globe is a very rare situation that happens as result of total disruption of the extraocular muscles and optic nerve, and displacement of these structures out of the orbital cavity. It occurs only in maxillofacial fractures. Optic nerve section usually occur following a severe facial trauma, or martial art maneuvers [11]. What is astonishing that our patient didn't have any palpebral laceration nor orbital bones cracking after the traumatism. Gagov et al stated that alcohol plays an important part in maxillofacial trauma, and that the association of interpersonal violence and alcohol is extremely high in Bulgaria. Falls made up 28% of our trauma and alcohol was involved in 24% of them [12]. According to Han et al, physical assault was more common in alcohol-associated injury. Besides orbital wall fracture and hyphemia showed a significant association with alcohol consumption but not the globe avulsion. Night time injury were significantly related to the increased risk of alcohol-

associated ocular trauma. That relates to the case of our patient whose the trauma occurred at night time also [13].

Many researches were published about the characteristics of ocular trauma and avulsion.

Katarina et al. reported the case of the older male person, who attempted suicide by gunshot had his right eye enucleated with complete acute section of the optic nerve [14]. The same, Among four patients with evulsion of the optic nerve evaluated by Sanborn et al. caused by blunt trauma. The avulsion was complete only in two of the patients and incomplete in the other two [15]. UNALI et al. reported also a case of bilateral complete avulsion of ocular globes in a severe trauma classified as Le Fort III maxillofacial fracture. Both globes were luxate out of the orbit and suspended only on the skin of the upper lid below the brows but not fallen on the floor [16]. Her husband hit a 25 years old female over the left hemi-face by a sickle. She had DE gloving and avulsion of the left upper hemi face including the nose, forehead skin and eyebrow on the left side, upper and lower eyelids and part of the cheek. But the globe was intact [17]. De Gonzaga et al observed a 94-year-old woman who sustained multiple and deep facial injuries associated with full thickness tissue of the face involving the front, eyelid with ocular muscles and scleral lacerations, nose, upper lips and a part of her left ear. The cornea was fine and the eye ball remained on its place [18].

We can draw some hypothesis from the aforementioned reports that even of high magnitude trauma such as blunt trauma, gunshot, stabbing and finally dog bites could not manage to bring the eye ball to fall to the floor. So we need further explanation of the case of our patient who had no history of severe traumatism but he had his left globe fallen on the floor. On top of that, under the stairs. It is known that alcohol intake has been proved to potentiate aggressive behavior as a psychomotor stimulant [19]. To support this finding, Lang et al e reported that auto enucleations are also reported in psychiatric patients [20] and this context is difficult to be excluded in the case of our patient. In addition, a study conducted by Eliason et al, in Sweden, found out that a more than 3% increase in unemployment was associated with an increase in suicide rates [20].

Our patient drank much alcohol called Toaka Gasy a day. This is an uncontrolled strong beverage which can contain 75° of alcohol. Moreover, the components of this drink are not identified. If our patient couldn't remember the mecanism of the trauma and didn't feel the pain without drug smoking context, what is the reason? The Toaka Gasy is too strong for his body? Do the active substances in Toaka gasy have stupeficient effect?.

By contrast, Hammer T highlighted that unemployment does not appear to influence the consumption of alcohol. Their study concluded that that there was no increase in use of alcohol in response to stress as a result of unemployment [21].

Much more needs to be done to reduce alcohol-related injuries at national and regional levels. Malagasy government should investigate the components and the degree of the Toaka gasy before promulgating the law that authorizes the trade of this sugar cane-based local drink into national market. Face to unemployment, people should focus in mind that alcohol intake is worsening the issues.

Conclusion

Madagascar is exposed to the consequences of Covid-19 in several ways. The tourism sector is among the hard hit by this overwhelming economic downturn. Alcohol is sometimes used by people to manage symptoms of anxiety, depression and stress as a result of unemployment.

Our patient sustained an avulsion of his left ocular globe due to Toaka gasy-associated trauma as a result of unemployment. Malagasy government should investigate the components and the degree of the Toaka gasy before promulgating the law that authorizes the trade of this sugar cane-based local drink into national market. Face to unemployment, people should focus in mind that alcohol intake is worsening the issues. A study comparing the aspect of ocular trauma linked to Toaka gasy and ordinary alcohol should be conducted.

References

- Ewing J and Stevis-Gridneff M, 'European Slump Is Worst Since World War II, Reports Show', NY Times. 2020.
- United Nations, Economic commission for Africa. Covid-19 Lock-down Exit Strategies For Africa.
- UNDP. Note On The Impact Of Covid-19 On The Economy Of Madagascar Scenarios and recommendations.
- CARE First.COVID-19: Managing Alcohol intake during Lock-down.
- Richard JP, Palle C, Guignard R et coll. La consommation d'alcool en France en 2014. Evolution, resultants d'étude et des recherches en education et en prevention pour la santé, n°32- Avril. 2015; 1.
- Malagasy tours. Que boivent les Malgaches?.
- Mandimbisoa R. Madagascar Tribune. La legalisation du Toaka gasy suscite des débats. Jeudi 2020 .
- Sahraravand A, Haavisto AK, Holopainen JM , Leivo T. Ocular trauma in the Finnish elderly Helsinki Ocular Trauma Study. Acta Ophthalmol. 2018; 96: 616–622.
- Han SB, Yang HK, Woo SJ, Hyon JY, Hwang JM. Association of Alcohol Consumption with the Risk of Ocular Trauma Korean Med Sci. 2011; 26: 675-678.
- Bajaj MS, Kedar S, Sethi A, Gupta V. Traumatic globe luxation with optic nerve transection. Orbit. 2000; 19: 165-170.
- Roth DB, Warman R. Optic nerve avulsion from a golfing injury. Am J Ophthalmol. 1999; 128: 657-658.
- Gagov L, Rubiev M, Deliverska E. The Role Of Alcohol Involvement In Maxillofacial Trauma JofIMAB. 2012; 18.
- Sang Beom Han, Hee Kyung Yang, Se Joon Woo, Joon Young Hyon, and Jeong-Min Hwang Association of Alcohol Consumption with the Risk of Ocular Trauma Korean Med Sci. 2011; 26: 675-678.
- Janicijevic K, Petrovic MJ, Kocic S, Radovanovic S. Traumatic avulsion of the optic nerve PONS Med J. 2015; 12: 75-78.
- Sanborn GE, Gonder JR, Goldberg RE, Benson WE, Kessler S. Evulsion of the optic nerve: A clinic pathological study. Can J Ophthalmol. 1984; 19: 10-6.
- Unal S, Argin A, E. Arslan, F. Demirkan, A. Aksoy. Bilateral complete avulsion of ocular globes in a Le Fort III maxillofacial fracture: A case report and review of the literature. European Journal of Ophthalmology. 2005; 1: 123-125.
- Panse N, Sahasrabudhe P, Joshi N. Face Avulsion and Degloving. World J Plast Surg. 2014; 3: 64-67.
- De Gonzague ML, Carnot NS, Rado R, Cyris J, Rindra R, et al. Disfigured Woman with Ocular Involvement by Dog Bites. Arch Surge Cline Case Rep. 2019; 2: 115.
- Lang GK, Bialasiewicz AA, Rohr WD. Bilateral traumatic eye avulsion. Kiln Monatsbl Augenheilkd 1991; 198: 112-116.
- Eliason M, Storrie D. Does Job Loss Shorten Life? Journal of Human Resources. 2009, 44: 277-302.
- Hammer T. Unemployment and use of drug and alcohol among young people: A longitudinal study in the general population British Journal of Addiction 1992; 87: 1571-1581.