



Hemopatch® as a New Dural Sealant in Posterior Fossa Neurosurgery; A Clinical Application Observation

Stephan Nowak^{1*}; Márton Eördögh²; Henry WS Schroeder²; Steffen Fleck²

¹Universitätsmedizin Greifswald, Clinic and Polyclinic for Neurosurgery, Sauerbruchstrasse, 17475 Greifswald.

²Department of Neurosurgery, Clinic and Polyclinic for Neurosurgery, Sauerbruchstrasse, 17475 Greifswald.

***Corresponding Author(s): Stephan Nowak**

Universitätsmedizin Greifswald, Clinic and Polyclinic for Neurosurgery, Sauerbruchstrasse, 17475 Greifswald.

Tel: +49-3834-86-6163;

Email: stephan.nowak@uni-greifswald.de

Abstract

Hemopatch® as a new dural sealant in posterior fossa neurosurgery; a clinical application observation.

Objectives: We analyzed our results using Hemopatch® as a new dural sealant after neurosurgical procedures via the retrosigmoid approach.

Patients and methods: In our prospective single center study, we analyzed all patients (288) who received a retrosigmoid craniotomy between October 2016 and December 2019. We included 161 (55.9%) female and 127 (44.1%) male patients. The mean age at time of surgery was 56 years (4-83 years). We included emergency and elective surgical procedures. We did not exclude any type of underlying pathology. We took note of the general patient data, the size of Hemopatch® and TachoSil® used, the type of dural closure, and the postoperative stay. Additionally, we recorded the type of dural closure (watertight/ watertight with additional muscle patch/ not watertight with small or large defect (>1cm) remaining) and of pre- and postoperative hydrocephalus.

Results: Indication for surgery was hemifacial spasm in 134 (46.6%) patients, trigeminal neuralgia in 71 (24.7%) patients, vestibular schwannoma in 53 (18.4%) patients, meningioma in 15 (5.2%) patients, epidermoid in 8 (2.8%), and miscellaneous conditions in 7 (2.4%) patients (brainstem glioma, sarcoma, plasmocytoma, metastases, and vascular compression of the lower nerve group). TachoSil® was used in 224 (77.8%) cases and Hemopatch® was used in 39 (13.5%) cases. TachoSil® was used in 40.6% for watertight sutures, in 50% for dural sutures with small defects and in 9.4% for complex dura plastics.

Hemopatch® was used in 20.5% for watertight sutures, in 38.5% for dural sutures with small defects and in 41% for complex dura plastics. A fistula occurred with Tachosil in 6.2% and with Hemopatch® in 1.4% of cases.

Received: Dec 20, 2020

Accepted: Feb 08, 2021

Published Online: Feb 11, 2021

Journal: International Journal of Innovative Surgery

Publisher: MedDocs Publishers LLC

Online edition: <http://meddocsonline.org/>

Copyright: © Nowak S (2021). *This Article is distributed under the terms of Creative Commons Attribution 4.0 International License*

Keywords: Hemopatch®; Dural sealant; Dural closure; Csf fistula; Posterior fossa surgery.

Abbreviations: CSF: Cerebrospinal Fluid; NHS-PEG: Succinimidyl Carboxyl Methyl Ester; PDS: Polydioxanon; PEG: Polyethylen glycol; SAH: Subarachnoid Hemorrhage.



Conclusion: We could demonstrate the safety and efficiency of Hemopatch® used as dural sealant after durotomy in microneurosurgical posterior fossa surgery. To confirm our promising results a larger prospective randomized controlled trial will be needed.

Introduction

After performing intradural cranial or spinal procedures a watertight dural closure should be achieved to reduce the risk of Cerebrospinal Fluid (CSF) leakage. Several studies could demonstrate that a CSF leakage increases the morbidity, prolongs the hospital stay, and may lead to revision surgery [1]. That means that not only the perioperative risks increase for the individual patient, but also the costs [2]. To achieve a watertight dural closure many techniques and sealant agents have been developed [3]. Nowadays, one of the most often used sealing agents is a fibrinogen–thrombin-coated collagen pad (Tachosil®, Takeda Pharma Vertrieb GmbH & Co. KG Germany). Its successful use as a hemostat but also as a dural sealant has been reported [4]. In our previous study “Hemopatch® as a new dural sealant: A clinical observation”, we studied Hemopatch® (Baxter Deutschland GmbH; Germany) in a clinical application observation in a broad setting for dural closure [5]. Figure 1 shows a biochemical model. Especially due to its dual mechanism of action which uses a porous collagen matrix to promote greater hemostatic effects and the protein-binding layer meaning a greater adhesiveness to the side of action [6]. This makes the Hemopatch® also an excellent alternative to classic fibrinogen-thrombin-coated collagen pads as a dural sealant.

Due to the small cohort of our previous study and the general clinical setting the statistical data could only be used as a first evaluation of usability. To validate our results, we designed a new study to evaluate dural repair after the widely applied standardized retrosigmoid posterior fossa approach. The rate of CSF leaks after posterior fossa surgery is especially high with up to 17% [7]. Therefore, a meticulous watertight dural closure is of utmost importance, putting special demand on sealing agents.

Material and methods

Participants

In our prospective single center study, we analyzed 288 patients who received a retrosigmoid approach between October 2016 and December 2019. The inclusion criteria contain all cases who underwent craniotomy for a retrosigmoid approach. Five cases were already included in our previous study [5]. For a general overview of the effectiveness of our dural closure and/or repair in the broad clinical setting, we included emergency and elective surgical cranial intradural procedures. We did not exclude any type of underlying pathology the patient was operated on. Always, the surgeon decided on his own clinical experience, in every single case independently, to use or not to use Hemopatch®, TachoSil® or any other technique to achieve a watertight dural closure. In our department, a collagen sealing agent will be used when a watertight suture cannot be achieved by running suture alone. Small to medium sized defects will usually be closed with the use of a muscle patch. Large defects will be closed by either periost or pericard (XenoSure LeMaitre Vascular GmbH; Germany) grafting together with a collagen sealant overlay. Figure 2 shows an intraoperative application of Hemopatch® as dural sealant after retrosigmoid craniotomy.

The dural suture was accomplished using Prolene 4-0 (Johnson & Johnson Medical GmbH; Germany).

The study was approved by the ethical commission board of the university medicine Greifswald.

Data collection

Before data collection a power analysis was performed. A prospective randomized study with two arms (Hemopatch® and Tachosil®) needs to generate 700 cases per cohort group for statistical relevant data. Due to non-feasibility, data collection was therefore performed by retrospective analysis of prospective generated clinical data.

We obtained the general patient data, the size of Hemopatch® and TachoSil® used, the type of dural closure and the postoperative stay. Special note we took on the type of dural closure (watertight/ watertight with additional muscle patch/ not watertight with small or large defect remaining). Furthermore, we recorded mastoid opening after retrosigmoid approach and type of sealing (bone wax/ muscle and or fibrin glue).

To define the efficacy of Hemopatch® as dural sealant we took special note of how the primary dural closure was accomplished, before the application of Hemopatch®, and whether a dural defect remained as potential source of dural fistula. Special risk factors favoring a dural fistula (intra-operative mastoid opening or complex dural repair) were noted. Any sign of dural fistula (rhinoliquorrhoe, subgaleal CSF accumulation or open fistula) in the postoperative course was clinically evaluated and documented.

For safety analyses, any sign of surgical site infection was clinically evaluated. Blood analysis for infect parameters (CRP and leucocyte count) was performed at the first postoperative day and when clinical signs of infection (wound swelling, redness, high temperature, profound night sweating and cardiopulmonary signs) were reported. We analyzed the surgical report for detailed information.

The data analysis was done by using Microsoft Excel and statistical percental comparison.

Results

We included 161 (55.9%) female and 127 (44.1%) male patients. The mean age at time of surgery was 56 years (4-83 years). All procedures performed were with dural opening. Surgery was performed due to hemifacial spasm in 134 (46.6%) patients, due to trigeminal neuralgia in 71 (24.7%) patients, due to vestibular schwannoma resection in 53 (18.4%) patients, due to meningioma resection in 15 (5.2%) patients, due to epidermoid resection in 8 (2.8%) and in 7 (2.4%) patients a rare etiology (brainstem glioma, sarcoma, plasmocytoma, metastases and vascular compression of the lower nerve group) was the reason of surgery. An acute pre-operative hydrocephalus was not present. Also, in the postoperative course a hydrocephalus, leading to shunt surgery, was not observed.

The size of Hemopatch® is divided in small (2.7x2.7 cm), medium (4.5x4.5 cm) and large (4.5x9.0 cm). The small size was used in 26 (29%) patients, the medium size in 12 (4.2%) patients, and the large size in the remaining 1 (0.3%) patient. The small size of TachoSil® was used in 176 (61.1%) patients, the medium size was used in 46 (16%) patients and the large size was not used at all. In comparison, TachoSil® was used in 224 (77.8%) cases and Hemopatch® was used in 39 (13.5%) cases.

A nearly watertight/ watertight suture could be achieved in 122 (42.4%) of cases. From those, 91 were additionally sealed by TachoSil and 8 by Hemopatch®. A watertight suture without the use of a sealing agent was achieved in 23 (8%) cases.

A small defect after dural suture remained in 127 (44.1%) cases of which, 112 were additionally sealed by TachoSil® and 15 by Hemopatch®.

A complex dural reconstruction with muscle and or duragen/ galea was performed in 39 (13.5%) cases. Of those, 21 were sealed with TachoSil® and 16 with Hemopatch®. In 2 cases, no sealing patch was used.

To put the results in comparison for each sealing patch:

TachoSil® was used in 40.6% for watertight sutures, in 50% for dural sutures with small defects and in 9.4% for complex dura plastics.

Hemopatch® was used in 20.5% for watertight sutures®, in 38.5% for dural sutures with small defects and in 41% for complex dura plastics.

Tablet 1 shows a circular chart for better visualization.

A cerebrospinal fluid fistula occurred in 23 (8%) patients in whom TachoSil® was used in 18 (78.3%) and Hemopatch® in 4 (17.4%) and no sealing agent in 1 (4.3%). In comparison with all cases, a post-operative fistula occurred with TachoSil® in 6.2% and with Hemopatch® in 1.4% of cases.

In 11 (47.8%) cases, a lumbar drain was sufficient to treat the fistula. A revision surgery was performed in the remaining 12 (52.2%) cases.

A post-operative infection occurred in 5 (1.7%) cases. In 4 of those cases, TachoSil® was used as sealing agent and in 1 case no patch was used. In 3 cases, the patient presented with post-operative meningitis which could be treated with antibiotics. In those cases, a bacterium could not be isolated. In the remaining two cases, an epidural abscess had to be evacuated surgically.

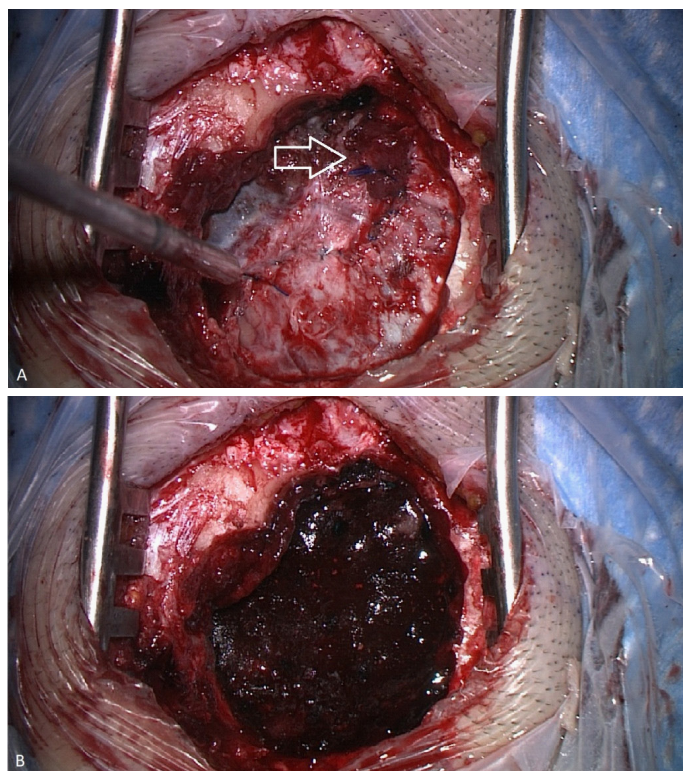


Figure 2: Intraoperative application of Hemopatch as dural sealant after retrosigmoidal approach. (A): Dural closure with small defect and muscle patch (white arrow). (B): Applied Hemopatch®.

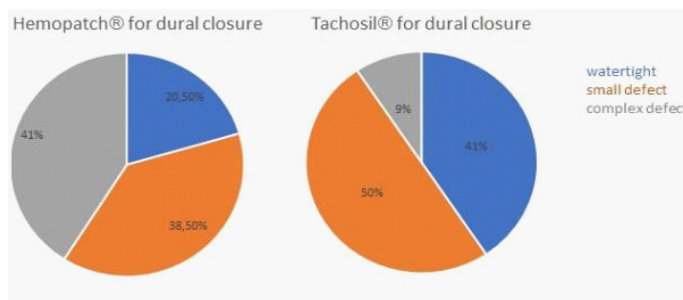


Table 1: Comparison of the type of dural closure technique and applied sealing patch.

Discussion

In our initial clinical application observation, we already reported the efficiency of Hemopatch® as a new sealing agent for dural closure in the field of neurosurgery [5].

One of the advantages of Hemopatch® over other sealing agents like TachoSil® is that it does not use human blood components. Instead of, Succinimidyl Carboxyl Methyl ester (NHS-PEG) combined with the collagen matrix is responsible for the sealant mechanism.

To verify our initial results from 37 cases in a broad clinical setting, we analyzed all our retrosigmoid approaches. We could include 288 cases and, due to the standardized approach, make a direct comparison. It is well known that dural closure after posterior fossa surgery often leads to hydrodynamic complications and sealing agents need to meet demands [8]. The risk of CSF fistula after posterior fossa surgery is with 2-17% still high [9,10]. Leading to higher risk of infection, prolonged hospital stay and up to 141% of cost increase [2,11]. Of course, these numbers depend on posterior fossa craniotomy side and extend, surgical dexterity and the type of dural repair and seal-

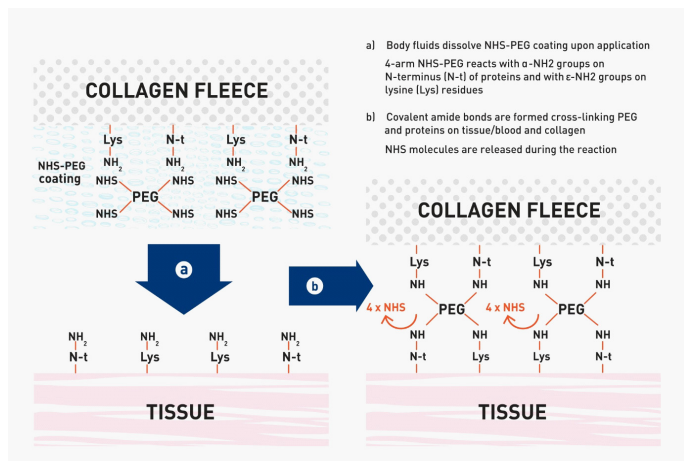


Figure 1: A chemical Model of rapid protein-reactive monomer binding to tissue through covalent amide bonds between Polyethylenglycol (PEG) and tissue proteins and collagen; provided by courtesy of Baxter USA.

ant used [12,13]. Reviewing the literature, a conclusive solution which agent for dural closure should be used cannot easily be found. Even the question of necessity remains. Hutter et al., for example, could not show a statistically significant risk reduction of postoperative CSF leakage by using TachoSil® compared to a control-group in their prospective randomized study [14].

In our series, we directly compare two different sealing patches in posterior fossa surgery. Already many studies and systemic literature reviews were conducted to proof different techniques and sealing agents [11,15]. In general, the use of dural sealants is supposed to reduce the risk of CSF leaks by supporting watertight dural closure and still having a low risk profile.

The novelty in our analysis is the use of a new type of sealant with an active agent taking part in the sealing mechanism. It is a rapid protein-reactive monomer which binds to tissue through covalent amide bonds between Polyethyleneglycol (PEG) and tissue proteins as well as collagen. One of the main advantages of this agent over fibrin sealants is the omission of human blood components. Instead of, Succinimidyl Carboxyl Methyl ester (NHS-PEG) combined with the collagen matrix is responsible for the sealant mechanism as described above. Human blood components have a minimal risk of the transmission of blood transmitted diseases. Despite the newest technical standards and precautions used by the manufacturers the possibility of nonenveloped viruses or prions being transmitted still remains [16]. One of the disadvantages of protein-based sealants is the requirement of special conditions to optimize the adhesive effect and start optimal protein degradation. This should be a dry surface (a CSF flooded surface should not be present) or the presence of blood [17].

In this comparative series between two dural sealing agents, we could confirm our previous results. In our initial clinical application observation, we could document good sealing properties of Hemopatch® with a low fistula rate of 5.9% in infra- and supratentorial application [5]. These results are comparable or even better than current Meta-Analysis may suggest with a leakage rate of up to 8.2% for fleece bound sealants [18].

In this study we could reach a leakage rate in the Hemopatch® group of only 1.4% despite the application in complicated cases in 38.5% for dural sutures with small defects and in 41% for complex duraplasty. In comparison the TachoSil® group could reach a leakage rate of 6.2% despite the use of only 9.4% in complex dural defects.

Hemopatch® is a promising new type of protein-based collagen fleece with excellent sealing properties to prevent CSF leakage and omitting human blood components. In our view, the minor disadvantages in the application are negligible. The presence of a small blood film to optimize sealing time and mechanism is not mandatory and was omitted in our surgical application. A dry field cannot always be guaranteed at neurosurgical dural closure with major dural tears. We feel that in the neurosurgical armamentarium other tools will be applied in those cases like complex autogen duraplasty.

Limitations of the study

The limitation of our study is the observational prospective design and with 288 cases still an underpowered cohort. Especially the mismatch between the TachoSil® and Hemopatch® cohort (222 vs. 39 cases) can clearly lead to a statistical bias.

Therefore, well powered prospective multicenter studies are needed to make a clear statistical impact and prove our promising results.

Conclusion

In our prospective clinical observation study, we could confirm our initial promising results of the intraoperative application of Hemopatch® as a new dural sealant. As a dural sealant in a standardized retromastoid approach Hemopatch® could keep up its good sealing performance even in comparison with TachoSil®. Again, we could demonstrate the safety and efficiency of Hemopatch® used as dural sealant even in cases where direct dural repair was not possible. To confirm our promising results of Hemopatch® as an alternative to other collagen-based sealants in the field of neurosurgery a prospective randomized controlled trial will be needed.

References

1. Kim KD, Wright NM. Polyethylene glycol hydrogel spinal sealant (DuraSeal Spinal Sealant) as an adjunct to sutured dural repair in the spine: results of a prospective, multicenter, randomized controlled study. *Spine*. 2011; 36: 1906–1912.
2. Grotenhuis JA, Costs of postoperative cerebrospinal fluid leakage: 1-year, retrospective analysis of 412 consecutive nontrauma cases. *Surg Neurol*. 2005; 64: 490–494.
3. Ozisik PA, Inci S, Soylemezoglu F, Orhan H, Ozgen T. Comparative dural closure techniques: a safety study in rats. *Surg Neurol*. 2006; 65: 42–47.
4. Kivelev J, Göhre F, Niemelä M, Hernesniemi J, Experiences with Tachosil in microneurosurgery *Acta Neurochir*. 2015; 157: 1353–1357.
5. Nowak S, Schroeder HWS, Fleck S., Hemopatch® as a new dural sealant: A clinical observation. *Clin Neurol Neurosurg*. 2019; 176: 133–137.
6. Lewis KM, Kuntze CE, Gulle H, Control of bleeding in surgical procedures: critical appraisal of HEMOPATCH (Sealing Hemostat) *Med Devices (Auckl)*. 2015; 9: 1–10.
7. Fishman AJ, Marrinan MS, Golfinos JG, Cohen NL, Roland JT. Prevention and management of cerebrospinal fluid leak following vestibular schwannoma surgery. *Laryngoscope*. 2004; 114: 501–505.
8. Nathoo N, Narotam PK. Posterior fossa duraplasty and hydrodynamic complications. *Neurosurg*. 2010; 66: E1030.
9. Bryce GE, Nedzelski JM, Rowed DW, Rappaport JM. Cerebrospinal fluid leaks and meningitis in acoustic neuroma surgery. *Otolaryngol Head Neck Surg*. 1991; 104: 81–87.
10. Danish SF, Samdani A, Hanna A, Storm P, Sutton L. Experience with acellular human dura and bovine collagen matrix for duraplasty after posterior fossa decompression for Chiari malformations. *J Neurosurg*. 2006; 104: S16–20.
11. Schiariti M, Acerbi F, Broggi M, Tringali G, Raggi A, et al. Two alternative dural sealing techniques in posterior fossa surgery: (Poly lactide-co-glycolide) self-adhesive resorbable membrane versus polyethylene glycol hydrogel. *Surg Neurol Int*. 2014; 5: 171.
12. Berjano R, Vinas FC, Dujovny M. A review of dural substitutes used in neurosurgery. *Crit Rev Neurosurg*. 1999; 9: 217–222.
13. Caroli E, Rocchi G, Salvati M, Delfini R. Duraplasty. Our current experience. *Surg Neurol*. 2004; 61: 55–59.

-
14. Hutter G, von Felten S, Sailer MH, Schulz M, Mariani L. Risk factors for postoperative CSF leakage after elective craniotomy and the efficacy of fleece-bound tissue sealing against dural suturing alone: a randomized controlled trial. *J Neurosurg.* 2014; 121: 735-744.
 15. Esposito F, Angileri FF, Kruse P, Cavallo LM, Solari D, Esposito V, Tomasello F, Cappabianca P. Fibrin Sealants in Dura Sealing: A Systematic Literature Review. *PLoS One.* 2016; 11: e0151533.
 16. Toro A, Mannino M, Reale G, Di Carlo I. TachoSil use in abdominal surgery: A review. *J Blood Med.* 2011; 2: 31–36.
 17. Bhagat V, Becker ML. Degradable Adhesives for Surgery and Tissue Engineering. *Biomolecules.* 2017; 18: 3009-3039.
 18. Kinaci A, Van Doormaal TPC. Dural sealants for the management of cerebrospinal fluid leakage after intradural surgery: Current status and future perspective. *Expert Rev Med Devices.* 2019; 16: 549-553.