



# Gangrene of Penile Skin - A Rare Entity

**Sonal Kumar Jha\***; Alisha Qamar

Northern Railway Central Hospital, New Delhi, India.

**\*Corresponding Author(s): Sonal Kumar Jha**

Northern Railway Central Hospital, New Delhi, India.

Tel: 818-687-2728 & 913-588-6065;

Email: sonaljha.jha@gmail.com &

alish.qamar@gmail.com

**Abstract**

Penile gangrene is seen infrequently but is associated with significant morbidity and mortality. Gangrene of the penis may be dry or infective.

Received: Apr 06, 2022

Accepted: Apr 28, 2022

Published Online: May 02, 2022

Journal: International Journal of Innovative Surgery

Publisher: MedDocs Publishers LLC

Online edition: <http://meddocsonline.org/>

Copyright: © Jha sk (2022). *This Article is distributed under the terms of Creative Commons Attribution 4.0 International License*

## Introduction

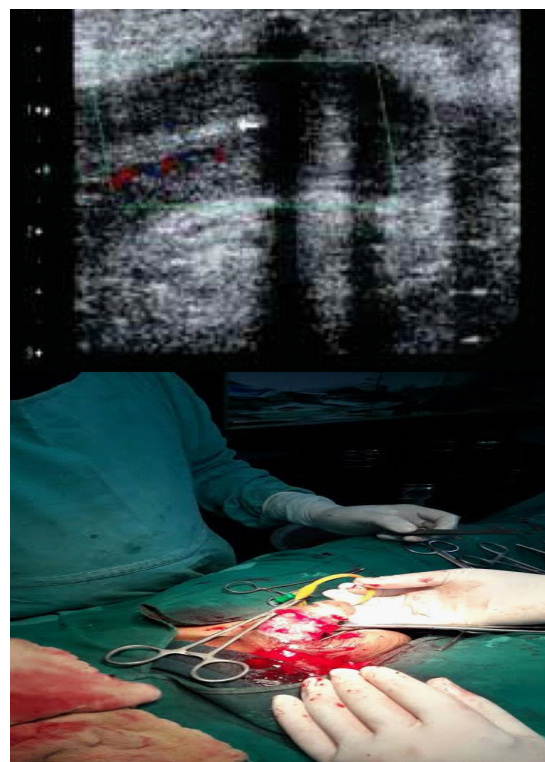
It is rare, fulminant but usually a localized disease of penis and scrotum with occasional extension up to abdominal wall.

A 27-year-old gentleman presented with pain, Fever, and brownish-black discoloration of the penis For 7-8 days; with a history of Savalon application Over the penile area for hygiene purposes. There was no h/o trauma, infection, or diabetes.

**General examination:** Febrile; no palor.

**Local examination:** brownish-black discoloration of penile skin extending up to the penoscrotal junction without any clear line of demarcation.

Penile gangrene is rare, but grave sequential following infection or ischemia. Vascular Compromise may be caused by tourniquet syndrome; priapism; venous thrombosis and anticoagulants and can also be seen in diabetics with end-stage renal disease.



**Figure 1:** USG doppler can provide information regarding thrombosis or rupture of cavernosal and dorsal penile vessels.

