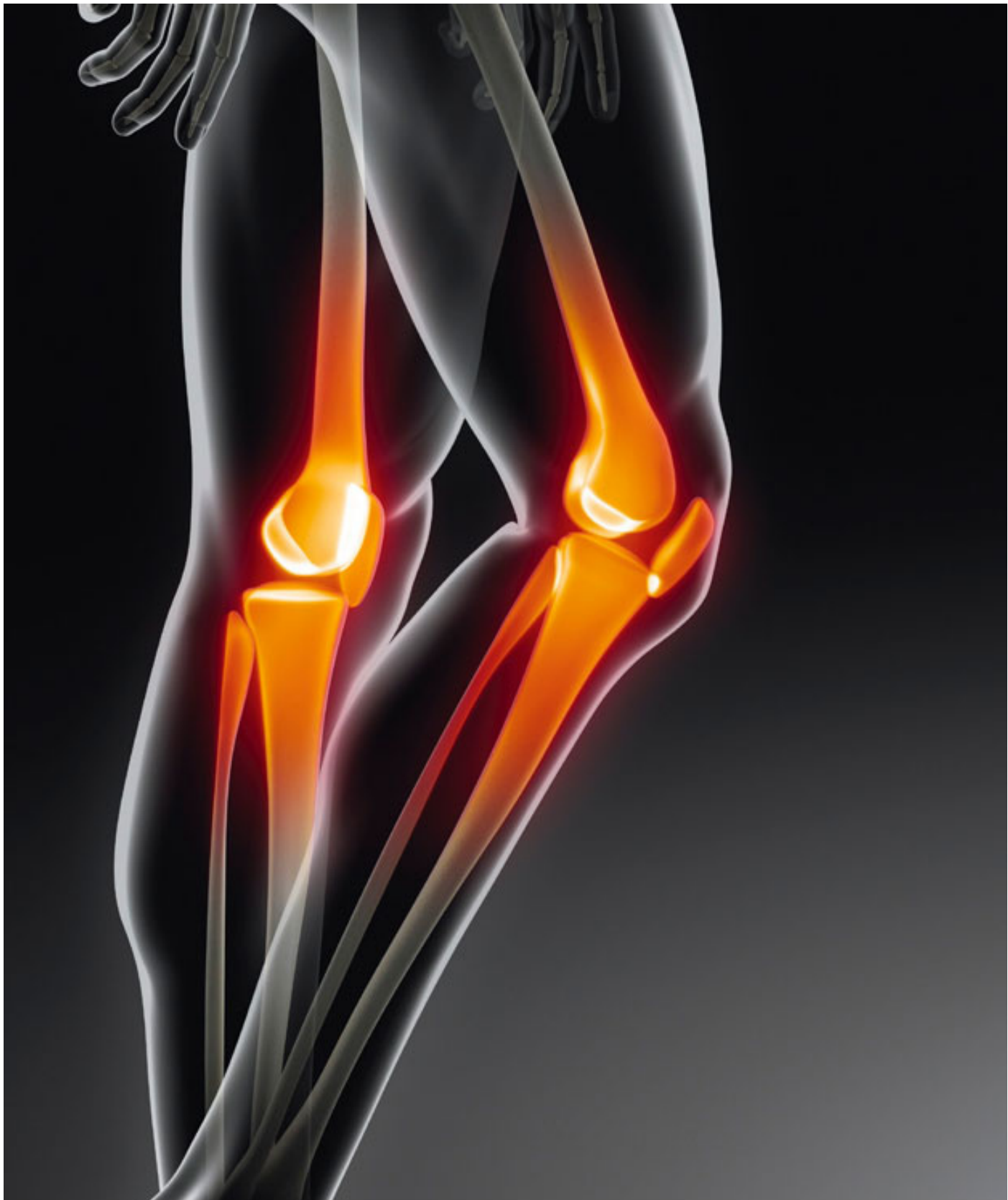



OSTEOARTHRITIS



Intoxination with Grass Pea: A Multi System Pathology: Neuro-Vasculo-Osteo-Lathyrism

Corresponding Author: George M Weisz

School of Humanities, University of New South Wales, Sydney and New England University, Armidale, Australia.

Email: gmweisz1@aol.com

Published Online: Jun 01, 2020

eBook: Osteoarthritis

Publisher: MedDocs Publishers LLC

Online edition: <http://meddocsonline.org/>

Copyright: © Weisz GM (2020).

This Chapter is distributed under the terms of Creative Commons Attribution 4.0 International License

Keywords: Toxic food; Neurological; Vascular; Bone damage.

Abstract

Grass pea consumption, the drought tolerant survival food of the poor in underdeveloped regions of the world, has been known since antiquity for producing (a quantity and quality dependant) pathological syndrome. Presented mostly in the literature as a neurological disease (spastic paralysis), whilst the two other aspects of this condition were less emphasised or not mentioned at all. These are the vascular (peripheral arterial fragility, venous insufficiency and aortic wall fragility) and the osteo (bone fragility, connective tissue degradation, legs and spinal deformities)-lathyrism. Proven experimentally, it confirmed the identity of the disease. It is but a partial review of this famine related disease.

Attempts were made in various laboratories to detoxify the plant, allowing for nutrition of starving populations. A detoxifying prophylactic method was developed, but not a curative one. This brief review, not claiming to be exclusive, offers a general description of the complete triple syndrome and of the available prophylactic measures.

Historical background

Toxicity to grass pea was known to an Indian Bhavaprakasa cult some 4000 years ago, it was known to Hippocrates some 400 years before the New Era to Galen in the second century of the New Era and during the Medieval times. It was prohibited by the Count of Wurttemberg in South-West Germany in the 1671; and was described in detail by Ramazzini from Modena in 1690 and was depicted as a "Thanks to Almorta" by Francesco Goya in early 19 C in Spain.

In the 20 century it was recognised in N. African countries, during the civil war in Spain, was weaponised by Nazi Germany during WWII. It was detected later as an endemic in Indian subcontinent (India, South China, Nepal and Bangladeshi) and in East Africa (Ethiopia, Sudan). In all these regions, grass pea

was the food of the poor, was free, with good protein nutrition [6,7].

The toxic component of the grasspea was extensively investigated and finally, separately and unknown to each other, Rao and Marty identified the toxic element to be oxyl- diamino-propionic-acid=ODAP, in the *Lathyrus sativus* legume and responsible for the neurological syndrome. At a later stage beta amino-proprio-nitrite=BAPN was found also to be toxic in another legume, namely *Lathyrus odoratum*, responsible for the vasculo-and osteo-lathyrism. Reproduced experimentally it has proven the toxicity of the agent and the effect on the respective systems.





Figure 1: Francesco GOYA: "Thanks to Almorta"



Figure 2: Grass pea, the misleading attractive plant.

The emerging disease was finally named as Lathyrism by Cantani in 1873 [1-5]. The toxin was chemically analysed and reproduced by Lambein et.al in Belgium, whilst trying to ameliorate the toxin. The plant was detoxified by C. Hunbury, (West Australian Agricultural Institute), where the scientist managed to release a toxin free legume into the wild and allow feeding of the poor. In India, in 2016, developed was a genetic variant of ODAP, a qualitative improvement, eventually leading to the eradication of Lathyrism in India [8-11].

The clinical syndrome of neuro-lathyrism

Numerous articles have been published in prestigious journals, all revealing the cortico-spinal tract and anterior horn damage, that leads to axonal loss and interference with neural transmission. It leads to spastic paralysis, weakness in the legs, scissors type of wobbling, cramps, convulsion in the legs, with normal sensation, but occasional dysaesthesia. The condition is at times accompanied by partial or complete incontinence and partial or complete erectile dysfunction. [12-14].

The severity of the syndrome is of gradual progress and was internationally classified as grading from **a.** Instability and spasm, to **b.** Reliance on one crutch support to **c.** Two crutch support and finally to **d.** the crawling phase.

On examination typical pyramidal signs are present: Brisk

knee and ankle reflexes; motor weakness but increased muscle tone, tight extensors, adductors and gastrocnemius muscles. The syndrome is more frequent in men and in the young and at risk is Group O blood group. The syndrome is progressive until a stable condition is reached (once the toxin intake has ceased) and is not life threatening.

Histologically

Degeneration of motor tracts and microgliosis of antero-lateral horn [12].

A very detailed review has attributed the naming of the disease to Selye in 1967, unaware of Cantini's record in the previous century. Equally, this otherwise excellent study stated that the osteolathyrism and vascular one has not been detected in human. This remains for the clinical examples later on in this review

The upper extremities are very rarely involved, as it is an upper neuron disease, it was localised by electrophysiological testing to the thoracic and lumbar spine [15]. There is no pathognomonic test for the diagnosis of this syndrome. Autopsy findings localised the degenerative condition in the anterior horn of the thoracic and also lumbar spine, myeline changes in the corticospinal tract [15,16]. Later on, by sophisticated MRI and Functional MRI scanning, any cerebral involvement was excluded and the pathology was localised at the mid-thoracic spinal level [16]

The syndrome is usually symmetric, occasionally only unilateral and it is irreversible, untreatable, but a preventable condition. It is prevented either by avoidance of the food intake, by amelioration with quantity restrictions or altered cooking measures. Proven in extensive Indian research, the toxicity was found that by feeding 1/3 or 1/2 of a daily diet, the accumulation of toxin will lead to lathyrism within 2-3 months. It could be ameliorated or prevented with cooking in water, but using only the paste, by cooking with onion or boiled with other vegetables [17-19].

Other preparation measures can help: Boiling in water or repeated steeping in hot water and discarding the extracts can detoxify the seeds. Roasting the seeds at 140 degree C for 15 to 20 minutes results in 80-90% destruction of the neurotoxins. Soaking the seeds or dhal overnight and decanting the water before cooking eliminates about 90% of the toxin [17-20]. All these measures will prevent or ameliorate the syndrome disease of neuro-lathyrism.

The clinical syndrome of vasculo-lathyrism

It is the result of a different type of lathyrus grass, namely Lathyrus Odoratus, at times in the same legume with lathyrus sativus or separate from it. By producing degradation of the basic connective tissue, elastine cross link change, the toxin allows for endothelial wall degradation in peripheral arteries, ending with anoxic legs, with secondary venous thrombosis and gangrene. In parallel, there is clinical and experimental proof of softening of the wall of the aorta, with diminished elastin content of the internal, middle and the external intimas, leading to aneurismal dilatation, rupture and dissection, a mechanism also reproduced experimentally. This condition is less frequently described comparatively in the literature, and will be referred to in the clinical examples later on [21,22]. This condition is enhanced in case of parallel Zinc and Copper deficiency.

Histologically

Inhibition of cross linking of Collagen and Elastine, leading to vasculo- and osteo-lathyrism [23].

The clinical syndrome of osteo-lathyrism

Experimental findings following the ingestion of lathyrus ododratu daily for 3-6 months, result in alteration in the mechanical properties of bone tissue, (proven in an X-ray Diffraction study).

The clinical syndrome in humans is of bowing of soft bones, increased fragility, infraction on the vertebral surfaces and scoliotic deformities. Radiology detects swelling of the periosteum, lack of epiphyseal closure of the pelvic bones (iliac crest and ischial tuberosity), exostosis formations and vertebral deformities due to osteoporosis. Histology showed porosis of trabeculae, collagen tissue changes and mal-alignment of the cells in the growth areas of bones. This is mostly the result of the second identified toxic amino acid (beta amino propio-nitrite) [24-29].

It is the complete clinical syndrome including all three pathologies that is so very acute and disabling. The re-emergence of interest in this rare disease in Europe began with the observations of Arthur Kessler, a general practitioner, victim of racial persecution during WWII. The detailed description of the diseases was recorded in a severe condition forced upon an incarcerated population of over 100.000 prisoners, interned in a concentration camp in the today's Ukrainian village of Vapniarka [30-33].

It is the only example of forced nutrition with Lathyrus; this was noted in a population of Jewish prisoners interned in Transnistria, west of Ukraine, a geographical territory (between the rivers Burg and Dniester), offered by the Nazi regime to Romania as a reward for their collaboration in the anti-Soviet invasion and the anti-Jewish persecution during WWII [30].

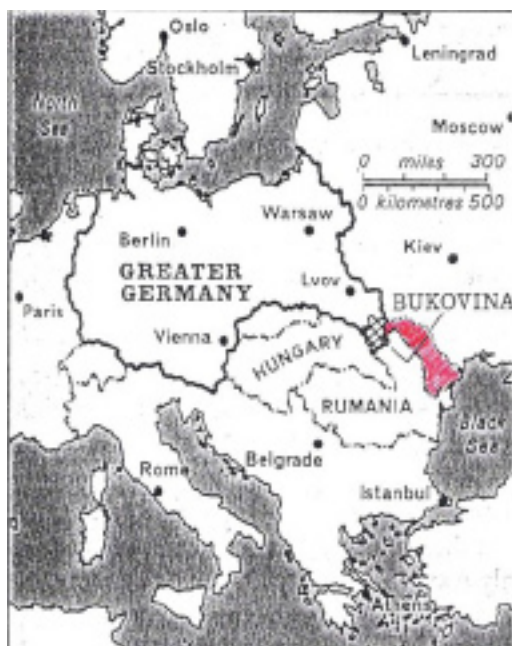

Figure 3: Map of Eastern Europe: In red the region of Transnistria.

It was the general practitioner, who studied Medicine in Vienna, but never learned about the disease, unaccounted for in Europe, who was the one to recognise in humans a toxic neuro-vasculo-osteo-clinical syndrome

Surveying the surroundings in the camp, Dr Arthur Kessel found that the departing Soviet troupes left behind a large quantity of horse fodder, containing Lathyrus, and ordered by the occupiers as food for the incarcerated population [31-33].

Prevented from import of any other food, (but the daily meagre supply of 2 slices of bread, "fruit soup" and tea sweetened with an artificial product), the symptoms of toxicity appeared in some 1800 people, 2-3 months after the daily ingestion of the cooked fodder. Dr. Kessler recorded: "*within months, hundreds of young male inmates of the camp began limping and had begun to use stick- crutches to propel themselves about, in some cases inmates had been rapidly reduced to crawling on their back sides to make their ways through the compound*".

There were detailed records on 800 patients, written by Dr Kessel on any available piece of paper. The design of the plant and clinical samples were saved from the destruction. Recorded were the gradual neurological symptoms and findings, the vascular symptoms and the resulting amputations. There was also evidence of the need for building crutches, preparing nappies and support for the dragging on the ground of fellow prisoners. Described was mobility interference (proven later on histologically to be a spinal cord degenerative process), an upper neuron disease.




Figure 4: Dr. Kessler, drawing of paretic limb.Vapniarka.1942 (supplied by Dr. D Kessler Jnr.)

The inventive physician, Arthur Kessler, improvised bandages for skin ulcerations and gangrene (for angio-lathyrism) and a relief supplied for the incontinent patient. Vascular occlusion occurred in adults and the softened bone deformity (osteo-lathyrism) appeared in developing skeletons. He quantified the toxic dosage of the grass pea to be 200 mg a day, for a 3 month period.




Figure 5: Dr. Kessler: Drawing of Lathyrus plant, Vapniarka.1942.

Dr. Kessler was fortunate to be within the surviving half of the 800,000 Jewry of pre-war Romania. His documents were hidden and published after liberation in local Israeli journals and in German-Swiss Medical Journals.

Studies on 200 survivors were published after the war, with clinical, pathological radiological findings, the gender predisposition, all raising great interest [29]. It was documented that their longevity was not affected, even though their disability was permanent.

Dr. Kessler opened a new branch of clinical research that led others to purify the Lathyrus plant, to become an alanine and ODAP free food, growing wildly in poor countries. It was researched in detail in Western Australia and once detoxified, it was allowed to grow wildly, to the benefit of the Bangladeshi population, as was in Western Australia [1,2].

Indeed famine was not justified anymore as by the end of the last century, food supply in the globe surpassed the demand, becoming sufficient to feed the entire world population.

It was the social economist Devereux, who stated that it is "*the twentieth century's shame that over 75 million people perished as a result of famine*". [34].

References

- Lathyrism in Australia <https://patient.info/doctor/lathyrism>.
- Lathyrism. <https://en.m.wikipedia.org/wiki/Lathyrism>.
- Striefler M, Cohn DF, Hirano A, Schujman: The central nervous system in a case of neurotoxic lathyrism. *Neurology*. 1977; 27: 1176-1178.
- Denny-Brown D. Neurological conditions resulting from prolonged and severe dietary restrictions. *Lathyrism Medicine*. 1947; 26: 41-44.
- Manna PK, Mohanta GP, Valliappan K, Manavalan R. Lathyrus and lathyrism: A review. *Int. J. Food Properties*. 1999; 2: 197-202.
- Haimanot RD, Feleke A, Lambein F. Is Lathyrism still endemic in Ethiopia? *Ethiop. J. Health*. 2005; 19: 230-236.
- Singh SS, Rao SLN. Lessons from neurotoxic lathyrism: A disease of the past & future of lathyrus sativus. *Ind. J. Med. Res.* 2013; 138: 32-37.
- Ludolph AC, Hugon J, Dwivedi MP, Schaumburg HH, Spencer PS. Studies on the aetiology and pathogenesis of motor neuron disease: Lathyrism. *Brain*. 1987; 110: 149-165.
- Spencer PS, Schaumburg HH. Lathyrism: A neurotoxic disease. *Lancet*. 1983; 5: 625-626.
- Spencer PS, Ludolph A, Dwivedi MP, Roy DN, Hugon J, et al. Lathyrism: Evidence for role of the neuro-excitatory amino acid, BOAA. *Lancet*. 1986; 8: 1066-1067.
- Lambein F, Ngudi DD, Kuo YH. Progress in Prevention of toxico-nutritional Neurodegeneration.
- Barrow MV, Simpson CF, Miller EJ. Lathyrism: A review. The quarterly review of biology. 1974; 49: 101-128.
- Striefler M. Chronic Central nervous system toxicity of the chickling Pea. *Clin Toxicol*. 1981; 18: 1513-1517.
- Misra UK, Mnaams DM, Shrama VP, Singh VP. Clinical aspects of neurotoxic lathyrism in Unnao, India. *Paraplegia*. 1993; 31: 249-254.
- Cohn DF, Striefler M. Human Neurotoxic Lathyrism, a follow up of 200 patients. (Part I). *Arch Suisses de Neurologie*, 1981; 128: 151-163.
- Bick AS, Meiner Z, Gotkine M, Levin N. Using advanced imaging methods to study neurotoxic lathyrism. *Isr. Med. Assoc. J.* 2016; 18: 341-345.
- Getahun H, Lambein F, Vanhoorne M, Van der Stuyf P. Food-aid cereals to reduce neurotoxic lathyrism related to grass-pea preparations during famine. *The Lancet*. 2003; 362: 1808-1810.
- Dixit GP, Parihar AK, Bohra A, Singh NP. Achievements and progress of grass-pea, on sustainable food production. *ScienceDirect: The Crop Journal*. 2016.
- Growing Ceora grass pea in Western Australia.
- Spencer PS, Palmer VS. Lathyrism: Aqueous leaching reduces grass-pea neurotoxicity. *Lancet (London, England)*. 2003; 362: 1775-1776.
- Ponsetti I, Baird WA. Scoliosis and dissecting aneurysm of the aorta in rats fed with lathyrus odoratus seed. *Am. J. Pathology*. 1952; 28: 1059-1077.
- Amato VP, Siema M, Rombelli R. Early skeletal and vascular changes in rats fed on sweet pea (*L. odoratus*). *J Bone & Joint Surg*. 1959; 41B: 601-610.
- Bornstein P. The Cross Linking of Collagen and Elastin and its inhibition in Osteolathyrism *Am J. Med.* 1970; 49: 429-435
- Cohn DF. Intoxication with Chick pea: Nervous system and Skeletal findings. *Arch. Toxicol. Suppl.* 1983; 6: 190-193.
- Paschalis EP, Tatakis DN, Robins S, Fratzl P, Manjubala I, et al. Lathyrism-induced alterations in collagen cross-links influence the mechanical properties of bone material without affecting the mineral. *Bone*. 2011; 49: 1232-1241.
- Kundell HL. Osteolathyrism in rats. *Radiology*. 1964; 82: 67-75.
- Belanger LF. Observations on the manifestations of osteolathyrism in the chick. *J. Bone & Joint Surg*. 1959; 41B: 581-589.
- Paissios CS et al: Human Lathyrism. *Clin. Orthop*. 1947; 23: 236-245.
- Weintraub S, Cohen DF, Salama M, Steifler M, Weissman SL. Skeletal Findings in Human Neurotoxic Lathyrism. *Eur. Neurol*. 1980; 19: 121-127.
- Weisz GM, Grzybowski A. Remembering more Jewish physicians. *Rambam Med. J.* 2016; 7.
- Kessler A. Lathyrismus. *Monatschrift fur Psychiatrie und Neurologie*.

gie. 1947; 113: 23-33.

32. Kessler D. Remembering Dr Arthur Kessler (1903-2000). Lathyrus Newsletter, W.A. Australia. 2003.
33. CCDN, Cassava Cyanide Diseases & Neurolathyrism Network. 2015: 1-3.
34. Devereux S. Famine in the twentieth century. 1988. IDS working paper 105, Inst. of Development website.