

ALZHEIMER'S DISEASE AND TREATMENT




MEDDOCS
— International —

Treatment of CSVD in Alzheimer's Disease by means of Transcatheter Intracerebral Laser Exposure

Corresponding Author: Ivan V Maksimovich

Clinic of Cardiovascular Diseases named after Most Holy John Tobolsky, Moscow, Russia

Email: carvasc@yandex.ru; Tel: +7 903 7240277

Published Online: Dec 21, 2017

eBook: Alzheimer's Disease & Treatment

Publisher: MedDocs Publishers LLC

Online edition: <http://meddocsonline.org/>

Copyright: © Maksimovich IV (2017).

This article is distributed under the terms of Creative Commons Attribution 4.0 International License

Keywords: Alzheimer's Disease; Dementia; CSVD; Angiogenesis; TDR; Dyscirculatory Angiopathy of Alzheimer's Type; DAAT; Transcatheter Intracerebral Laser Revascularization

Abstract

Introduction: Cerebral Small Vessel Disease (**CSVD**) is one of the causes of AD development. This research focuses on the changes in dementia and cognitive functions in AD after restoration of cerebral distal arterial and capillary blood supply by transcatheter intracerebral laser revascularization. It also compares the results of this method with those of widespread conservative methods.

Materials and Methods: 200 patients with AD were examined. The examination plan included dementia severity Clinical Determination (**CDR**), cognitive functions assessment (MMSE), laboratory examination, cerebral Scintigraphy (**SG**), Rheoencephalography (**REG**), cerebral CT and MRI, AD stages morphometric detection (TDR), cerebral Multi-Gated Angiography (**MUGA**).

93 patients aged 34-80 (mean age 67.5) were selected, 32 (34.40%) men, 61 (65.59%) women.

According to AD severity, the patients were divided into: TDR-0 (preclinical stage) - 10 (10.75%) patients, TDR-1 (early stage) - 26 (27.96%), TDR-2 (middle stage) - 40 (43.01%), TDR-3 (late stage) - 17 (18.28%).

Test Group - 48 (51.61%) patients underwent transcatheter intracerebral treatment by low-energy lasers.

Control Group - 45 (48.39%) patients had conservative treatment with Memantin and Rivastigmine.

Results: In the Test Group, improvement in cerebral microcirculation was obtained, which led to persistent dementia decline and to cognitive functions recovery, and allowed the patients to be transferred to a minor TDR group or taken outside the scale.

In the Control Group, patients with earlier AD stages (TDR-0, TDR-1) were stabilized for a period of 0.5-3 years followed by an increase in dementia and cognitive impairment. Patients with advanced AD (TDR-2, TDR-3) faced further dementia increase and cognitive impairment.

Conclusion: The method of transcatheter intracerebral laser revascularization is a pathogenetically justified and effective method of treating CSVD in AD. Due to angiogenesis stimulation, it restores collateral and capillary blood supply, improves cellular and tissue metabolism, and promotes amyloid beta excretion from the cerebral tissue and vascular wall and the development of reparative processes.



Introduction

The etiology and pathogenesis of AD has not been fully studied yet. Considering the origin of this disease, it is necessary to take into account that AD develops not only because of disorders in amyloid beta and tau metabolism in the cerebral tissue and vascular wall, but also due to disorders in cerebral angioarchitectonics, reduction of cerebral microcirculation and development of cerebral hypoperfusion [1-11]. The complex of these vascular and microcirculatory changes can be called Cerebral Small Vessel Disease (CSVD) in AD [12-15]. For the first time vascular contribution to the development of this disease was noted by F. Morel, who described dysoric or druzoidal angiopathy in AD in the 1930s [16].

Vascular and microcirculatory disorders in AD are specific and complex. They begin to develop with disorders of capillary blood supply [4,7,9,17-20]. There begins a decrease in the number of capillaries in the hippocampus tissue. They get thinner, and there is a decrease in distal branching, which leads to the development of hypoxia due to a decrease in the distal arterial influx [4,7-10]. The process is accompanied by the development of hypovascular regions in the temporal and frontoparietal regions [8,9,17-19,21]. As a result, mitochondria die in the cells of the smooth endoplasmic reticulum and the Golgi apparatus, and there is loss of synapses, degeneration and death of neurons [9,12,17-20]. The combination of cerebral microcirculatory, hemodynamic and tissue damage is defined as Neurovascular Unit (NVU) lesion [5-7,22].

The blood flowing through larger arterial branches cannot pass through the reduced arterioles and capillaries. As a result, arteriovenous shunts open in the temporal and frontoparietal regions [8,19]. This process is a natural response of the body to disorders in blood passage through arterioles and capillaries [4,8]. Consequently, arterial blood is dumped into the venous bed causing stasis and disorders in venous outflow, which causes even more damage to cerebral hemodynamics [19].

Developed capillary and hemodynamic disorders cause a decrease in excretion and an increase in the accumulation of amyloid beta [5,7,13]. The deposition of amyloid in the cerebral tissue and especially in the vascular wall leads to a decrease in the elasticity of micro-vessels and reduces their lumen, thereby causing an even greater reduction in cerebral blood flow [11].

The combination of all these processes induces further disorders in cerebral microcirculation promoting the development of hypoxia [11,15,23] and the dysfunction of the Blood-Brain Barrier (BBB) [23-25].

Simultaneously, AD development is accompanied by a decrease in natural intracerebral angiogenesis [19,20]. The resulting cerebrovascular changes lead to increased tortuosity of distal arterial branches and capillaries [4,8].

The combination of these particular changes in cerebral angioarchitectonics and CSVD can be found only in patients with AD. It is included into the concept of "Dyscirculatory Angiopathy of Alzheimer's Type (DAAT)" [4,8,19,21,26]. The combination of similar changes is not found in patients suffering from other neurodegenerative diseases [4,19,26].

The more pronounced these disorders are, the faster cerebral hypoxia is aggravated and the faster AD develops [8,12,26,27]. As a result, the disease progresses and its clinical symptoms increase [5,11,21].

More and more authors have been indicating the need to develop new methods of treating AD aimed at restoring cerebral blood supply and microcirculation [4,10,19,23], including low-energy lasers [8,12,21,26].

In modern literature, there has appeared a large number of experimental and clinical studies devoted to successful use of transcranial "Low Level Laser Therapy" (LLLT), or photobiomodulation, in the treatment of dementia and AD. These studies showed a good positive effect of the therapy [27-33].

However, when carrying out transcranial photobiomodulation, it is necessary to take into account that the bones of the human skull are quite thick and have high optical density. Therefore, when a coherent light flux passes through them, there is a significant absorption of laser energy, and only an insignificant part of it reaches the cerebral tissue [35]. The bones of the skull of small experimental animals are much thinner than the bones of the human skull; they absorb laser energy to a lesser extent, hence a greater amount of energy reaches cerebral tissues. In clinical conditions, it is necessary to consider more efficient ways of delivering laser energy to the cerebral tissue.

When creating new methods of treating AD, it is necessary to work out new and more effective methods of influencing CSVD. These new methods should be aimed at cerebral revascularization, restoration of the distal arterial and microcirculatory bed, which would improve metabolic and reparative processes in the cerebral tissue.

The present work is devoted to:

- 1) the study of the changes in dementia and cognitive functions, as well as cerebral reparative opportunities in AD after restoration of cerebral distal arterial and capillary blood supply by transcatheter intracerebral laser revascularization;
- 2) comparison of the results of this method with those of widespread conservative methods.

Materials & Methods

All the examinations and transcatheter interventions have been carried out with the approval of the ethics committee, as well as with the consent of the examined and treated patients and their relatives.

Criteria for selecting patients:

- 1) the consent of the patients and their relatives for carrying out the necessary examination and treatment;
- 2) the patients' somatic state making examination and treatment possible;
- 3) the level of dementia, cognitive disorders, atrophic changes in the temporal and frontoparietal regions of the brain.

Of the 200 patients with different stages of AD, 93 patients aged from 34 to 80 (mean age 67.5) were selected, 32 (34.40%) men and 61 (65.59%) women.

The study included patients with different AD stages without serious co-morbidities, who were in satisfactory somatic state in accordance with their age.

Patient Examination Plan

The examination plan included:

- Clinical severity of dementia was determined using the Clinical Dementia Rating scale (**CDR**) [35]. The first examination was conducted at the admission of the patient, the second one at her/his discharge, and further ones with an interval of 6-12 months;

- Cognitive functions assessment was performed using the Mini-Mental State Examination (**MMSE**) [36]. The first testing was conducted at the admission of the patient, the second one at her/his discharge, and further ones with an interval of 6-12 months;

- Laboratory examination included coagulologic, biochemical and general clinical tests that were done on admission and further on in accordance with what the symptoms required [8,19,21];

- Brain Scintigraphy (**SG**) in dynamic and static modes (using TC 99M Perchnetate 555) was performed on a gamma camera of "Ohio Nuclear", USA. The first examination was carried out at the admission of the patient, further ones followed in the period of 6-12 months [19,21];

- Rheoencephalography (**REG**) with the determination of disorders in pulse blood filling in the cerebral hemispheres was performed using "Reospectr-8" by Neurosoft Company, Russia. The first examination was carried out at the admission of the patient, further ones followed in the period of 6 to 12 months [8,21];

- CT and MRI of the brain were performed by means of "Somatom" (Siemens), "Hi Speed" (GE), "Tomoscan" (Philips), "Apetro Eterna" (Hitachi). In the course of the examination, the ATAA (Advance Tomo Area Analysis) technique was used. This technique allows determining the percentage of a decrease in the tissue volume of temporal lobes in comparison with their natural volume, showing involuntional changes in temporal lobes [19]. Simultaneously, the Tomography Dementia Rating scale (**TDR**) was used to determine the severity of dementia and AD stages [37]. This method allows determining the stage of dementia in AD by the degree of atrophic changes in the temporal lobes, which is identified by means of CT and MRI. The first examination was carried out at the admission of the patient and was followed by further ones in the period of 6-12 months;

- Cerebral Multi-Gated Angiography (**MUGA**) was performed on "Advantx" (GE). With the help of transfemoral access, according to the classical injection technique, Omnipak 350 was administered: 10-12 ml intra-carotidally and 7-8 ml intra-vertebrally. The procedure was performed in direct and lateral projection with a recording rate of 25 frames per second using the constant subtraction mode [4,8]. Capillary blood flow was examined using the "Angio Vision" computer program [8,19]. This program allows you to inspect the changes in the density and the number of black pixels in a certain area of a cerebral angiographic image while radiopaque substance passes through arterioles and capillaries [19,26]. Recently, Philips has proposed a similar program supplemented by the addition of 2D effects [38].

Results of the Examination of the Patients

Based on CDR test results, dementia of various severities was detected in 83 (89.25%) patients.

MMSE showed cognitive impairment of various severities in all 93 (100%) patients.

The results of the laboratory examination revealed no gross deviations.

SG demonstrated a decrease in blood flow in the cerebral hemispheres in all 93 (100%) patients.

REG detected a decrease in the volume of pulse blood in carotid basins in all 93 (100%) patients.

CT and MRI revealed involuntional changes in the brain accompanied by atrophy of temporal lobes of varying severity in all 93 (100%) patients. Morphometric determination of the stages of dementia was carried out in all 93 (100%) patients.

MUGA showed CSVD manifested in Dyscirculatory Angiopathy of Alzheimer's type (**DAAT**) in all 93 (100%) patients.

Features of CSVD (DAAT) in AD in the examined patients:

- Reduction of the number of arterioles and capillaries in the temporal and frontoparietal regions was revealed in all 93 (100%) patients;

- Development of multiple arteriovenous shunts in the basins of arteries which supply blood to temporal and frontoparietal regions was detected in all 93 (100%) patients;

- Early venous dumping of arterial blood through the shunts into the venous bed was detected in all 93 (100%) patients;

- Abnormal expansion of lateral venous branches which receive the blood from arteriovenous shunts was revealed in 84 (90.32%) patients;

- Stagnation of venous blood at the border of the frontal and parietal regions due to excessively increased blood flow from arteriovenous shunts was detected in 85 (91.40%) patients;

Increased looping of distal intracranial arterial branches was revealed in 74 (79.57%) patients.

Selection of the Patients

In accordance with the severity of dementia and cognitive impairment, examined patients were divided into the following groups:

- 10 (10.75%) patients had preclinical AD stage - TDR-0. They showed no signs of dementia while had increasing memory disorders and a decrease in cognitive functions to 26-28 MMSE points. Cerebral involuntional changes were manifested by atrophy of temporal lobes with a 4-8% decrease in tissue volume. It should be noted that each of these patients had direct relatives suffering from AD;

- 26 (27.96%) patients had early AD stage - TDR-1 corresponding to mild dementia. Clinically, dementia was determined at the level of CDR-1; cognitive functions were reduced to 20-25 MMSE points. Cerebral involuntional changes were manifested by atrophy of temporal lobes with a 9-18% decrease in tissue volume; the anamnesis of the disease was 2 years;

- 40 (43.01%) patients had middle AD stage - TDR-2 corresponding to moderate dementia. Clinically, dementia was determined at the level of CDR-2; cognitive functions were reduced to 12-19 MMSE points. Cerebral involuntional changes were manifested by atrophy of temporal lobes with a 19-32% decrease in tissue volume; the anamnesis of the disease was 2-6 years;

17 (18.28%) patients had advanced AD stage - TDR-3 corresponding to severe dementia. Clinically, dementia was determined at the level of CDR-3; their cognitive functions were reduced to 7-11 MMSE points. Cerebral involutions changes were manifested by atrophy of temporal lobes with a 33-62% decrease in tissue volume; the anamnesis of the disease was 7-11 years.

Test Group

Test Group 48 (51.61%) patients, 17 (35.42%) men, 31 (54.58%) women underwent transcatheter endocerebral laser revascularization. In accordance with the severity of dementia, patients were divided:

- TDR-0: 4 patients;
- TDR-1: 16 patients;
- TDR-2: 21 patients;
- TDR-3: 7 patients.

In the group of patients with TDR-0 preclinical stage of the disease, transcatheter intracerebral laser interventions were performed prophylactically, against the backdrop of increasing memory impairment.

In groups of patients with TDR-1, TDR-2, TDR-3 with AD, intracerebral laser interventions were performed in the period from 1 to 12 years from the moment of manifestation of the symptoms of the disease.

The Method of Transcatheter Intracerebral Laser Revascularization

Using local anesthesia, in accordance with Seldinger's method, the common femoral artery is punctured and cathetered with an introducer of 6-7F in diameter. Through this introducer, guiding catheters are coaxially conducted and installed in the internal carotid artery. Through these catheters, a thin, flexible, fiber-optic light guide tool is guided. This fiber-optic tool has a diameter of 25 to 100 micrometers and is connected to a laser apparatus. It is conducted to the distal sections of anterior and middle cerebral arteries, where laser exposure is carried out [39]. The light guide tool is constantly washed with heparinized 0.9% NaCl solution. If necessary, for X-ray television control, Omnipack 350 solution is injected periodically, in small doses. The laser exposure is performed using a low-energy laser with a wavelength of 633 nanometers and a power of 20 mW. The laser exposure time is about 20-40 minutes [40]. After the intracerebral intervention, second cerebral MUGA is done. Based on the results, the severity of intracerebral angiogenesis, the degree of collateral revascularization and restoration of the microcirculatory bed are considered [21].

After the intracerebral transcatheter exposure the patients underwent disaggregate, anticoagulant, antioxidant, vasodilating and nootropic therapy. The patients took Aspirin in accordance with their blood coagulation system parameters, Heparin, indirect anticoagulants, 100 mg of Pentoxifylline, 150 mg of Complamin, 200 mg of Inosin, 1200 mg of Nootropil (Piracetam) (or 1000 mg of Gliatilin) intravenously, by means of a drop counter, No. 10-15, followed by oral forms. Later, the courses of pills were repeated twice a year. The patients did not receive any specific therapy aimed at treating AD.

Control Group

Control Group 45 (48.39%) patients, 16 (35.36%) men and 39 (64.44%) women, to whom conservative treatment was applied.

According to the severity of dementia, the patients were divided:

- TDR-0: 6 patients;
- TDR-1: 13 patients;
- TDR-2: 15 patients;
- TDR-3: 11 patients.

Conservative treatment was carried out according to conventional schemes [41, 42]. Patients from TDR-0 group received 2400 mg of Nootropil (Piracetam) per day (courses of 3-4 months) or 1200 mg of Gliatilin per day (courses of 4-6 months). Patients from groups TDR-1, TDR-2, TDR-3 received 5-20 mg of Memantin per day or 3-12 mg of Rivastigmine per day. Simultaneously, patients of all groups received vasoactive drugs, Pentoxifylline, 800 mg per day for 3 months, and Complamin, 450 mg per day for 2-3 months, which was repeated twice a year.

Results

Test Group

Immediate Results: There were no complications either during intracerebral interventions or in the early and in the distant periods after it.

According to the data of the repeated cerebral MUGA performed after the endocerebral treatment, all 48 (100%) patients demonstrated a good immediate result manifested in stimulation of natural angiogenesis, improvement and restoration of collateral and capillary blood supply, reduction of arteriovenous shunts, and in improvement of venous outflow (**Figure 1-4**).

Early Period (1-6 Months) after the Intracerebral Treatment

Patients with preclinical AD stage (TDR-0): Clinically, all 4 (100%) patients had memory improvement and recovery of cognitive functions of up to 28-30 MMSE points.

According to CT and MRI, all 4 (100%) patients experienced an increase in the volume of cerebral temporal lobes, narrowing of the Sylvian fissures, and recovery of the subarachnoid space.

SG and REG showed that all 4 (100%) patients had recovery of blood flow and pulse blood flow in the cerebral hemispheres.

Patients with early AD stage (TDR-1): Clinically, all 16 (100%) patients had a decrease in the level of dementia. 6 (37.50%) of them recovered cognitive functions up to 25-26 MMSE points and 10 (62.50%) patients - up to 27-28 MMSE points.

CT and MRI showed that all 16 (100%) patients experienced an increase in the volume of cerebral temporal lobes, narrowing of the Sylvian fissures, and recovery of the subarachnoid space.

SG and REG demonstrated that all 16 (100%) patients had restoration of blood flow and pulse blood flow in the cerebral hemispheres.

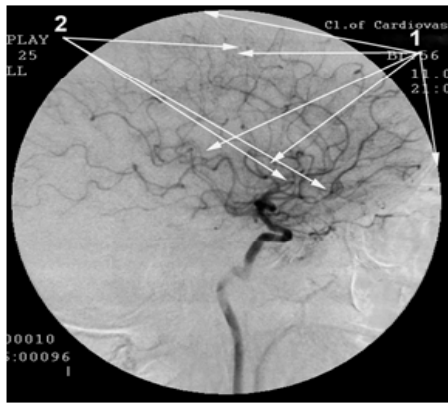


Figure 1: Patient A., 56 years old, male (TDR-2) before transcatheter intracerebral laser exposure. Left internal carotid artery angiogram, arterial phase.
 1. Hypovascular areas in temporal and frontoparietal regions.
 2. Multiple arteriovenous shunts in temporal and frontoparietal regions.

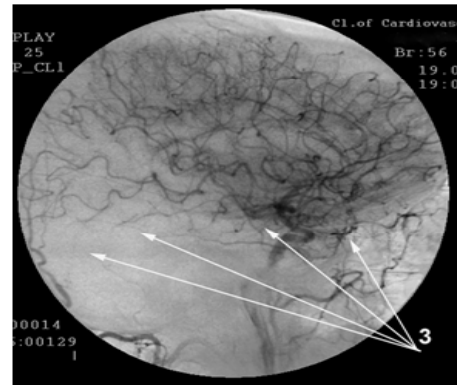


Figure 4: Same patient A., 56 years old, after transcatheter intracerebral laser exposure. Left internal carotid artery angiogram, late arterial phase. Reduction of arteriovenous shunts in temporal and frontoparietal region.
 3. No simultaneous contrasting of arteries and veins.

Patients with middle AD stage (TDR-2)

Clinically, all 21 (100%) patients had a decrease in the level of dementia. 12 (57.14%) of them featured improvement of cognitive functions to 19-20 MMSE points, and 9 (42.86%) patients - to MMSE 21-22 points.

CT and MRI demonstrated that all 21 (100%) patients had an increase in the volume of cerebral temporal lobes, narrowing of the Sylvian fissures, and a decrease in the subarachnoid space.

SG and REG showed that all 21 (100%) patients had positive dynamics of blood flow velocity and pulse blood filling in the cerebral hemispheres.

Patients with advanced AD stage (TDR-3)

Clinically, all 7 (100%) patients experienced a decrease in the level of dementia, as well as improvement of cognitive functions of up to 11-12 MMSE points.

CT and MRI revealed that all 7 (100%) patients showed a tendency to an increase in the volume of cerebral temporal lobes, narrowing of the Sylvian fissures and to a decrease in the subarachnoid space.

SG and REG showed that all 7 (100%) patients had positive dynamics of blood flow and pulse blood flow in the cerebral hemispheres.

Long-Term Period (1-7 years) after the Intracerebral Treatment

Patients with preclinical AD stage (TDR-0): Clinically, all 4 (100%) patients experienced persistent recovery of memory and cognitive functions up to 28-30 MMSE points (**Table 1**).

CT and MRI showed recovery of the volume of cerebral temporal lobes, narrowing of Sylvian fissures and recovery of subarachnoid space in all 4 (100%) patients a year after the intracerebral transcatheter treatment. Consequently, all 4 (100%) patients were transferred to a group of practically healthy people, in accordance with the criteria listed above.

SG and REG demonstrated that all 4 (100%) patients had recovery of blood flow and pulse blood filling in the cerebral hemispheres.

The obtained positive dynamics persisted during the whole examination period.

Patients with early AD stage (TDR-1): Clinically, all 16 (100%)

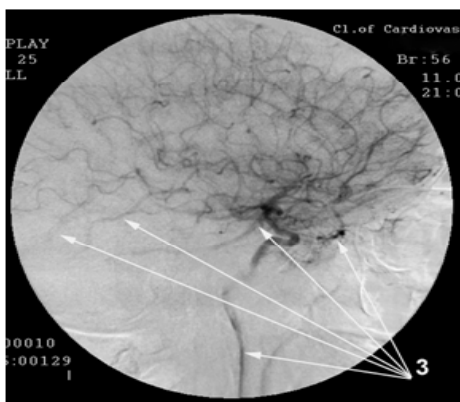


Figure 2: Same patient A., 56 years old, male (TDR-2) before transcatheter intracerebral laser exposure. Left internal carotid artery angiogram, late arterial phase. Dumping of arterial blood through arteriovenous shunts into venous channel.
 3. Simultaneous contrast of arteries and veins.

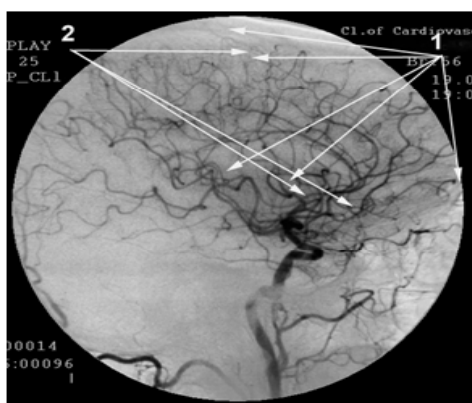


Figure 3: Same patient A., 56 years old, after transcatheter intracerebral laser exposure. Left internal carotid artery angiogram, arterial phase.
 1. Stimulation of ateliogenesis, collateral and capillary bed recovery in temporal and frontoparietal region.
 2. Closing of arteriovenous shunts.

patients had no evidence of dementia. They also experienced persistent recovery of cognitive functions to 27-28 MMSE points (**Table 1**).

CT and MRI showed that all 16 (100%) patients had almost complete recovery of cerebral temporal lobes volume, narrowing of the Sylvian fissures and recovery of the subarachnoid space (residual atrophy comprised 4-6%, which corresponds to the age norm). Consequently, all 16 (100%) patients, in accordance with the criteria listed above, were transferred to TDR-0 group.

SG and REG revealed that all 16 (100%) patients featured normalization of blood flow velocity and pulse blood filling in the cerebral hemispheres.

The obtained positive dynamics persisted during the whole examination period.

Patients with middle AD stage (TDR-2): Clinically, there was a decrease in the level of dementia, as well as improvement of cognitive functions to 21-22 MMSE points in all 21 (100%) cases in a year after the transcatheter treatment. In the more distant period, 12 (57.14%) patients experienced a further decrease in the level of dementia and recovery of cognitive functions up to 21-25 MMSE points. In 9 (42.86%) cases, cognitive functions were preserved at the level of 21-22 MMSE points (**Table 1**).

In all 21 (100%) cases, the condition lasted for about 4 years, after which there was a decrease in cognitive functions to 20-21 MMSE points.

When CT and MRI were performed a year after the treatment, all 21 (100%) patients showed an increase in the volume of cerebral temporal lobes, narrowing of the Sylvian fissures and the subarachnoid space. In the more distant period, a further decrease in the atrophy of the temporal lobes to the level of

15-18% was noted in 12 (57.14%) cases. 9 (42.86%) patients had no further decrease in the atrophy. Consequently, 21 (100%) patients were transferred to TDR-1 group according to the criteria listed above.

When SG and REG were performed, all 21 (100%) patients had positive dynamics of blood flow and pulse blood flow in the cerebral hemispheres.

Patients with severe AD stage (TDR-3): Clinically, there was a decrease in the level of dementia, as well as an improvement in cognitive functions in all 7 (100%) cases one year after the transcatheter treatment. In 4 (57.14%) of them, improvement was up to 11-14 MMSE points, in 3 (42,86%) cases - up to 15-19 MMSE points (**Table 1**).

When CT and MRI were performed one year after the treatment, all 7 (100%) revealed a decrease in the atrophy of the cerebral temporal lobes to a level of 28-34%, narrowing of the Sylvian fissures and the subarachnoid space. Consequently, 5 (71.43%) patients were transferred to TDR-2 group according to the criteria listed above.

The stable condition lasted for 2-2.5 years, after which there was a decrease in cognitive functions up to 11-12 MMSE points.

When SG and REG were performed, all 7 (100%) patients had positive dynamics of blood flow and pulse blood flow in the cerebral hemispheres.

In the period from 2 to 6 years after the transcatheter treatment, repeated cerebral MUGA was performed in 9 (21.74%) cases. All 9 (21.74%) patients had further progression of angiogenesis, accompanied by collateral and capillary revascularization (**Figure 5-10**).

Table 1. Clinical results of treatment of study and control groups patients in the long-term period.

GROUP	Summary Frequency Table							Totals
	Treatment Method	Severity Degree before Treatment	Severity Degree after Treatment Healthy	Severity Degree after Treatment TDR-0	Severity Degree after Treatment TDR-1	Severity Degree after Treatment TDR-2	Severity Degree after Treatment TDR-3	
Test Group	Transcatheter	TDR-0	4	0	0	0	0	4
Column Percentage			100.00%	0.00%	0.00%	0.00%		
Row Percentage			100.00%	0.00%	0.00%	0.00%	0.00%	
Sample Proportion			4.30%	0.00%	0.00%	0.00%	0.00%	4.30%
Test Group	Transcatheter	TDR-1	0	16	0	0	0	16
Column Percentage			0.00%	100.00%	0.00%	0.00%		
Row Percentage			0.00%	100.00%	0.00%	0.00%	0.00%	
Sample Proportion			0.00%	17.20%	0.00%	0.00%	0.00%	17.20%
Test Group	Transcatheter	TDR-2	0	0	21	0	0	21
Column Percentage			0.00%	0.00%	100.00%	0.00%		
Row Percentage			0.00%	0.00%	100.00%	0.00%	0.00%	

Sample Proportion			0.00%	0.00%	22.58%	0.00%	0.00%	22.58%
Test Group	Transcatheter	TDR-3	0	0	0	5	2	7
Column Percentage			0.00%	0.00%	0.00%	100.00%		
Row Percentage			0.00%	0.00%	0.00%	71.43%	0.00%	
Sample Proportion			0.00%	0.00%	0.00%	5.38%	0.00%	7.53%
Test Group TOTALS			4	16	21	5	2	48
Sample Proportion			8.33%	33.33%	43.75%	10.42%	4.17%	100.00%
Control Group	Therapeutic	TDR-0	0	3	3	0	0	6
Column Percentage				100.00%	60.00%	0.00%	0.00%	
Row Percentage			0.00%	50.00%	50.00%	0.00%	0.00%	
Sample Proportion			0.00%	3.23%	3.23%	0.00%	0.00%	6.45%
Control Group	Therapeutic	TDR-1	0	0	2	11	0	13
Column Percentage				0.00%	40.00%	100.00%	0.00%	
Row Percentage			0.00%	0.00%	15.38%	84.62%	0.00%	
Sample Proportion			0.00%	0.00%	2.25%	12.36%	0.00%	13.98%
Control Group	Therapeutic	TDR-2	0	0	0	0	15	15
Column Percentage				0.00%	0.00%	0.00%	57.69%	
Row Percentage			0.00%	0.00%	0.00%	0.00%	100.00%	
Sample Proportion			0.00%	0.00%	0.00%	0.00%	16.13%	16.13%
Control Group	Therapeutic	TDR-3	0	0	0	0	11	11
Column Percentage				0.00%	0.00%	0.00%	42.31%	
Row Percentage			0.00%	0.00%	0.00%	0.00%	100.00%	
Sample Proportion			0.00%	0.00%	0.00%	0.00%	11.83%	11.83%
Control Group TOTALS			0	3	5	11	26	45
Sample Proportion			0.00%	6.67%	11.11%	24.44%	57.78%	100.00%
Column Total			4	19	26	16	28	93
Total percentage			4.30%	20.43%	27.96%	17.20%	30.11%	100.00%

The original data, the distribution of which is given in the summary table, were analyzed using the nonparametric Mann-Whitney test. The statistical analysis showed that at the beginning of the therapy there were no significant differences between the Test and Control Groups ($p > 0.05$), while after the treatment these differences became significant ($p < 0.01$). The analysis of the indicator dynamics by means of the Mann-Whitney test also revealed significant differences between the groups: the effect of the therapy in the Test Group was significantly higher than in the Control Group ($p < 0.01$).

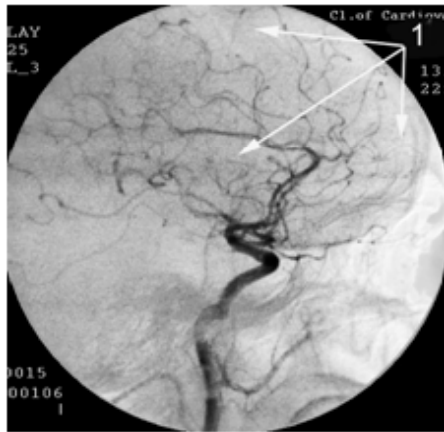


Figure 5: Patient T., 61 years old, male(TDR-2) before transcatheter intracerebral laser exposure.
Left internal carotid artery angiogram, arterial phase.
1. Hypovascular areas in temporal and frontoparietal regions.

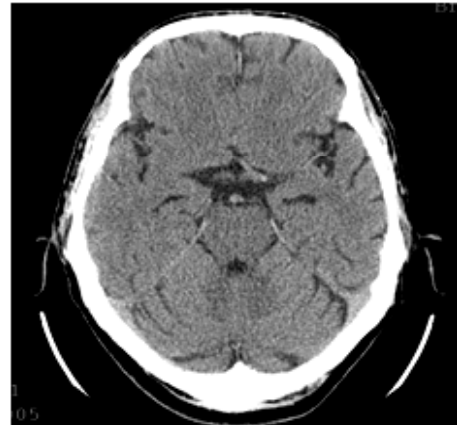


Figure 8: Same patient T., 61 years old (TDR-2) before transcatheter intracerebral laser exposure. Brain CT.
Decrease in temporal lobes volume:
left by 22%
right by 28%

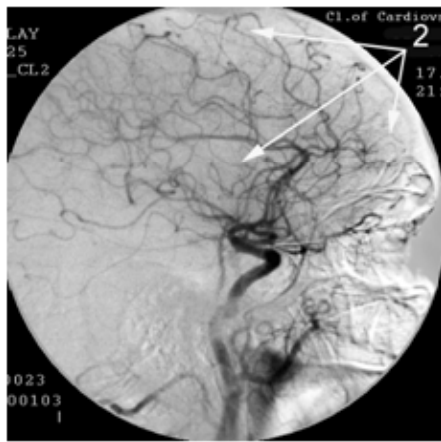


Figure 6: Same patient T., 61 years old, after transcatheter intracerebral laser exposure.
Left internal carotid artery angiogram, arterial phase.
1. Stimulation of atehiogenesis, collateral and capillary bed recovery in temporal and frontoparietal region.

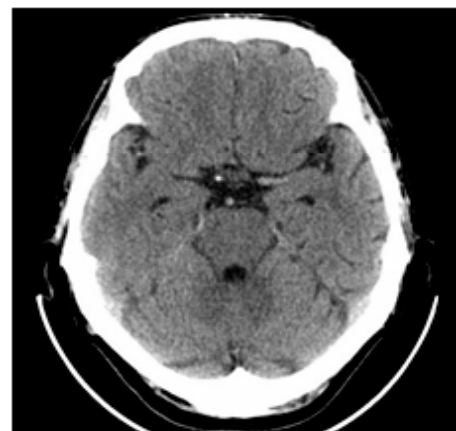


Figure 9: Same patient T., 62 years old, a year after transcatheter intracerebral laser exposure. Brain CT.
Recovery of temporal lobes volume:
left by 10%
right by 12%

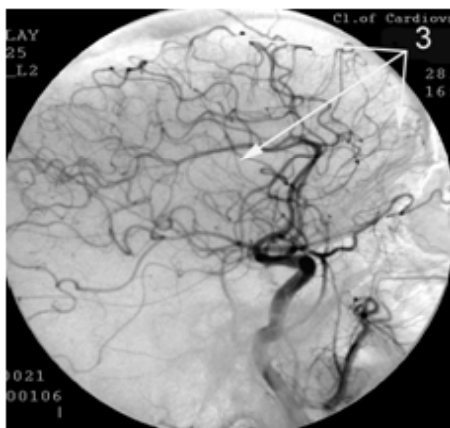


Figure 7: Same patient T., 66 years old, 5 years after transcatheter intracerebral laser exposure.
Left internal carotid artery angiogram, arterial phase.
3. Further progression of atehiogenesis, enhancement of collateral and capillary bed in temporal and frontoparietal region.

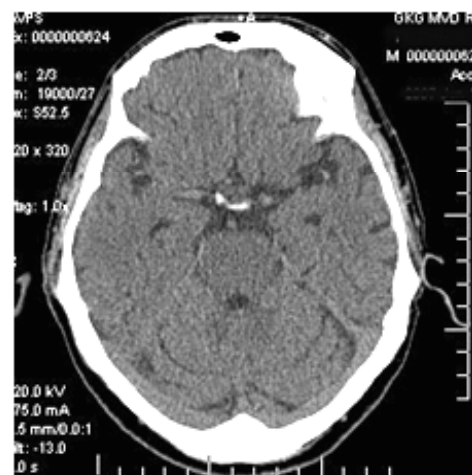


Figure 10: Same patient T., 66 years old, 5 years after transcatheter intracerebral laser exposure. Brain CT.
Recovery of temporal lobes volume to age norm.

Control Group

Early period (1-6 months) after the start of conservative treatment.

Clinically, patients with preclinical AD stage (TDR-0) have a tendency to memory improvement and cognitive functions recovery to 27-28 MMSE points.

Patients from groups TDR-1 and TDR-2 showed a tendency of their condition to be stable.

Patients from TDR-3 group had a tendency of dementia increase and cognitive functions decline.

CT and MRI showed no dynamics in all Control Group patients.

SG and REG demonstrated weak positive dynamics of blood flow and pulse blood flow in the cerebral hemispheres in all 45 (100%) Control Group patients.

Long-term period (1-5 years) after conservative treatment.

Patients with preclinical AD stage (TDR-0): Clinically, for all 2 years after the start of the treatment, all 6 (100%) patients experienced memory improvement and cognitive functions stabilization of up to 27-29 MMSE points. In the more distant period, 3 (50.00%) patients had no signs of dementia; 3 (50.00%) patients featured appearance of initial signs of dementia accompanied by a decrease in cognitive functions to 24-25 points (**Table 1**).

CT and MRI showed that 1 (16.67%) patient had no signs of tissue volume decrease in the temporal lobes. 3 (50.00%) patients had a tendency to an increase in involutive changes of temporal lobes accompanied by decreasing tissue volume. 2 (33.33%) patients showed a progressive decrease in temporal lobes tissue volume of up to 14-18% (**Figure 11,12**). Consequently, according to the criteria listed above, 3 (50.00%) patients were transferred to TDR-1 group and 3 (50.00%) patients remained in TDR-0 group (**Table 1**).

SG and REG demonstrated that all 6 (100%) patients had positive dynamics of blood flow and pulse blood flow in the hemispheres of the brain.

Patients with early AD stage (TDR-1): Clinically, during 2-3 years after the start of conservative treatment, all 13 (100%) patients showed stabilization of dementia and cognitive functions. In the period of more than 3 years, all 13 (100%) patients showed an increase in dementia signs. In 2 (15.38%) cases, cognitive functions decreased to 20-21 MMSE points, in 11 (84.62%) cases - to 18-19 MMSE points.

When CT and MRI were performed 2-3 years after the onset of conservative treatment, all 13 (100%) patients showed an increase in cerebral involutive changes accompanied by a decrease in temporal lobes tissue weight of up to 12-24%. Therefore, according to the criteria listed above, 11 (84.62%) patients were transferred to TDR-2 group and 2 (15.38%) patients remained in TDR-1 group (**Table 1**).

SG and REG revealed that all 13 (100%) patients had weak positive dynamics of blood flow and pulse blood flow rate.

Patients with middle AD stage (TDR-2): Clinically, dementia increased and cognitive functions decreased to 11-12 points in all 15 (100%) cases in the period of more than a year after the onset of conservative treatment. In the more distant period,

there was a further increase in dementia and a decrease in cognitive functions of up to 9-11 MMSE points.

CT and MRI detected that all 15 (100%) patients showed an increase in cerebral involutive changes with a decrease in the volume of temporal lobes to 33-40% in the period of more than 1.5-2 years after the initiation of the treatment.

Hence, according to the criteria listed above, all 15 (100%) patients, were transferred to TDR-3 group (**Table 1**).

When SG and REG were performed, 9 (60.00%) patients revealed deterioration in the velocity rates of cerebral blood flow and pulse blood filling and 6 (40.00%) patients had no changes in the indices.

Patients with severe AD stage (TDR-3): Clinically, dementia increased and cognitive functions decreased to 7-8 MMSE points in all 11 (100%) cases a year after the start of conservative treatment.

With CT and MRI, all 11 patients showed an increase in cerebral involutive changes with an increase in the atrophy of temporal lobes to 40-55% (**Table 1**).

When SG and REG were performed, there was a slight improvement in the rates of cerebral blood flow and pulse blood filling in 3 (27.27%) cases, and there was no pronounced dynamics of the indices in 8 (72.73%) cases.

Discussion

CSVD is an important factor in the development of AD. Vascular, microvascular and venous changes have a pronounced specificity and are manifested as dyscirculatory angiopathy of Alzheimer's type (DAAT) [4,19,26].

The symptoms of DAAT can be observed not only in patients with clinical AD stages (TDR-1, TDR-2, TDR-3), but also in people with preclinical AD stage (TDR-0), as well as in descendants of patients with AD. That fact points to the obvious primacy of the development of these changes in the etiology of the disease [8].

When working out new methods for treating AD, it is necessary to take into account that microcirculatory and hemodynamic changes cause hypoxia, disrupt the exchange of amyloid beta and lead to its progressive deposition in cerebral tissues and the vascular wall [5,7,8,11]. This process is accompanied by the development of cerebrovascular dysfunction and violates the Neurovascular Unit (NVU) [5,6,7,8]. In the cerebral tissue, metabolic processes are disrupted and hypometabolism develops [6,20,35]. There is a loss of synapses, degeneration and death of neurons in the cells of the Golgi apparatus and the smooth endoplasmic reticulum, mitochondria collapse and general neurodegeneration develops [9,12,17-20,22].

The more these disorders are pronounced and the more actively amyloid removal is reduced and its accumulation increases, the more rapidly AD develops [5,24].

When conservative methods for AD treatment were being worked out, the importance of vascular, microvascular disorders in the etiology and pathogenesis of the disease was not taken into account. These methods are aimed at improving metabolic processes in the cerebral tissue, at stimulating the transmission of nerve impulses and at inhibiting the formation of amyloid beta. These methods are not effective enough and do not always give the desired therapeutic effect [41,42].

In control group patients under the treatment, a temporary positive effect was obtained only in those with early stages of the disease. The effect was manifested in stabilizing the condition but not in improving it.

Low laser energy, when exposed to various biological tissues and the brain, has a different direction of action [12,27-33,43,46-48]. The mechanism of action of low-energy lasers in the red region of the spectrum, with transcatheter intracerebral application, consists in pronounced stimulation of the process of physiological angiogenesis, which causes collateral and capillary revascularization [8,19,34,43]. Recovery of cerebral microcirculation improves tissue nutrition, reduces hypoxia, stimulates metabolism in cells, and in turn helps to restore the process of excreting amyloid beta and recovering its metabolism in tissues [12,39,40].

In intracerebral application, laser energy penetrates 2-3 cm into tissues, affects the mitochondrial apparatus in cells, restores their energy resource, and thus directly stimulates metabolic, reparative and neuroprotective processes [12,34].

In the test group, a long-term positive effect was obtained in all cases after the treatment. It was manifested by a decrease in the level of dementia, improvement or recovery of cognitive functions, and a decrease in cerebral involutive changes.

Patients with preclinical AD stage TDR-0 were transferred into the category of practically healthy people. Patients with clinical stages of the disease (TDR-1, TDR-2, TDR-3) and more severe mental disorders were transferred to groups with an earlier stage of the disease.

Patients from TDR-0 and TDR-1 groups with early stages of the disease demonstrated the obtained effect throughout the observation period of 10 years.

In patients from groups TDR-2 and TDR-3, with later stages of the disease and more severe involutive changes in cerebral tissue, a pronounced positive effect was noted for 2.5-4 years. In the subsequent period, there was a decrease in cognitive functions. The difference in the results obtained in test group patients occurs because patients with advanced AD stages have irreversible changes in their cellular and tissue structures associated with both microcirculation disorders and marked deposition of amyloid beta. As a result, the restoration of blood supply allows restoring metabolism and improving the patient's condition for a certain period.

Conclusion

Transcatheter intracerebral application of low-energy lasers in the red region of the spectrum is a pathogenetically grounded and effective method of treating CSVD in AD. Due to stimulation of angiogenesis, the method produces cerebral revascularization restoring collateral and capillary blood supply, improves cellular and tissue metabolism, stimulates the excretion of amyloid beta from the cerebral tissue and vascular wall, and promotes development of reparative processes.

The application of the method allows reducing the level of dementia and improving cognitive and mental functions. It can be concluded that the use of the intracerebral method for treating people with preclinical stage of AD TDR-0, as well as with the early clinical stage of TDR-1, will prevent the onset or further progression of the disease. The use of the method in patients with advanced AD stages TDR-2 and TDR-3 allows re-

ducing the level of dementia and cognitive disorders for a long time, as well as making it possible for these patients to lead a more active and fulfilling life.

References

1. Waldemar G, Dubois B, Emre M. Recommendations for the diagnosis and management of Alzheimer's disease and other disorders associated with dementia: EFNS guideline. *European Journal of Neurology* 2007; 14: 1-26.
2. Burton EJ, Barber R, Mukaetova-Ladinska EB. Medial temporal lobe atrophy on MRI differentiates Alzheimer's disease from dementia with Lewy bodies and vascular cognitive impairment: a prospective study with pathological verification of diagnosis. *Brain* 2009; 132: 195-203.
3. Weiner WW, Veitch DP, Aisen PS. 2014 Update of the Alzheimer's Disease Neuroimaging Initiative: A review of papers published since its inception. *Journal of Alzheimer's & Dementia*. 2015; 11: e1-e120
4. Maksimovich IV. Radiodiagnostics of Alzheimer's disease. *Diagnostics and Intervention Radiology* 2008; 4: 27-38.
5. Zlokovic BV. Neurodegeneration and the neurovascular unit. *Nat Med*. 2010; 16: 1370-1371.
6. Iadecola C. The overlap between neurodegenerative and vascular factors in the pathogenesis of dementia. *Acta Neuropathol*. 2010; 120: 287-396.
7. Zlokovic BV. Neurovascular pathways to neurodegeneration in Alzheimer's disease and other disorders. *Nature Reviews. Neuroscience*. 2011; 3: 723-738.
8. Maksimovich IV. Certain new aspects of etiology and pathogenesis of Alzheimer's disease. *Advances in Alzheimer's Disease*. 2012; 1: 68-76.
9. Baloianis SJ and Baloianis IS. The vascular factor in Alzheimer's disease: A study in Golgi technique and electron microscopy. *Journal of the Neurological Sciences*. 2012; 322: 117-121.
10. Grammas P, Martinez J, Sanchez A. A new paradigm for the treatment of Alzheimer's disease: targeting vascular activation. *J Alzheimers Dis*. 2014; 40: 619-630.
11. Kimbrough IF, Robel S, Roberson ED, Sontheimer H. Vascular amyloidosis impairs the gliovascular unit in a mouse model of Alzheimer's disease. *Brain*. 2015; 138: 3716-3733.
12. De la Torre JC. Cerebral Perfusion Enhancing Interventions: A New Strategy for the Prevention of Alzheimer Dementia. *Brain Pathology*. 2016; 26: 618-631.
13. Baloyannis SJ. Brain capillaries in Alzheimer's disease. *Hell J Nucl Med*. 2015; 18: 152.
14. Pantoni L. Cerebral small vessel disease: from pathogenesis and clinical characteristics to therapeutic challenges. *Lancet Neurol*. 2010; 9: 689-701.
15. Cai Z, Wang C, He W. Cerebral small vessel disease and Alzheimer's disease. *Clin Interv Aging*. 2015; 23: 1695-1704.
16. Morel F. An apparently dyschoric and topical angiopathy. *Monatsschr Psychiat Neurol*. 1950; 120: 352-357.

17. De la Torre JC. Hemodynamic consequences of deformed microvessels in the brain in Alzheimer's disease. *Annals of New York Academy Sciences*. 1997; 26: 75-91.
18. Kalaria R. Small vessel disease and Alzheimer's dementia: Pathological considerations. *Cerebrovascular Diseases*. 2002; 13: 48-52.
19. Maksimovich. Dyscirculatory Angiopathy of Alzheimer's Type. *Journal of Behavioral and Brain Science*. 2011; 1: 57-68.
20. Brown WR, Thore CR. Review: cerebral microvascular pathology in ageing and neurodegeneration. *Neuropathol Appl Neurobiol*. 2011; 37: 56-74.
21. Maksimovich IV. Dementia and Cognitive Impairment Reduction after Laser Transcatheter Treatment of Alzheimer's Disease. *World Journal of Neuroscience* 2015; 5: 189-203.
22. Deviatkov ND. Application of electronics in medicine and biology. *Electronic Equipment: Microwave Equipment*. 1993; 1: 66-76.
23. Love S, Miners JS. Cerebral Hypoperfusion and the Energy Deficit in Alzheimer's Disease Brain Pathology 2016; 26: 607-617.
24. Bell RD, Zlokovic BV. Neurovascular mechanisms and blood-brain barrier disorder in Alzheimer's disease. *Acta Neuropathologica* 2009; 118: 103-113.
25. Montagne A, Barnes SR, Sweeney MD. Blood-brain barrier breakdown in the aging human hippocampus. *Neuron*. 2015; 85: 296-302.
26. Maksimovich IV. Vascular factors in Alzheimer's disease. *Health*. 2012; 4: 735-742.
27. Nelson AR, Sweeney MD, Sagare AP, Zlokovic BV. Neurovascular dysfunction and neurodegeneration in dementia and Alzheimer's disease. *Biochim Biophys Acta*. 2016; 1862: 887-900.
28. Yang X, Askarova S, Sheng W. Low energy laser light suppresses amyloid- β peptide-induced oxidative and inflammatory responses in astrocytes. *Neuroscience*. 2010; 171: 859-868.
29. Naeser MA, Hamblin MR. Potential for transcranial laser or LED therapy to treat stroke, traumatic brain injury, and neurodegenerative disease. *Photomed Laser Surg*. 2011; 29: 443-446.
30. Song S, Zhou F, Chen WR. Low-level laser therapy regulates microglial function through Src-mediated signaling pathways: implications for neurodegenerative diseases. *J Neuroinflammation*. 2012; 18: 219.
31. Rojas JC, Bruchey AK, Gonzalez-Lima F. Low-level light therapy improves cortical metabolic capacity and memory retention. *J Alzheimers Dis*. 2012; 32: 741-752.
32. onstantinović LM, Jelić MB, Jeremić A. Transcranial application of near-infrared low-level laser can modulate cortical excitability. *Lasers Surg Med*. 2013; 45: 648-653.
33. Purushothuman S, Johnstone DM, Nandasena C. Photobiomodulation with near infrared light mitigates Alzheimer's disease-related pathology in cerebral cortex - evidence from two transgenic mouse models. *Alzheimers Res Ther*. 2014; 3: 2.
34. Maksimovich IV. Transluminal Laser Angioplasty in the Treatment of Ischemic Brain Lesions. dissertation, Russian University of Friendship of the People, Moscow. 2004.
35. Morris JC. The Clinical Dementia Rating (CDR): Current Version and Scoring Rules. *Neurology*. 1993; 11: 2412-2414.
36. Folstein MF, Folstein SE, McHugh PR. (1975) "Mini-mental state". A practical method for grading the cognitive state of patients for the clinician. *J Psychiatr. Res*. 1975; 12: 189-198.
37. Maksimovich IV. The tomography dementia rating scale (TDR) - The rating scale of Alzheimer's disease stages. *Health*. 2012; 4: 712-719.
38. De Lin M and Jackson EF. Applications of Imaging Technology in Radiation Research. *Radiat Res*. 2012; 177: 387-397.
39. Maksimovich IV. Method for Endovascular Treatment of Alzheimer's Disease. 2006.
40. Maksimovich IV. Method and Device for Endovascular Treatment of Alzheimer's Disease. 2008.
41. Matsunaga S, Kishi T, Iwata N. Combination therapy with cholinesterase inhibitors and memantine for Alzheimer's disease: a systematic review and meta-analysis. *Int J Neuropsychopharmacol*. 2014; 28: 115.
42. Grossberg GT, Farlow MR, Meng X, Velting DM. Evaluating high-dose rivastigmine patch in severe Alzheimer's disease: analyses with concomitant memantine usage as a factor. *Curr Alzheimer Res*. 2015; 12: 53-60.
43. Moskvina SV. System analysis of efficiency in controlling biological systems with low-energy laser radiation. 2008.
44. Iadecola C. Neurovascular regulation in the normal brain and in Alzheimer's disease. *Nat Rev Neurosci*. 2004; 5: 347-360.
45. Henry-Feugeas MC. Alzheimer's disease in late-life dementia: a minor toxic consequence of devastating cerebrovascular dysfunction. *Med Hypotheses*. 2008; 70: 866-875.
46. Maksimovich IV. Disorders of cerebrovascular angioarchitectonics and microcirculation in the etiology and pathogenesis of Alzheimer's disease *Advances in Alzheimer's Disease*. 2013; 2: 171-181.
47. Chizhov GK, Kovalskaia NI and Kozlov VI. The effect of helium-neon laser radiation on the energy metabolic indices of the myocardium. *Bulletin of Experimental Biology and Medicine*. 1991; 111: 302-305.
48. Kozlov VI and Azizov GA. Pathophysiological characteristics of microcirculatory disorders in chronic arterial ischaemia of lower limbs. *Angiology and Vascular Surgery*. 2007; 13: 17-23.