



# Ovarian Torsion among a Pregnant Woman: An Uncommon Case Report

Hanaa Lazhar<sup>2</sup>; Aziz Slaoui<sup>1,2\*</sup>; Noha Amail<sup>2</sup>; Najia Zerai<sup>2</sup>; Amina Lakhdar<sup>2</sup>; Aziz Baydada<sup>2</sup>; Aicha Kharbach<sup>1</sup>

<sup>1</sup>Gynaecology-Obstetrics and Endoscopy Department, Maternity Souissi, University Hospital Center IBN SINA, University Mohammed V, Rabat, Morocco.

<sup>2</sup>Gynaecology-Obstetrics and Endocrinology Department, Maternity Souissi, University Hospital Center IBN SINA, University Mohammed V, Rabat, Morocco.

## \*Corresponding Author(s): Aziz Slaoui

University Hospital Center IBN SINA of Rabat,  
Gynaecology-Obstetrics and Endocrinology Department,  
Mohammed V of Rabat, Morocco.  
Email: azizslaoui27@gmail.com

## Abstract

**Background:** Adnexal torsion during pregnancy is a very unusual emergency. It is a surgical emergency, the clinical diagnosis of which remains difficult due to the non-specificity of the clinical picture. Conservative treatment for ovarian torsion is discussed outside the emergency phase; however, the occurrence of acute complications such as ovarian torsion requires more or less invasive surgical procedures. Some authors advocate preservation of the ovary despite its necrotic appearance because its function is preserved in 88 to 100% of cases.

**Case presentation:** We hereby present the case of a 31 years old female, gravida 3 para 3 that presented to our department complaining of a right lower quadrant abdominal pain. She denied any vaginal bleeding or discharge. A urinary pregnancy test was performed firsthand and turned out positive. Ultrasound showed a single live intrauterine pregnancy estimated at 5 weeks based off of the crown-rump length. It demonstrates also a large right intra-ovary cyst measuring 9cmx10cm. The patient was immediately admitted to the OR. She had an exploratory laparotomy which revealed a massive right cyst with an enlarged ovary twisted three times around her pedicle. It was manually detorsed and an ovariopexy was performed. The patient was discharged after 5 days. At 38 weeks, the patient had a vaginal delivery giving birth to a healthy boy.

**Conclusions:** Ovarian torsion is an uncommon urgent gynecological surgery and can occur during pregnancy. The clinical holds a preponderant place in establishing the diagnosis. It should be suspected in every female patient presenting with acute pelvic pain, nausea and vomiting whose physical exam reveal a palpable adnexal mass. Ultrasonographic imaging should be the first line investigation tool.

Received: Nov 04, 2022

Accepted: Nov 28, 2022

Published Online: Nov 30, 2022

Journal: Annals of Reproductive Medicine

Publisher: MedDocs Publishers LLC

Online edition: <http://meddocsonline.org/>

Copyright: © Slaoui A (2022). *This Article is distributed under the terms of Creative Commons Attribution 4.0 International License*

**Keywords:** Pregnancy; Ovarian torsion; Obstetrics emergencies.

**Cite this article:** Lazhar H, Slaoui A, Amail N, Zerai N, Lakhdar A, et al. Ovarian Torsion among a Pregnant Woman: An Uncommon Case Report. *Ann Reprod Med.* 2022; 1(1): 1002.



However, the presence of blood flow should not exclude the diagnosis. Surgical detorsion of the ovarian mass is an urgent requisite. Pregnancy should not delay the admission to the OR. Every delay risk compromising maternal morbidity and fetal mortality. Fetal loss is a low risk in the first trimester thanks to advances in anesthesiology. This article aims to outline proper diagnosis and management of ovarian torsion in pregnancy.

### Background

Adnexal torsion during pregnancy is a very unusual emergency. Its incidence varies from 3 to 5 per 10,000 pregnancies secondary to total or partial rotation of the ovary around its vascular axis [1,2]. It may be favored by the existence of an adnexal mass or ovarian hyper stimulation which sometimes leads to the formation of ovarian cysts [3]. It is a surgical emergency, the clinical diagnosis of which remains difficult due to the non-specificity of the clinical picture [4,5]. Conservative treatment for ovarian torsion is discussed outside the emergency phase; however, the occurrence of acute complications such as ovarian torsion requires more or less invasive surgical procedures [6]. Some authors advocate preservation of the ovary despite its necrotic appearance because its function is preserved in 88 to 100% of cases [7]. Despite the ovary's great capacity for recovery, conservative surgery is only conceivable in cases seen and treated early, which is very rarely the case in resource-poor countries [8]. We report here the case of a torsion of an ovarian cyst in a pregnant woman with a 5-week amenorrhea pregnancy.

### Case presentation

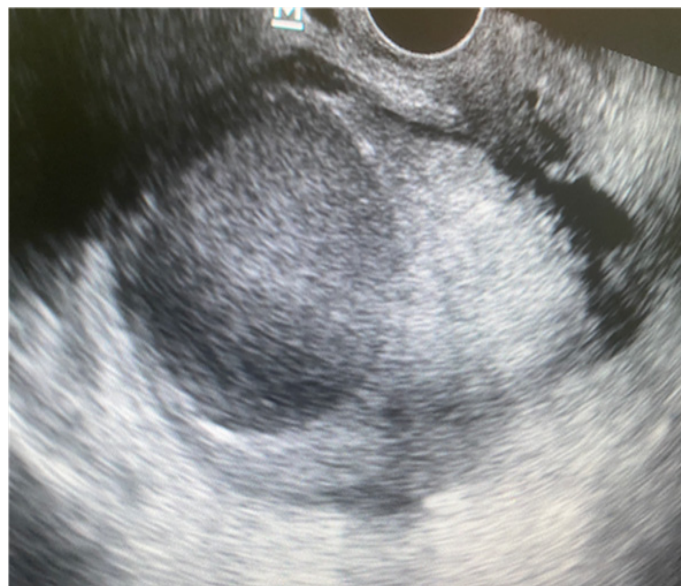We hereby present the case of a 31 years old female, gravida 3 para 3 that presented to our department complaining of a right lower quadrant abdominal pain. According to the patient, the pain had started at 4 am the night before and was described as constant pinching associated with nausea and vomiting. She denied any vaginal bleeding or discharge. History revealed 3 former vaginal deliveries besides irregular menses for the last year. She had not menstruated for two months.

Physical exam showed a stable patient with no acute distress. Her abdomen was slightly tender with normal bowel sounds. Gynecological examination revealed a right latero-uterine mass with an enlarged uterus. There was no vaginal discharge nor bleeding. Nevertheless, the cervix appeared purplish. A urinary pregnancy test was performed firsthand and turned out positive.

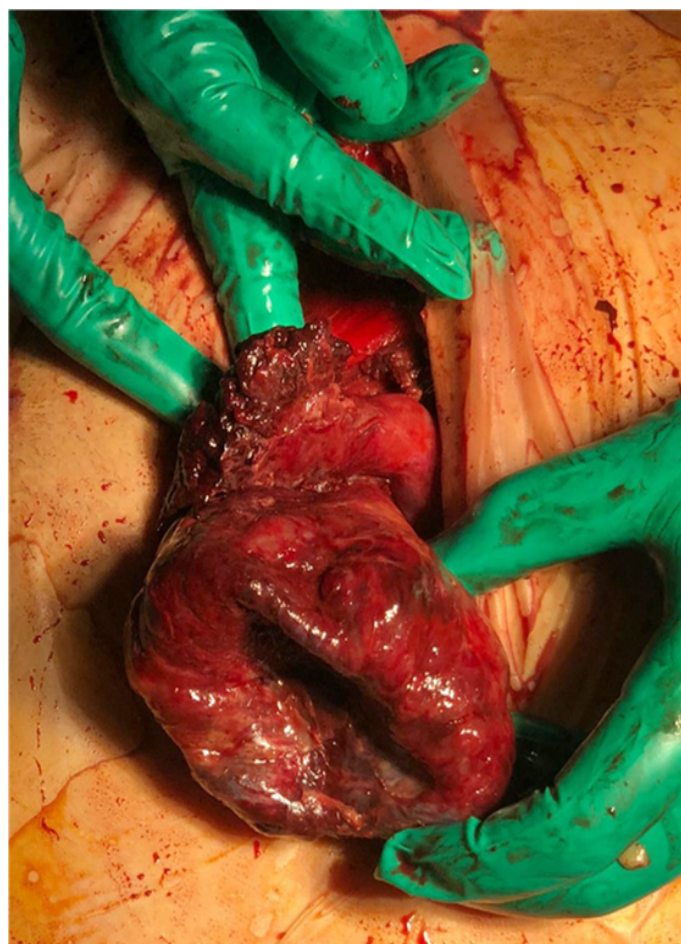
The immediate ultrasound showed a single live intrauterine pregnancy estimated at 5 weeks based off of the crown-rump length. Besides the pregnancy, it demonstrates a large right intra-ovary cyst measuring 9cmx10cm (**Figure 1**) whereas the left ovary appeared to be normal. A mild ascites was noted. Using color Doppler, blood flow was not demonstrated in the right ovary opposed to the left one where blood flow was adequate. Her blood investigations manifest hemoglobin (Hb): 10,5 g/dl ; total leucocyte count (TLC): 17800/cm<sup>3</sup> and platelet: 318000/mm<sup>3</sup>. Basic metabolic panel, renal and liver functions were within normal range.

The patient was immediately admitted to the OR. She had an exploratory laparotomy using a Pfannenstiel incision. It revealed a massive right cyst with an enlarged and podgy infundibulum tubae uterinae. The utero-ovarian ligament was lon-

ger than usual and the enlarged ovary was twisted three times around her pedicle (**Figures 2&3**). Using a syringe, a sample was drained from the chocolate-like content of the cyst. The right ovary was manually detorsed and an ovariopexy was performed. The patient was discharged after 5 days. She was immediately started on intravaginal progesterone (200 mg per day) for the two following months. At 38 weeks and 4 days, the patient had a vaginal delivery giving birth to a healthy boy weighing 3,2 kg.

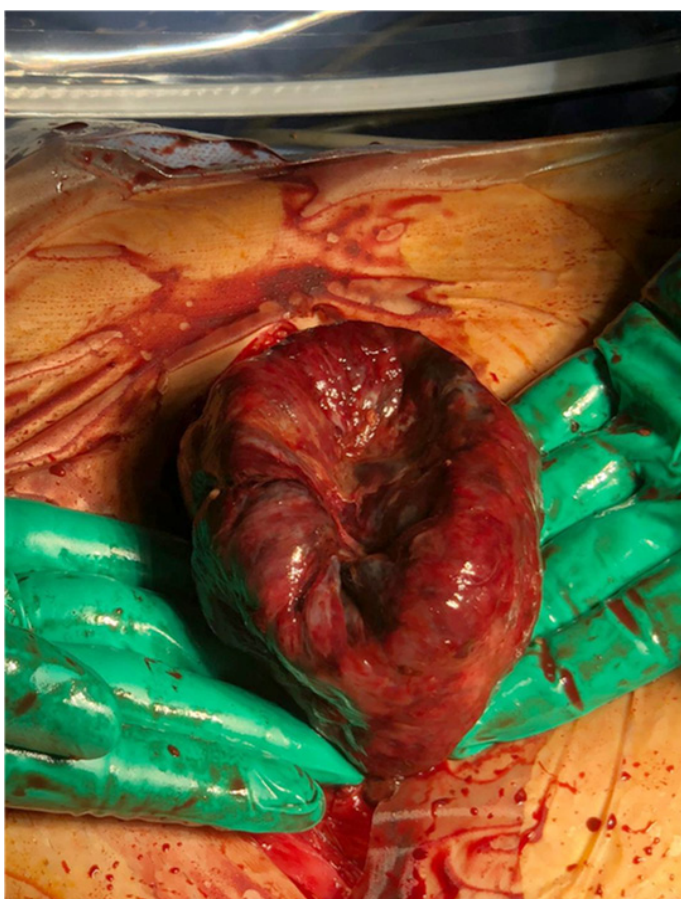


**Figure 1:** Ultrasound image of a 9 x 10 cm ovarian cyst with homogeneous content resembling an endometrioma with a ground glass appearance.



**Figure 2:** Intraoperative photograph of the ovarian cyst with two obvious turns of the ovary.





**Figure 3:** Intraoperative photograph showing the progressive recoloring of the ovary after detorsion.

### Discussion

Ovarian torsion is the total or partial rotation of the adnexa around its vascular axis [9]. The imbalance between the continuous arterial inflow without venous outflow causes a potentially massive enlargement of the ovary. Undiagnosed ergo untreated, it leads to hemorrhagic infarction and necrosis of the ovarian stroma [10].

OT among pregnant women is an uncommon complication with a high materno-fetal morbi-mortality. Its incidence during pregnancy is approximately 5 per 10000 spontaneous pregnancies [11]. It's the fifth most common gynecological surgical emergency with a prevalence of 2,7 to 3% [12]. It occurs when the ovary is enlarged secondary to cysts or neoplasms. During pregnancy, it's caused by the presence of the corpus luteum that vanishes spontaneously by the second trimester. Hence, ovarian torsion is a first trimester complication as it's the case of our patient. It seldom happens in the second trimester and exceptionally in the third trimester [13-14]. Like our patient, OT occurs more commonly on the right side because the sigmoid colon limits the mobility of the left ovary [15]. The risk factors of ovarian torsion in our case were pregnancy and the presence of an ovarian cyst.

The diagnosis is very challenging with variable and nonspecific symptoms. The most frequent symptom is onset of intense unilateral pelvic pain starting suddenly at night and persisting for more than 24 hours [16-17]. The second frequent symptom is a palpable adnexal mass. Our patient presented the same pain features and her physical exam revealed a 10cm adnexal mass. Pelvic pain associated to nausea and vomiting and pyrexia must raise the question of an ongoing ovarian torsion [18].

Ultrasound is the imaging examination of choice in the diagnosis of ovarian torsion [19]. As it's advised, when the US is performed in the first and second trimester of pregnancy, it should not only focus on fetal parameters but also evaluate the adnexae so as to avoid any complication related to ovarian cysts [20]. Unfortunately, in the third trimester, the ovaries are sometimes hard to visualize ultrasonographically delaying the diagnosis and resulting in increased feto-maternal morbidity [21]. They are usually displaced by the enlarging uterus. However, in this case, Magnetic Resonance Imaging (MRI) can be used.

The ultrasonic features characterizing ovarian torsion are unilateral ovarian enlargement (>4cm) with or without an ovarian mass; ovarian edema with presence of hyperechogenic ovary and peripherally displaced follicles with echogenic stroma; free fluid in the Douglas pouch; the absence or decreased blood flow in the ovary using Doppler effect; and the presence of coiled and twisted or circular vessels (whirlpool sign) [22-23]. The presence of flow at color Doppler imaging does not exclude the diagnosis of ovarian torsion but instead suggests that the ovary may be viable. Some authors recommended not to lean solely on the results of Doppler flow investigation to determine whether a surgical evaluation is needed [24]. The decision should rather be based off the patient's medical history, clinical appearance and laboratory assessment [25]. The ultrasound performed right after her admission showed results matching the literature.

Expedient surgery is a requisite treatment for ovarian torsion. The sooner the better. Weighing the risk of fetal loss in the first trimester or premature labor during the second and third trimester should not delay surgical decision. Although conservative treatment has been proposed during pregnancy, surgery is the treatment of choice once ovarian torsion is suspected [26].

Laparoscopic de-rotation of adnexal torsion is the recommended first line treatment [27]. Reestablishing ovarian circulation by untwisting the ovarian pedicle results in viable ovarian tissue on the affected side with no systemic complications [28]. Even if the adnexa initially appear purplish or black and nonviable, conservative approach is preferred in order to preserve fertility [29]. As ovarian torsion may recur after detorsion, unilateral or bilateral oophoropexy or ovariopepy following detorsion may be performed to prevent recurrence [30-32]. In our case, the utero ovarian ligament was abnormally long therefore an ovariopepy was performed successfully. Commonly, the cysts responsible for the torsion are excised or drained so as to avoid an ulterior torsion. Given that the typical cyst in the first trimester is a corpus luteal cyst whose responsible for supporting the pregnancy until the placenta is fully developed, the excision or drainage may result in pregnancy loss. Consequently, it's common practice to prescribe progesterone, as we did in post-operative care, to help sustain and support the pregnancy.

### Conclusions

Ovarian torsion is an uncommon urgent gynecological surgery and can occur during pregnancy. The clinical holds a preponderant place in establishing the diagnosis. It should be suspected in every female patient presenting with acute pelvic pain, nausea and vomiting whose physical exam reveal a palpable adnexal mass. Ultrasonographic imaging should be the first line investigation tool. However, the presence of blood flow should not exclude the diagnosis. Surgical detorsion of the ovarian mass is an urgent requisite. Pregnancy should not delay the admission to the OR. Every delay risk compromising maternal

morbidity and fetal mortality.

Fetal loss is a low risk in the first trimester thanks to advances in anesthesiology. This article aims to outline proper diagnosis and management of ovarian torsion in pregnancy.

This work has been reported in line with the SCARE 2020 criteria [33].

## References

- Zanetta G, Mariani E, Lissoni A, Ceruti P, Trio D, et al. A prospective study of the role of ultrasound in the management of adnexal masses in pregnancy. *BJOG Int J Obstet Gynaecol.* 2003; 110: 578-583.
- Kumari I, Kaur S, Mohan H, Huria A. Adnexal masses in pregnancy: a 5-year review. *Aust N Z J Obstet Gynaecol.* 2006; 46: 52-54.
- Rackow BW, Patrizio P. Successful pregnancy complicated by early and late adnexal torsion after in vitro fertilization. *Fertil Steril.* 2007; 87: 697-e9.
- Kao J-K, Chiu C-C, Wang P-Y, Yu M-K. Pediatric ovarian torsion in a medical center in Taiwan: case analysis. *Pediatr Neonatol.* 2012; 53: 55-59.
- Kitporntheranunt M, Wong J, Siow A. Entangled bilateral adnexal torsion in a premenarchal girl: a laparoscopic approach. *Singapore Med J.* 2011; 52: e124-e127
- Schmeler KM, Mayo-Smith WW, Peipert JF, Weitzen S, Manuel MD, Gordinier ME. Adnexal masses in pregnancy: surgery compared with observation. *Obstet Gynecol.* 2005; 105: 1098-1103.
- Oelsner G, Shashar D. Adnexal torsion. *Clin Obstet Gynecol.* 2006; 49: 459-463.
- Toure B, Dao B, Sano D, Akotiongma M, Lankoande J, et al. Adnexal torsion during pregnancy. Diagnostic and therapeutic problems in Burkina Faso. *Rev Med Brux.* 1997; 18: 379.
- Hibbard L. Adnexal torsion. *Am J Obstet Gynecol.* 1985; 152: 456-461.
- Bharathan R, Ramsawak L, Kelly A. Ovarian torsion: opportunities to improve clinical management. *J Obstet Gynaecol* 2012; 32: 683-686.
- Ginath S, Shalev A, Keidar R, Kerner R, Condrea A, et al. Differences between adnexal torsion in pregnant and nonpregnant women. *J Minim Invasive Gynecol.* 2012; 19: 708-714.
- Mashiach R, Melamed N, Gilad N, Ben-Shitrit G, Meizner I. Sonographic diagnosis of ovarian torsion accuracy and predictive factors. *J Ultrasound Med* 2011; 30: 1205-1210.
- Hibbard LT. Adnexal torsion. *Brain Res.* 1985; 152: 456-461.
- Mashiach R, Bar-On S, Boyko V, Stockheim D, Goldenberg M, et al. Sudden/nocturnal onset of acute abdominal pain, lasting less than a day and accompanied by vomiting: a tell-tale sign of ovarian torsion. *Gynecol Surg.* 2010; 297-301.
- Sasaki KJ, Miller CE. Adnexal torsion: review of the literature. *J Minim Invasive Gynecol.* 2014; 21: 196-202.
- Arena S, Canonico S, Luzi G, Epicoco G, Brusco GF, et al. Ovarian torsion in in vitro fertilization-induced twin pregnancy: combination of Doppler ultrasound and laparoscopy in diagnosis and treatment can quickly solve the case. *Fertil Steril.* 2009; 92: 1496.
- Smorgick N, Barel O, Halperin R, Schneider D, Pansky M. Laparoscopic removal of adnexal cysts: is it possible to decrease inadvertent intraoperative rupture rate? *Am J Obstet Gynecol.* 2009; 200: 237.
- Huchon C, Fauconnier A. Adnexal torsion: a literature review. *Eur J Obstet Gynecol Reprod Biol.* 2010; 150: 8-12.
- Kupesic S, Plavsic BM. Adnexal torsion: colour doppler and three dimensional ultrasound. *Abdominal Imaging.* 2010; 35: 602-606.
- Weiner E, Mizrahi Y, Keidar R, Kerner R, Golan A, et al. "Laparoscopic surgery performed in advanced pregnancy compared to early pregnancy". *Archives of Gynaecology and Obstetrics.* 2015; 292: 1063-1068.
- Smorgick N, Pansky M, Feingold M, Herman A, Halperin R, et al. The clinical characteristics and sonographic findings of maternal ovarian torsion in pregnancy. *Fertility and Sterility.* 2009; 92: 1983-1987.
- Chang HC, Bhatt S, Dogra VS. Pearls and pitfalls in diagnosis of ovarian torsion. *Radiographics* 2008; 28: 1355-1368.
- Valsky DV, Esh-Broder E, Cohen SM, Lipschuetz M, Yagel S. Added value of the gray-scale whirlpool sign in the diagnosis of adnexal torsion. *Ultrasound Obstet Gynecol.* 2010; 36: 630-634.
- Hasson J, Tsafir Z, Azem F, Bar-On S, Almog B, et al. Comparison of adnexal torsion between pregnant and nonpregnant women. *Am J Obstet Gynecol.* 2010; 202: 536.
- Arena S, Canonico S, Luzi G, Epicoco G, Brusco GF, et al. Ovarian torsion in in vitro fertilization induced twin pregnancy: combination of Doppler ultrasound and laparoscopy in diagnosis and treatment can quickly solve the case. *Fertil Steril.* 2009; 92: 1496.
- Krishnan S, Kaun H, Bali J, Rao K. Ovarian torsion in infertility management - missing the diagnosis means losing the ovary: a high price to pay. *Journal of Human Reproductive sciences.* 2011; 4: 39-42.
- Visser BC, Glasgow RE, Mulvihill KK, Mulvihill SJ. Safety and timing of nonobstetric abdominal surgery in pregnancy. *Dig Surg.* 2001; 18: 409-417.
- Pan HS, Huang LW, Lee CY, et al. Ovarian pregnancy torsion. *Hum Reprod.* 2004; 270: 119-121.
- Cohen SB, Oelsner G, Seidman DS, Admon D, Mashiach S, et al. Laparoscopic detorsion allows sparing of the twisted ischemic adnexa. *J Am Assoc Gynecol Laparosc.* 1999; 6: 139-143.
- Pansky M, Smorgick N, Herman A, Schneider D, Halperin R, et al. Torsion of normal adnexa in postmenarchal women and risk of recurrence. *Obstet Gynecol.* 2007; 109: 355.
- Grunewald B, Keating J, Brown S. Asynchronous ovarian torsion-the case for prophylactic oophoropexy. *Postgrad Med J.* 1993; 69: 318.
- Abeş M, Sarihan H. Oophoropexy in children with ovarian torsion. *Eur J Pediatr Surg.* 2004; 14: 168.
- Agha RA, Franchi T, Sohrabi C, Mathew G. The SCARE 2020 guideline: updating consensus Surgical CAse REport (SCARE) guidelines. *Int J Surg.* 2020; 84: 226-230.