



# Waldmann's Disease Revealed by Chronic Diarrhea and Lymphedema: Case Report

**Khadija Mouaddine<sup>1\*</sup>; Mouna Sabib<sup>1</sup>; Laila Benbella<sup>2</sup>; Yasmine Laraqui<sup>2</sup>; Taoufik Meskini<sup>1</sup>; Rouas Lamiaa<sup>2</sup>; Najat Lamalmi<sup>2</sup>; Nezha Mouane<sup>1</sup>**

<sup>1</sup>Pediatric Hepato-Gastroenterology and Nutrition Department, Rabat Children's Hospital, Faculty of Medicine and Pharmacy, Mohammed V University Rabat, Morocco.

<sup>2</sup>Pathology Department of the Rabat Children's Hospital, Rabat Children's Hospital, Faculty of Medicine and Pharmacy, Mohammed V University Rabat, Morocco.

## \*Corresponding Author(s): Khadija Mouaddine

Department of pediatrics, children's hospital of Rabat, Mohammed V University, Riad Loudaya 12020 Temara Morocco.

Tel: +21235306318;

Email: khadijamouaddine7@gmail.com

## Abstract

Intestinal Lymphangiectasia (IL) is a rare disease characterized by the dilation of intestinal lymphatics. It can be classified as primary or secondary depending on the underlying etiology. It usually shows in childhood or adolescence, chronic diarrhea and diffuse edema are the main clinical manifestations of the disease. True lymphoedemas can also be present and affect the lower and upper limbs, they are concomitant with the diagnosis or occur during the course.

The diagnosis is based on the visualization of duodenal lymphangiectasia. The primitive nature of the disease being affirmed by the elimination of the diseases causing secondary lymphangiectasias. Treatment is based on a strict hypo lipid diet enriched with Medium Chain Triglycerides (MCTs).

We present through this work the observation of a 12-month-old infant who presented with primary intestinal lymphangiectasia revealed by chronic diarrhea with lymphedema of the left upper limb.

Received: Jul 26, 2021

Accepted: Aug 19, 2021

Published Online: Aug 23, 2021

Journal: Annals of Pediatrics

Publisher: MedDocs Publishers LLC

Online edition: <http://meddocsonline.org/>

Copyright: © Mouaddine K (2021). *This Article is distributed under the terms of Creative Commons Attribution 4.0 International License*

**Keywords:** Intestinal Lymphangiectasia; Waldmann disease; Lymphedema.

## Introduction

Intestinal Lymphangiectasia (IL) is a rare and benign disease characterized by focal or diffuse dilation of mucous, submucosal and subserosal lymphatics [1]. In addition to being an important cause of protein loss [2], it is frequently associated with extra intestinal lymphatic abnormalities [3].

Depending on the underlying pathology, lymphangiectasia can be classified as a primary or secondary disease. The primary form (PIL) probably represents a congenital disorder of the mesenteric lymphatics, while the IL areal form may be secondary to diseases such as constrictive pericarditis, lymphoma, sarcoidosis and scleroderma [4]. The modification of the diet is the mainstay of the management of this pathology with a variable response.



**Cite this article:** Mouaddine K, Sabib M, Benbella L, Laraqui Y, Meskini T, et al. Waldmann's Disease Revealed by Chronic Diarrhea and Lymphedema: Case Report. *Ann Pediatr.* 2021; 4(1): 1077.

The objective of our work is to describe the observation of a female infant who presented with primary intestinal lymphangiectasia revealed by chronic diarrhea with lymphedema of the left upper limb.

### Patient and observation

Our patient is a 12 month old infant, from an out-consanguineous marriage with healthy siblings, and a well-followed pregnancy. The delivery took place vaginally with birth weight = 3400g, placed under exclusive breastfeeding for 02 months then mixed breastfeeding, diversified at the age of 07 months. She has had diarrhea since the age of 6 months at a rate of 6 stools / day. The stools are watery, there is no mucus or blood, there is progressive abdominal distension and lymphedema of the left upper limb.

There are no extra digestive signs, including no respiratory signs and no recurrent infections.

### Clinical results

On physical examination, the infant was found to be hemodynamically and respiratory stable, pale, with a weight of 10kg (M) and a height of 75cm (M). There is no dysmorphism. The abdomen is distended without hepatomegaly or splenomegaly, with the presence of lymphedema of the left hand (Figure 1).

No jaundice, no edema, the urine dipstick is negative.

### On the biological level

There is a hypoproteinemia at 27g / l with hypo albuminemia at 15g / l. Calcemia is 72 mg / l, ferritin is reduced to 8 ng / ml, total cholesterol to 1.37g / l, HDL to 0.27g / l LDL to 0.96 g / l, triglycerides to 0.72 g / l. The liver function tests are normal with ASAT at 47 U / L, ALAT at 18 U / L, GGT at 4 U / L and PAL=173 .TP at 100%. The blood count reveals a hemoglobin level of 11.1 g / dl with VGM at 73.7  $\mu$ m<sup>3</sup> and CCMH at 31.7%, a leukocyte level at 7060 /  $\mu$ l with polymorphonuclear neutrophils at 4780 /  $\mu$ l and lymphocytes at 1140 /  $\mu$ l and eosinophils at 210 /  $\mu$ l with thrombocytosis at 626000 /  $\mu$ l.

The blood ionogram as well as the renal function returned to normal, the anti-transglutaminase antibodies are normal with a level of Ig A=1.25 AU / ml and IgG=0.41 AU / ml.

### Radiologically

The echodoppler of the left upper limb as well as the echocoeur returned to normal, the abdominal ultrasound showed the presence of a thickened and agglutinated aspect of the slender loops (7mm) with a slight intraperitoneal effusion.

From an anatomopathological point of view: the jejunal biopsy showed a jejunal mucosa bristling with villi of normal height and lined by a regular columnar epithelium that is normosecretant. The glands are well differentiated nomosecretantes. The villus axis is congestive edematous with lesions of lymphangiectasia. The chorion harbors an inflammatory lymphoplasmacytic infiltrate mixed with a few neutrophils.

Secondary causes are ruled out before normal echocardiography, absence of lymphatic obstruction on abdominal ultrasound, normal fecal calprotectin, and negative ASCA and ANCA. The karyotype is normal eliminating Turner syndrome.

The diagnosis of Waldmann's disease was retained in our patient, she received albumin infusions and then put on a high protein diet, poor in long chain fatty acids, enriched in medium

chain fatty acids with supplementation of fat soluble vitamins and hell.

The course was marked by the stabilization of his clinical condition.

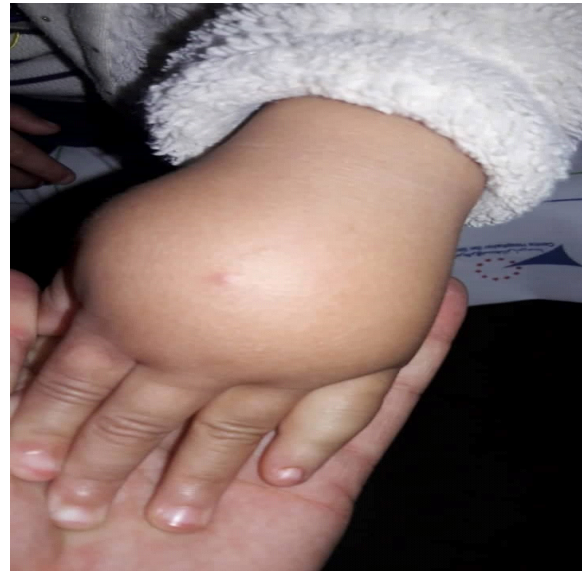

Figure 1: Aspect of lymphedema of the left hand.

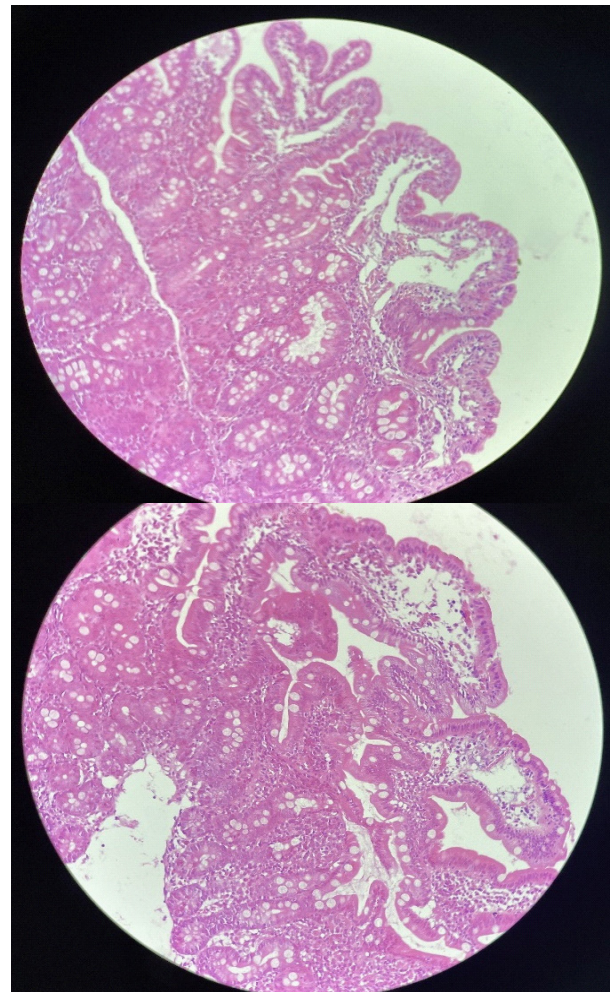


Figure 2: Anatomopathological aspect of intestinal lymphangiectasias.

---

**References**

1. Isa HM, Al-Arayedh GG, Mohamed AM. Intestinal lymphangiectasia in children: A favorable response to dietary modifications. *Saudi medical journal*. 2016; 37: 199.
2. Troskot R, Jurčić D, Bilić A, Palčić MG, Težak S, Brajković I. How to treat an extensive form of primary intestinal lymphangiectasia?. *World Journal of Gastroenterology: WJG*. 2015; 21: 7320.
3. Suresh N, Ganesh R, Sankar J, Sathiyasekaran M. Primary intestinal lymphangiectasia. *Indian Pediatr* 2009 ; 46 : 903-906.
4. Lai Y, Yu T, Qiao XY, Zhao LN, Chen QK. Primary intestinal lymphangiectasia diagnosed by double-balloon enteroscopy and treated by medium-chain triglycerides: A case report. *J Med Case Rep* 2013; 7: 19.
5. Vignes S, Bellanger J. Primary intestinal lymphangiectasia (Waldmann's disease). *The Journal of Internal Medicine*. 2017; 39: 580-585.
6. Fellow V, Vignes S. Primary intestinal lymphangiectasias (Waldmann's disease) revealed by lymphoedema of the limbs. *Journal of Vascular Diseases*. 2004; 29: 103-106.
7. Le Bougeant P, Delbrel X, Grenouillet M, Leou S, Djossou F. Familial Waldmann disease. In *Annals of internal medicine*. 2000; 151: 511-512.
8. Wen J, Tang Q, Wu J, Wang Y, Cai W. Primary intestinal lymphangiectasia: Four case reports and a review of the literature. *Dig Dis Sci*. 2010; 55: 3466-3472.
9. Daza Carreño W, Mejía Cardona LM, Jaramillo Barberi LE, Uribe MC. A case report of intestinal Lymphangiectasia. *Colombian Journal of Gastroenterology*. 2013; 28: 134-145.
10. Waldmann T, Steinfeld JL, Dutcher TF, Davidson JD, Gordon Jr RS. The role of the gastrointestinal system in "idiopathic hypoproteinemia". *Gastroenterology*. 1961; 41: 197-207.
11. Desrame J, Bechade D, Patte JH, Jean R, Karsenti D, et al. Yellow nail syndrome associated with intestinal lymphangiectasia. *Clinical and biological gastroenterology*. 2000; 24: 837-840.
12. Amiot A. Gastro-entéropathies exsudatives. *Rev Med Interne*. 2015; 36: 467-473.
13. Munck A, Faure C, Besnard M, Ferkdadji L, Cézard JP, et al. Long-term followup of primary intestinal lymphangiectasia in the child. Six case reports. *Pediatric Archives: Official organ of the French Pediatric Society*. 2002; 9: 388-391.
14. Klingenberg RD, Homann N, Ludwig D. Type I intestinal lymphangiectasia treated successfully with slow-release octreotide. *Dig Dis Sci*. 2003 ; 48 : 1506-1509.
15. Kuroiwa G, Takayama T, Sato Y, Takahashi Y, Fujita T, et al. Primary intestinal lymphangiectasia successfully treated with octreotide. *Journal of gastroenterology*. 2001; 36: 129-132.
16. Harris SR, Hugi MR, Olivotto IA, Levine M. Clinical practice guidelines for the care and treatment of breast cancer: 11. Lymphoedema. *Cmaj*. 2001; 164: 191-199.