



# Multidisciplinary Care with Surgery and Palliative Chemotherapy to Improve Quality of Life in a Patient with Trisomy 18 and Wilms Tumor

Samanta Catueno<sup>1</sup>; Utpal Bhalala<sup>1,3</sup>; Stephen Almond<sup>2</sup>; Catherine Boston<sup>1</sup>; Ndina Nhlane<sup>1</sup>; Nkechi Mba<sup>1,3</sup>; Farha Sherani<sup>1,3\*</sup>

<sup>1</sup>Department of Pediatrics, Driscoll Children's Hospital, Corpus Christi, TX, USA.

<sup>2</sup>Department of Surgery, Driscoll Children's Hospital, Corpus Christi, TX, USA.

<sup>3</sup>Department of Pediatrics, Texas A&M University, College Station, TX, USA.

## \*Corresponding Author(s): Farha Sherani

Department of Hematology/Oncology, Driscoll Children's Hospital, Corpus Christi, 3533 S. Alameda St, Corpus Christi, TX 78411, USA.

Tel: 361-694-5000; Email: Farha.sherani@dchstx.org

## Abstract

**Background:** With recent advances in medical care, the overall life expectancy of Trisomy 18 has improved significantly. With this, solid tumor reports have increased, with Wilms tumor as the second most common malignancy described. We present a patient with Trisomy 18, Wilms tumor and Eisenmenger syndrome, requiring multidisciplinary management given her complex medical history.

**Case description:** 2-year-old female with Trisomy 18 and Eisenmenger syndrome with evidence of a horseshoe kidney and an incidentally discovered solid mass in the left-sided kidney. The mass remained stable under surveillance for about 2.5 years. At 4 years of age, she had abdominal pain and an increase in mass size. After multidisciplinary discussions, she underwent left nephrectomy, with no complications. The tumor was classified as Wilms tumor with Stage 1 favorable histology. Chemotherapy was deferred due to parental concern about toxicity. Subsequently, for recurrence of tumor and occurrence of pulmonary metastasis, she received palliative chemotherapy with EE4A. She had good symptom management and maintained pre-surgery quality of life, until terminal disease progression 5 months after recurrence.

**Conclusion:** Medical advances and a multidisciplinary team approach to patients with Trisomy 18 has led to prolonged survival. Routine abdominal ultrasound screening is recommended to detect associated tumors. When detected, a multidisciplinary team approach to management may result in prolonged survival with good quality of life.

Received: Jul 16, 2022

Accepted: Aug 11, 2022

Published Online: Aug 15, 2022

Journal: Annals of Pediatrics

Publisher: MedDocs Publishers LLC

Online edition: <http://meddocsonline.org/>

Copyright: © Sherani F (2022). This Article is distributed under the terms of Creative Commons Attribution 4.0 International License

**Keywords:** Trisomy 18; Wilm's tumor; Surgery; Palliative chemotherapy; Quality of life.

**Cite this article:** Catueno S, Bhalala U, Almond S, Boston C, Nhlane N, et al. Multidisciplinary Care with Surgery and Palliative Chemotherapy to Improve Quality of Life in a Patient with Trisomy 18 and Wilms Tumor. Ann Pediatr. 2022; 5(2): 1100.



## Introduction

Trisomy 18 is a frequent chromosomal disorder with a reported incidence of 1/6000-1/8000 live births [1]. In the natural course of the disease, mortality is 90-95% in the first year of life [2]. With recent advances in medical care, the overall life expectancy of Trisomy 18 has improved significantly [3]. With this, solid tumor reports have increased, with Wilms tumor as the second most common malignancy described [4].

This poses newer challenges and dilemma to healthcare teams for managing co-morbidities in these patients. A multidisciplinary approach is the key to a successful outcome and, in cases of disease progression, to optimal palliative care.

We describe a patient with Trisomy 18 with multiple congenital anomalies including unrepaired congenital heart disease with irreversible Eisenmenger syndrome, a horseshoe kidney, and unilateral Wilms tumor, who was managed by a multidisciplinary team for tumor resection and palliative chemotherapy, which enabled a prolonged survival while maintaining pre-tumor quality of life. Her underlying Trisomy 18 and Eisenmenger syndrome, with significant anesthetic and surgical risk and cardiotoxicity due to chemotherapy, made this a very challenging case.

## Case presentation

A 2-year-old female with Trisomy 18, unrepaired ASD, VSD, PDA and Eisenmenger syndrome was admitted with E. Coli urinary tract infection. Renal ultrasound showed a horseshoe kidney and a solid mass in the left-sided kidney. A CT scan showed a well-circumscribed solid mass in the left kidney measuring 3.1 x 3.0 cm (Figure 1). Renal function was normal, and urine catecholamines were negative. Given her multiple comorbidities, multidisciplinary decision including parental preference, was to monitor tumor growth. She continued ultrasound tumor surveillance with Oncology.

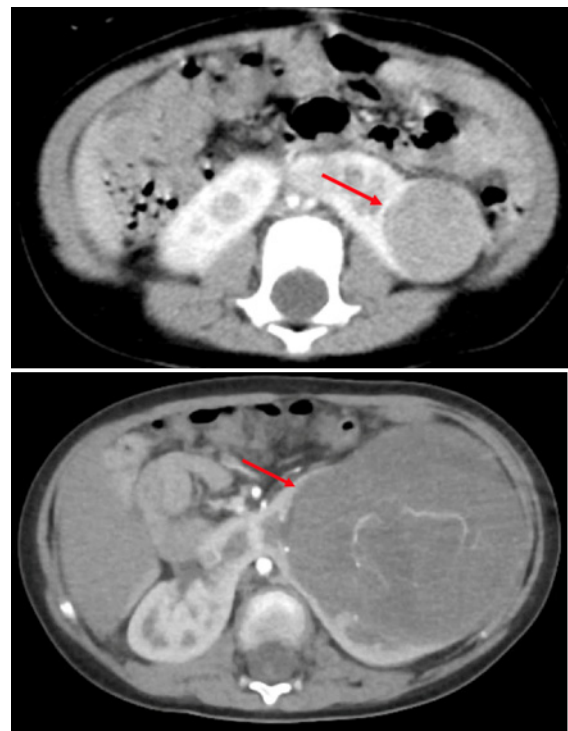
At 4 years of age, 32-months after the initial mass was first imaged, she was admitted with progressive abdominal pain and a decrease in hemoglobin from 14.3 to 9.9 g/dl in 3 months. Abdominal CT angiogram showed an increase in mass size measuring 10.2 x 9.1 x 9.2 cm (previously 6.7 x 5.9 x 5.4 cm), with no intralesional hemorrhage (Figure 1). Parents were now leaning towards intervention due to symptoms. After multidisciplinary discussions with Oncology, Surgery, Cardiology, Pulmonology, Intensivists and Cardiac anesthesiology, she underwent successful left nephrectomy, with no complications and complete resolution of abdominal pain (Figure 3). Pathology showed triphasic Wilms tumor, no anaplasia, extensive perilobar nephrogenic rests with diffuse WT 1 positivity on immunohistochemistry. The tumor was classified as Wilms tumor with Stage 1 favorable histology. Given the co morbidities, potential treatment toxicities and parental input adjuvant chemotherapy and radiation were deferred, in favor of quality of life.

Three months later she was admitted with fever, abdominal pain, tachycardia, and decreased urine output. Echocardiogram showed severe pulmonary hypertension and biventricular dysfunction (LVEF (Teich) (M-Mode): 41.8 %; LV FS (M-Mode): 19.88 %). A chest, abdomen and pelvic CT done to elicit etiology showed 3 large masses in the left side of the abdomen (7.5 x 6.5 x 11.5 cm; 6.5 x 4.8 and 6.0 x 4.9 cm) (Figure 2), with bilateral pulmonary nodules consistent with metastatic Wilms tumor

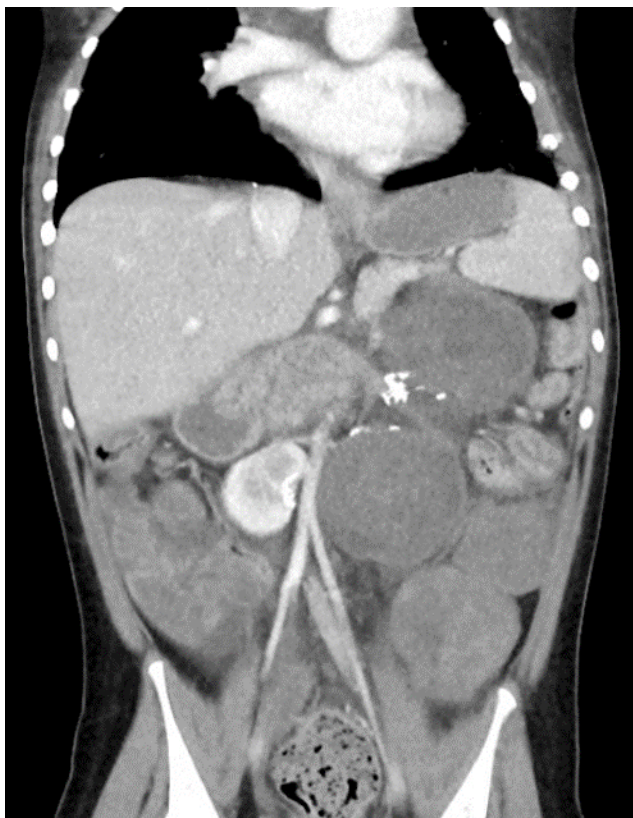After multidisciplinary conference and family meeting, the severe pulmonary hypertension and biventricular dysfunction precludes any potentially curative therapies for recurrent/metastatic Wilms including surgery with radiation and intense multi agent chemotherapy). Palliative chemotherapy was offered, and her parents opted to pursue palliative chemotherapy to improve her symptoms and maintain good quality of life. Decision was to start Regimen EE4A (Vincristine and Dactinomycin) to avoid cardiotoxic regimen. Initiation of chemotherapy was delayed after the patient had respiratory arrest with worsening biventricular dysfunction needing ICU admission and pressors, secondary to E. Coli urosepsis.

Disease evaluation following 6 weeks of EE4A chemotherapy showed significant decrease in mass in renal fossa and pulmonary nodules (60% reduction of the abdominal mass). Due to this response and good tolerability of this regimen, decision was to continue with the same chemotherapy regimen, and explore feasibility of surgery, after Week 12 of treatment [5].

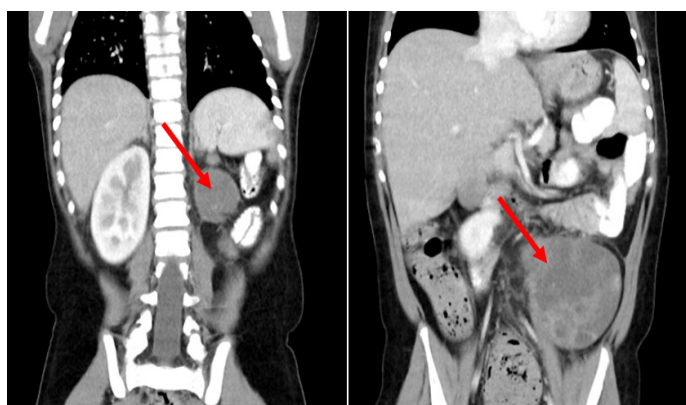
She presented for follow up at 11 weeks of treatment with increase in abdominal mass. CT chest, abdomen and pelvic was obtained which showed a mixed response, with improvement in pulmonary lesions and abdominal mass in renal fossa, but significant enlargement of masses in left iliac fossa (Figure 3). Parents wanted to continue treatment. Surgery followed by vincristine with irinotecan chemotherapy was offered. A week prior to surgery she was admitted with Rhinovirus infection and worsening cardiac function needing Milrinone inotropic support. Surgery was delayed. She had significant progression of the size of her abdominal tumor. Cardiac function worsened precluding surgery and additional chemotherapy. Following multidisciplinary discussions with parental input. Her care goals were focused to comfort and end of life care. Milrinone was weaned off, and the patient was discharged to hospice care, where she died peacefully 5 days later [6].



**Figure 1:** Initial tumor in left kidney at 2 years of age (left) and tumor progression at 4 years of age (right).



**Figure 2:** Wilms tumor relapse, with multiple abdominal masses (red arrows).



**Figure 3:** Mixed response on Week 11, showing decrease size of mass in renal fossa (left), but at the same time, increase size of mass in iliac fossa (right).

### Discussion

To the best of our knowledge, this is the first case report of a patient with Trisomy 18, Wilms tumor and unrepaired congenital heart disease with Eisenmenger syndrome, undergoing surgery and palliative chemotherapy treatment, resulting in survival prolongation while maintaining pre-cancer quality of life. Wilms tumor is the most frequent renal tumor in children, with a high proportion of cases seen in patients less than 5 years of age [7]. It is usually unilateral, although it can be bilateral in up to 10% of cases [7]. Approximately 650 new cases are reported each year in the United States [8]. In 10% of cases, Wilms tumor occurs in association with a syndrome with known predisposition for this type of tumor. Examples include Beckwith Wiedemann Syndrome, or WAGR syndrome [8,9]. Given this known association, guidelines propose surveillance in such patients with renal ultrasound every 3 months until age 7 [9]. In trisomy 18, the incidence of Wilms tumor is reported as 1% [6].

Trisomy 18 was initially described in 1960 and is currently the second most frequent autosomal trisomy after Down's syndrome [3]. The constellation of phenotypic characteristics includes developmental delay, failure to thrive, congenital heart defects, renal abnormalities such as horseshoe kidney or polycystic kidneys, and multiple malformations, among other features<sup>3</sup>.

Even though mortality in Trisomy 18 has always been described as very high, with mortality of 90-95% by the first year of life in some reports [2], more recent studies show an increase in survival, possibly due to the medical advances over the last few years. Meyer et al [4] reviewed data from 1113 patients with trisomy 18 from 9 different states and described a survival of 12.3% at 5 years of age.

As a result of the increased survival in this population, new studies have started to describe an association with different neoplasms, with hepatoblastoma as the most frequent tumor in patients with Trisomy 18, followed by Wilms tumor [1,5,6].

With the improved survival in patients with Trisomy 18, and case reports describing an increased frequency of neoplasms in this population, surveillance has been proposed in this group of patients as well<sup>1</sup>. Since hepatoblastoma is the most frequent tumor in such patients, followed by Wilms tumor, an abdominal ultrasound every 3 months is proposed as surveillance method, with levels of AFP every 3 months as well, up to 4 years of age. After that, follow up with renal ultrasound every 3 months is recommended, up to age 7, mimicking Beckwith-Wiedemann syndrome guidelines [1].

In patients with Wilms tumor, five-year survival is described to be approximately 90%. Management involves upfront nephrectomy, with adjuvant chemotherapy and radiation depending on risk categorization, per Children's Oncology Group (COG), and chemotherapy followed by nephrectomy per the International Society of Pediatric Oncology (SIOP) [10]. Following COG guidelines, our patient initially would have received adjuvant chemotherapy after the surgical resection, with no radiation since it was a Stage I favorable histology, but the family was not in favor of chemotherapy due to concerns regarding quality of life.

For patients with Trisomy 18, there are no treatment guidelines with specific suggestions regarding management, besides surveillance recommendations. This is a particularly difficult group of patients given the multiple comorbidities they usually present with, including congenital cardiac disease. It is very important to consider quality of life in such difficult cases, when comorbidities preclude the possibility of curative treatment. In such complex cases multidisciplinary management, involving the family input, can guide palliative treatment in order to optimize symptom control and uphold family's values

This case highlights the importance of cancer surveillance and multidisciplinary management of patients with Trisomy 18, and the early establishment of multidisciplinary care in these complex patients.

### Conclusion

Medical advances and a multidisciplinary team approach to Trisomy 18 patients has led to prolonged survival. This allows other diseases, such as Wilms tumor, to manifest themselves. For such patients, early surveillance is recommended, and early implementation of multidisciplinary management is crucial to

allow a successful outcome and, in cases of refractory disease, for optimal end of life care.

### References

1. Farmakis SG, Barnes AM, Carey JC, Braddock SR. Solid tumor screening recommendations in trisomy 18. *Am J Med Genet A*. 2019; 179: 455-466.
2. Anderson CE, Punnett HH, Huff V, de Chadarevian JP. Characterization of a Wilms tumor in a 9-year-old girl with trisomy 18. *Am J Med Genet A*. 2003; 121A: 52-55.
3. Rosa RF, Rosa RC, Zen PR, Graziadio C, Paskulin GA. Trisomy 18: review of the clinical, etiologic, prognostic, and ethical aspects. *Rev Paul Pediatr*. 2013; 31: 111-120.
4. Meyer RE, Liu G, Gilboa SM, et al. Survival of children with trisomy 13 and trisomy 18: A multi-state population-based study. *Am J Med Genet A*. 2016; 170A: 825-837.
5. Satgé D, Nishi M, Sirvent N, Vekemans M. A tumor profile in Edwards syndrome (trisomy 18). *Am J Med Genet C Semin Med Genet*. 2016; 172: 296-306.
6. Kepple JW, Fishler KP, Peebles ES. Surveillance guidelines for children with trisomy 18. *Am J Med Genet A*. 2021; 185: 1294-1303.
7. Nelson MV, van den Heuvel-Eibrink MM, Graf N, Dome JS. New approaches to risk stratification for Wilms tumor. *Curr Opin Pediatr*. 2021; 33: 40-48.
8. PDQ® Pediatric Treatment Editorial Board. PDQ Wilms Tumor and Other Childhood Kidney Tumors Treatment. Bethesda, MD: National Cancer Institute. Updated. PMID: 26389282.
9. Spreafico F, Fernandez CV, Brok J, et al. Wilms tumour. *Nat Rev Dis Primers*. 2021; 7: 75.
10. Pater L, Melchior P, Rube C, et al. Wilms tumor. *Pediatr Blood Cancer*. 2021; 68 Suppl 2: e28257.