



# Malrotation Presenting with Congenital Diarrhea Disorder-Like Symptoms

Noor Hamed<sup>1</sup>; Eman Hamid<sup>1</sup>; Vishwanatha Kini<sup>2</sup>; Kamal Hassan<sup>1</sup>

<sup>1</sup>Department of Pediatrics, Hamad General Hospital, Qatar.

<sup>2</sup>Department of Radiology, Hamad General Hospital, Qatar.

## \*Corresponding Author(s): Kamal Hassan

Pediatric Gastroenterology Consultant, PO-Box  
13724, Doha, State of Qatar.

Tel: +974-55205612, Fax: +974-44439571;

Mail: kemo6789@icloud.com

## Abstract

Intestinal malrotation is a congenital condition that can have a disastrous and potentially fatal outcome if not diagnosed early. We report a case of malrotation that presented at two weeks of age with severe diarrhea, poor weight gain, and metabolic acidosis. The patient also developed hypoalbuminemia secondary to protein-losing enteropathy. Infective and metabolic causes were ruled out. The findings of the investigations on causes of congenital diarrheal disorders were unremarkable. Imaging studies, including upper gastrointestinal series, abdominal ultrasound, and plain abdominal X-ray, were suggestive of midgut malrotation, which was confirmed and corrected by surgery. Post-operatively, all her symptoms resolved, and she started gaining weight and growing remarkably well. To the best of our knowledge, this is the first case of malrotation presenting with early-onset severe diarrhea mimicking congenital diarrheal disorders.

Received: Nov 16, 2020

Accepted: Dec 17, 2020

Published Online: Dec 21, 2020

Journal: Annals of Pediatrics

Publisher: MedDocs Publishers LLC

Online edition: <http://meddocsonline.org/>

Copyright: © Kamal H (2020). *This Article is distributed under the terms of Creative Commons Attribution 4.0 International License*

**Keywords:** Malrotation; Congenital diarrheal disorders.

**Abbreviations:** GI: Gastrointestinal; CDD: Congenital Diarrheal Disorders; PLE: Protein Losing Enteropathy; TPN: Total Parenteral Nutrition.

## Introduction

Intestinal malrotation results from a failure of rotation and fixation of bowel segments, leading to abnormalities in intestinal positioning and attachment that leave obstructing bands across the duodenum and a narrow pedicle for the midgut loop [1]. The rotation abnormality can be asymptomatic, but may also cause a variety of symptoms depending on the presence of non-rotation or malrotation and volvulus and whether the volvulus is partial or intermittent [2]. The pathologic effects of

anomalies of rotation arise from excessive mobility, compression, or kinking of the bowel and predisposition to torsion, volvulus, and intussusception [3]. Acute presentation of midgut volvulus occurs most frequently in neonates, with the likelihood decreasing with age. Up to 50% of midgut volvulus cases present within the first week of life and 50-66.5% in the neonatal period [1].



**Cite this article:** Hamed N, Hamid E, Kini V, Hassan K. Malrotation Presenting with Congenital Diarrhea Disorder-Like Symptoms. *Ann Pediatr.* 2020; 3(1): 1046.

## Case report

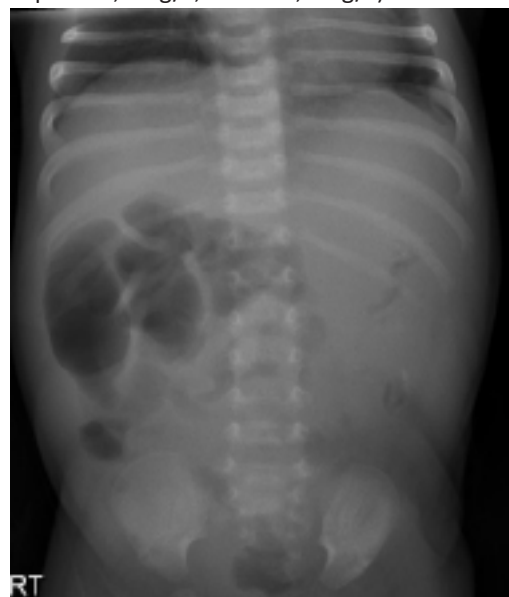The parents' free and informed written consent was obtained for publishing this case. The patient was a 2-week-old Palestinian girl born at term to non-consanguineous parents. Her birth weight was 2.9 kg; no admission to the neonatal intensive care had been required, and breastfeeding was established. She presented to the pediatric emergency department of our hospital with a history of mild vomiting and diarrhea since age 2 days. The vomiting had improved; however, her diarrhea worsened to 8-12 motions/day and was the main reason for seeking medical advice. She was failing to gain weight, and her mother described intermittent episodes of inconsolable screaming associated with abdominal distension, followed by lethargy. There was no history of fever. Initial blood tests showed normal serum electrolyte levels; however, metabolic acidosis with a normal anion gap was present (sodium, 132 mmol/L; potassium, 3.3 mmol/L; chloride, 105 mmol/L; urea, 5.8 mmol/L; creatinine, 40  $\mu$ mol/L; HCO<sub>3</sub>, 9 mmol/L; base excess, -17 mmol/L; total protein, 55 g/L; albumin, 34 g/L; hemoglobin, 15 g/dL; white blood cells, 25.4 $\times$ 10<sup>3</sup>/ $\mu$ L [neutrophils, 53%; lymphocytes, 39%; monocytes, 4.5%; and eosinophils, 2%]; platelets, 867 $\times$ 10<sup>3</sup>/ $\mu$ L; and normal lactic acid and ammonia levels). A septic workup was performed, and intravenous antibiotics were started empirically. However, all culture results were negative. The findings of other investigations, including congenital infection screening, stool microbiology, stool elastase, serum amino acids, pancreatic enzymes, immunoglobulin levels, lipid profile, food allergy screening, sweat chloride test, and congenital disorders of glycosylation testing, were unremarkable. Initial abdominal ultrasound revealed fluid- and gas-distended small bowel loops.

She continued to have episodes of abdominal distension, profuse diarrhea, and severe acidosis when breast milk was provided, even after the mother stopped taking dairy products in her diet. Changing to an exclusive elemental formula (Neocate LCP, SHS, Liverpool, UK) made no difference to her condition. Her serum albumin level quickly dropped to 18-20 g/L (normal, 30-43 g/L), and she developed palpebral and peripheral edema. Urinary protein was negative. Feeding had to be stopped, and she was started on Total Parenteral Nutrition (TPN) 10 days post admission. With no improvement in her symptoms, upper gastrointestinal endoscopy and colonoscopy were performed to rule out enteropathy and colitis. The macroscopic appearances of the esophagus, stomach, duodenum and colon were unremarkable. The histopathology of the biopsies taken also described normal histology. Plain abdominal X-ray showed most of the dilated gas-filled bowel loops located to the right side of the abdomen, typical of malrotation (Figure 1). Upper Gastrointestinal (GI) series showed gastroesophageal reflux reaching the upper esophagus, with the fourth part of the duodenum and the duodenojejunal flexure lying to the left of the midline, but below the level of the duodenal cap and caudad to the third part, suggesting partial malrotation (Figure 2A). The jejunum was dilated, and delayed films at 3 and 6 hours suggested that the caecum and appendix were in the left abdomen (Figure 2B). Doppler ultrasound of the abdomen showed inverse orientations of the superior mesenteric artery and the superior mesenteric vein consistent with midgut malrotation but no "whirlpool sign" to suggest volvulus.

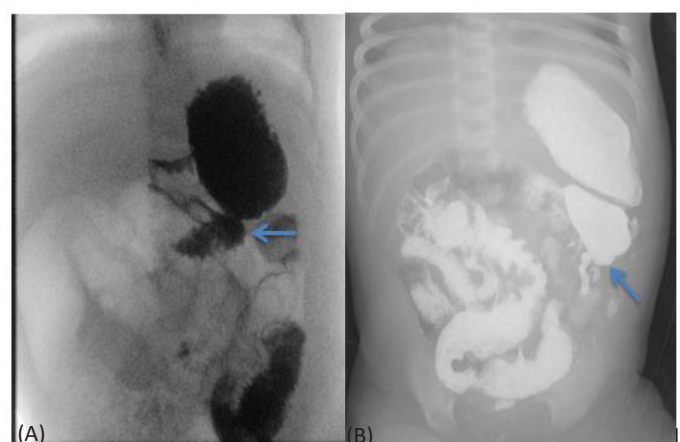
Because of failure to progress in feeding, persistent hypoproteinemia, and radiological findings suggestive of malrota-

tion, an exploratory laparotomy was performed at age 37 days (22 days post admission). Multiple adhesion bands were found between the intestinal loops and the anterior abdominal wall. The position of the cecum was high; the colon was on the left side, and the duodenojejunal junction was on the right side, confirming the diagnosis of malrotation. Ladd's procedure was then performed.

The patient recovered well, and feeding was reintroduced on day 4 post surgery. Full feeding was achieved without any vomiting or diarrhea, and TPN was stopped by day 8 post surgery. The serum albumin level increased from 18 g/L before surgery to 35-40 g/L from day 6 post surgery onward. She was discharged on day 16 post surgery. At the regular outpatient clinic review, she remained asymptomatic with excellent weight gain and growth. Repeat blood tests one week after discharge showed normal electrolyte and albumin levels: sodium, 136 mmol/L; potassium, 4.3 mmol/L; chloride, 102 mmol/L; urea, 4.8 mmol/L; creatinine, 45  $\mu$ mol/L; HCO<sub>3</sub>, 22 mmol/L; base excess; total protein, 70 g/L; albumin, 40 g/L).



**Figure 1:** Plain abdominal X-ray showing most of the dilated gas-filled bowel loops located to the right side of the abdomen, typical of malrotation.



**Figure 2:** (A) Barium meal follow-through showed duodenojejunal junction (arrow) lying at a lower level than the duodenal bulb level. (B) Delayed films demonstrated the caecum and the appendix located in the left iliac fossa (arrow).

## Discussion

Early diagnosis of malrotation is important, and there are several reports in the literature that discuss the impact of delayed diagnosis on the outcomes of malrotation and volvulus, with more time elapsed typically leading to an increased mortality or morbidity [3-6]. Abnormalities of intestinal rotation and fixation classically present in newborns or infants with sudden onset of bilious vomiting, reflecting either acute midgut volvulus or duodenal obstruction from Ladd's bands [4]. Although symptoms other than bilious vomiting have been described with malrotation, these atypical presentations are rare and usually occur beyond infancy.

The main presenting symptoms of our patient were early onset of severe diarrhea leading to dehydration and metabolic acidosis. She also had severe feeding intolerance while on breast milk and even when she was put on a hypoallergenic formula. Her symptoms were severe enough to require stopping all feeding and starting TPN. Infective causes were ruled out, and the possibility of allergy to cow's milk protein became very unlikely with the lack of response to the elemental formula. Such a presentation that started soon after birth is typical of Congenital Diarrheal Disorders (CDD), which is defined as a group of inherited enteropathies with a typical early onset and frequent chronic diarrhea of sufficient severity to require parenteral nutrition [7]. Soon after admission, our patient's serum albumin level dropped significantly, and she developed peripheral and palpebral edema that continued even after improving the nutrition by giving full TPN. In the presence of diarrhea and the absence of proteinuria or another non-GI source of protein loss, this is strongly suggestive of Protein-Losing Enteropathy (PLE), which is defined as a rare complication of a variety of intestinal disorders characterized by an excessive loss of proteins into the GI tract due to impaired integrity of the mucosa [8]. Both CDD and PLE are challenging clinical conditions because of their severity and the broad range of diseases in their differential diagnoses; their diagnostic work up usually requires numerous investigations that can be costly, invasive, or both [8,9]. There are reports in the literature of malrotation presenting as chronic malabsorption [10,11] or PLE [12,13]. However, unlike our patient, who was only 2 days old when her symptoms started, the other reported patients were all much older (age range, 8 months to 10 years). Another difference is the acute presentation in our patient (less than 2 weeks) compared with chronic courses in the other patients that ranged between 2 months and 6 years. Many mechanisms have been postulated as the cause of diarrhea and PLE in cases of malrotation, including vascular and lymphatic compromises from proximal occlusion of the mesenteric vessels with or without mucosal injury, resulting in increased mucosal permeability [5,8,13].

Although the clinical presentation of our patient was suggestive of CDD, the blood and stool tests did not fit any particular malabsorptive disorder, and the bowel biopsy results were totally unremarkable, which did not support our initial impression of CDD. With the development of PLE, we started excluding its various causes. The report of Zellous et al., [13] that associated malrotation with PLE prompted us to arrange upper GI series and reach the right diagnosis. This highlights the importance of reporting unusual presentations of medical conditions to alert other colleagues of such atypical scenarios.

## Conclusion

Midgut malrotation should be considered in the differential diagnosis of CDD. Early consideration of this diagnosis will help avoid unnecessary expensive or invasive investigations and catastrophic consequences of missing midgut volvulus secondary to malrotation.

## References

1. Ezer SS, Oguzkurt P, Temiz A, Ince E, Gezer HO, et al. Intestinal malrotation needs immediate consideration and investigation. *Pediatr Int.* 2016; 58: 1200-1204.
2. Langer JC. Intestinal rotation abnormalities and midgut volvulus. *Surg Clin North Am.* 2017; 97: 147-159.
3. Millar AJ, Rode H, Cywes S. Malrotation and volvulus in infancy and childhood. *Semin Pediatr Surg.* 2003; 12: 229-236.
4. Powell DM, Othersen HB, Smith CD. Malrotation of the intestines in children: The effect of age on presentation and therapy. *J Pediatr Surg.* 1989; 24: 777-780.
5. Lee HC, Pickard SS, Sridhar S, Dutta S. Intestinal malrotation and catastrophic volvulus in infancy. *J Emerg Med.* 2012; 43: e49-e51.
6. Messineo A, MacMillan JH, Palder SB, Filler RM. Clinical factors affecting mortality in children with malrotation of the intestine. *J Pediatr Surg.* 1992; 27: 1343-1345.
7. Terrin G, Tomaiuolo R, Passariello A, Elce A, Amato F, et al. Congenital diarrheal disorders: An updated diagnostic approach. *Int J Mol Sci.* 2012; 13: 4168-4185.
8. Braamskamp MJ, Dolman KM, Tabbers MM. Clinical practice. protein-losing enteropathy in children. *Eur J Pediatr.* 2010; 169: 1179-1185.
9. Canani RB, Castaldo G, Bacchetta R, Martin MG, Goulet O. Congenital diarrhoeal disorders: Advances in this evolving web of inherited enteropathies. *Nat Rev Gastroenterol Hepatol.* 2015; 12: 293-302.
10. Jackson A, Bisset R, Dickson AP. Malrotation and midgut volvulus presenting as malabsorption. *Clin Radiol.* 1989; 40: 536-537.
11. Imamoglu M, Cay A, Sarihan H, Sen Y. Rare clinical presentation mode of intestinal malrotation after neonatal period: Malabsorption-like symptoms due to chronic midgut volvulus. *Pediatr Int.* 2004; 46: 167-170.
12. Burke V, Anderson Cm. Chronic volvulus as a cause of hypoproteinaemia, oedema and tetany. *J Paediatr Child Health.* 1966; 2: 114-118.
13. Zellos A, Zarganis D, Ypsiladis S, Chatzis D, Papaioannou G, et al. Malrotation of the intestine and chronic volvulus as a cause of protein-losing enteropathy in infancy. *Pediatrics.* 2012; 129: e515-e518.