



Cutaneous Calcinosis in Pediatrics: Report of Five Cases

Mouaddine Khadija*; Aarbaoui Nisrine; Bentahila Abdelali; Chkirate Bouchra

Department of pediatrics, children's hospital of Rabat, Mohammed V University, Morocco.

***Corresponding Author(s): Khadija Mouaddine**

Department of pediatrics, children's hospital of Rabat,
Mohammed V University, Riad Loudaya 12020 Temara
Morocco.

Tel: +21235306318;

Email: khadijamouaddine7@gmail.com

Abstract

Calcinosis is a common complication of connectivities, including systemic scleroderma, CREST syndrome, dermatomyositis and systemic lupus erythematosus [1]. Our study consists of the retrospective analysis of five patients followed for calcinosis in the pediatric department of the children's hospital over a period from 2003 to 2019.

The average age of our patients was 5.9 years with 100% female predominance. Calcinosis was secondary to juvenile dermatomyositis in four cases, and idiopathic in only one case. It affected several anatomical sites in all our patients.

The serum calcium/phosphate levels were within range in all our patients; an inflammatory syndrome was noted in 03 patients, with positive antinuclear antibodies in 02 patients. Pathological examination showed an appearance of dermatomyositis with muscular and sub epidermal calcinosis in 02 patients, and the presence of calcifications with an inflammatory reaction to a giant cell-type foreign body in 02 cases.

Therapeutically: Surgical excision was performed in 2 patients: Idiopathic calcinosis and follow-up for dermatomyositis. Oral corticosteroid therapy was prescribed in our 04 patients with a progressive decrease, one of them had relapses requiring prolonged corticosteroid therapy and one patient was put on methotrexate then on bisphosphonates with partial improvement then on calcium channel blockers with remarkable progress.

Received: Jul 23, 2021

Accepted: Aug 18, 2021

Published Online: Aug 20, 2021

Journal: Annals of Pediatrics

Publisher: MedDocs Publishers LLC

Online edition: <http://meddocsonline.org/>

Copyright: © Mouaddine K (2021). *This Article is distributed under the terms of Creative Commons Attribution 4.0 International License*

Keywords: Dermatomyositis; Child; Calcinosis; Treatment.

Introduction

Cutaneous calcinosis is a group of diseases in which calcium deposits form in the skin. These deposits consist mainly of calcium hydroxyapatite crystals or amorphous calcium phosphate [2]. It can be associated with metabolic abnormalities phosphocalcic but it may also occur without metabolic disorder, in particular some connectivities. Among these, the most represented are dermatomyositis and limited forms of systemic scleroderma

[3]. It mostly affects children, and it is responsible for pain and functional discomfort, especially when it is in periarticular areas. The treatment of localized forms is mainly surgical. However, the management of diffuse forms often remains difficult, with disappointing therapeutic results for the moment [2]. We report the history of five children followed in our department for calcinosis.



Cite this article: Khadija M, Nisrine A, Abdelali B, Bouchra C. Cutaneous Calcinosis in Pediatrics: Report of Five Cases. *Ann Pediatr.* 2021; 4(1): 1076.

Materials and methods

Case 1

In 2018, Sara, a 6-years-old girl, presented calcifications located in the right elbow and knee (Figure 1), diagnosed as an idiopathic calcinosis.

These lesions were painful and increasing in size, making the mobilization of the elbow and knee so difficult.

Inflammatory, serum calcium/phosphate levels, and muscle enzyme tests as well as an immunological and ophthalmological examination were normal.

The X-rays of the elbow showed a confused appearance with ossifying myositis or a neoplastic process. The electromyography revealed moderate ulnar nerve damage.

The elbow and tibia biopsy showed calcinosis with a foreign body inflammatory reaction of giant cell type, without tumor cells.

Our patient benefited to surgical excision, with a great evolution marked by regression of the calcinosis (Figure 2, 3).

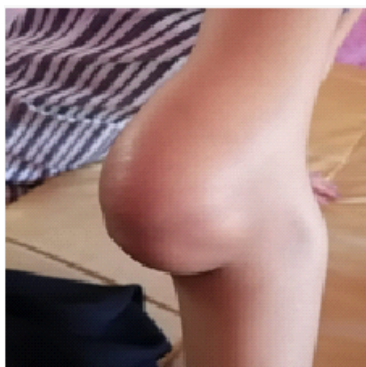

Figure 1: Picture showing tumefaction of the right elbow.

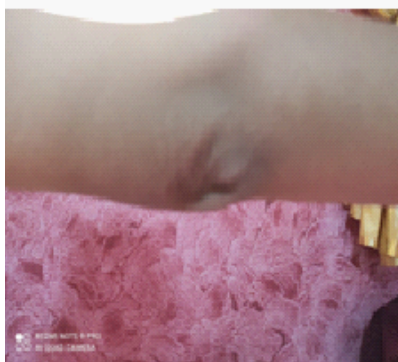

Figure 2: Picture showing decrease in size of calcinosis.




Figure 3: Picture showing regression of Calcinosis.

Case 2

Laila, a 5 years old girl, developed calcinosis secondary to Juvenile Dermatomyositis (JDM). Calcinosis of different sizes was seen on the elbows, hips, and knees. The blood analysis showed a biologic inflammatory syndrome: A high erythrocyte sedimentation rate: 44 mm/90mm, thrombocytosis at 443000. Serum muscle enzymes: an increase in Creatine Kinase (CK): 750 UI/l, and Lactate dehydrogenase at 192 UI/L, kidney function and serum calcium/phosphate levels were normal. Myositis-specific autoantibodies and myositis-associated antibodies (anti-Jo-1, U1-RNP, SSA/Ro60KD, PM-Scl100 and Ku) were normal, as well as anti-DNA and antinuclear antibodies and rheumatoid factor. The pelvis's CT scan showed a calcinosis of the soft parts. The electromyography revealed an inflammatory myopathy. The ophthalmological examination was normal. Histopathological diagnosis of dermatomyositis with muscle calcinosis and sub epidermal has been established.

Our patient was treated with methylprednisolone (3 doses of 1g/1.73m² per day) and prednisone (at a dose of 2mg/kg/day) for 8 weeks, with progressive degression. Subsequently, she had two relapses requiring the use of long-term Corticosteroids associated to methotrexate with improvement of her clinical and biological status: disappearance of calcinosis, improvement of muscle strength and synovitis, normalization of the inflammatory test and creatine kinase.

Case 3

Imane, a 10-years-old girl, was diagnosed with dermatomyositis in a local hospital, and took systemic corticosteroid without significant improvement. Started to present calcinosis lesions of different sizes on forearms, elbows, thighs, hips and knees (Figure 4,5,6,7&8). The blood analysis showed a biologic inflammatory syndrome: A high erythrocyte sedimentation rate: 86 mm/120 mm/H, reactive protein C: 160mg/l, inflammatory microcytic hypochromic anemia: Hemoglobin = 8.4, Mean Corpuscular Volume (MCV)=66, Mean Corpuscular Hemoglobin Concentration (MCHC)=20, White blood cells=7340/mm³ and Platelets=429,000. Creatine Kinase (CK) increased: 1950 IU/L, Lactate Dehydrogenase (LDH): 192 IU/L. Renal function, serum calcium/phosphate levels and urinary ionogram are normal. Anti-nuclear antibodies were positive >1280 speckled type. No signs of uveitis on ophthalmologic examination. The X-ray showed calcium deposits in the soft tissues of the hips, thighs, and knees. Electromyography revealed the appearance of an inflammatory myopathy.

A histopathological diagnosis of dermatomyositis with muscular and sub epidermal calcinosis was established. Therefore, the patient was put on corticosteroid (2mg/kg/day by oral administration) associated with an immunosuppressive therapy: low-dose methotrexate, until the stabilization of the disease. She received a surgical excision for the biggest nodule of calcinosis of the right knee.

Thereafter, and in association with corticosteroid therapy, we started treatment with biphosphonates: Pamidronate disodium (30mg/day by intravenous route) six times a month, then twice every three months, without significant improvement of the calcinosis.

Diltiazem at a dose of 60 mg/day was started; the dose was increased over the next six months to 150 mg/day. She continued to take the diltiazem 150 mg/day in association with prednisone 5 mg for two years. We notice regression of calcinosis

and remission of myositis.

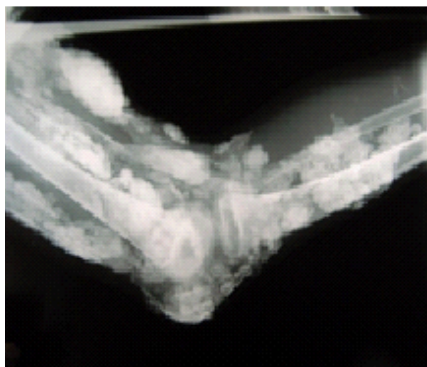


Figure 4: Calcareous streaks extending to the arm and forearm.

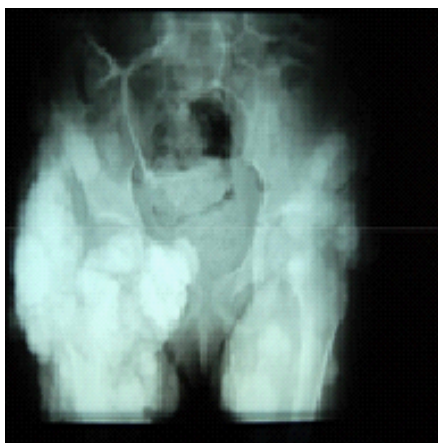

Figure 5: Calcareous streaks extending to lower limbs.

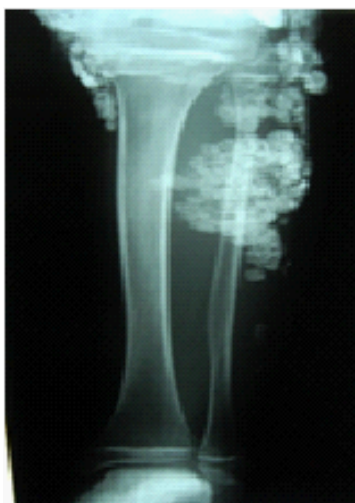

Figure 6: Calcareous streaks extending to the leg.

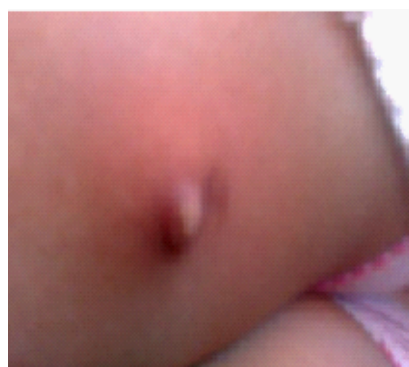


Figure 7: Calcinosis of the thigh.

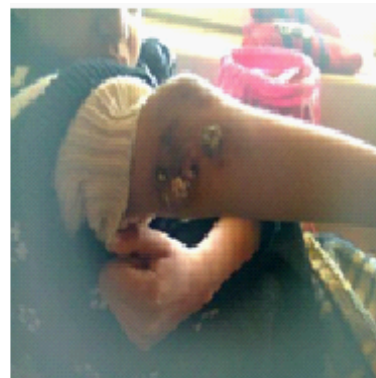


Figure 8: Calcinosis of the elbow.

Case 4

Douae, a 06 years old girl, who has been suffering from inflammatory arthralgias for 05 months in her hips, spine and knees ,with muscle weakness. She occasionally took non-steroidal anti-inflammatory drugs. Three months later, nodules of different sizes were observed on the hips and knees with ulcerations (Figure 9, 10). Gottron's papules were also seen on the hands and elbows.

The blood analysis showed a biologic inflammatory syndrome: A high erythrocyte sedimentation rate: 37 mm/H, inflammatory microcytic hypochromic anemia: Hemoglobin at 10.7 g/dl, Mean Corpuscular Volume(MCV): 70fl, Mean Corpuscular Hemoglobin Concentration (MCHC): 31.4%, white blood cells: 7600/mm³, platelets: 396000/mm³, ferritin: 200ng/ml, C-reactive protein was negative; creatine kinase at 34 UI/l; serum calcium/phosphate levels, kidney function and proteinuria were normal. Antinuclear antibodies were positive. Other autoantibodies used for connectivities and autoimmune diseases (DNA antibodies, ANCA, scl70), rheumatoid factor and C3 and C4 supplements were normal.

Ophthalmologic examination was unremarkable. The pelvis X-ray showed a periosteal reaction of the right iliac wing. Magnetic Resonance Imaging (MRI) of the pelvis showed a left hip effusion. Electroneuromyography was normal. Microscopically, there was fibrous tissue with several areas of calcification in the center associated with a foreign body giant cell reaction.

In view of the clinical, biological and immunological arguments, the diagnosis of juvenile dermatomyositis was suspected. Although electroneuromyographic and histology were not compatible with it, but given the active calcinosis, it was considered as a dermatomyositis complicated by calcinosis, our patient was treated with a low dose of corticosteroid (0.5mg/kg/ day) for 02 months, the follow-up is ongoing.

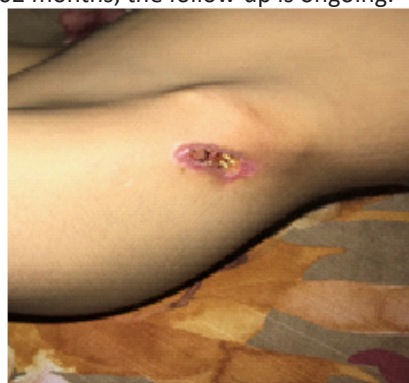

Figure 9: Ulcerations and exposure of calcinosis in the left iliac wings.

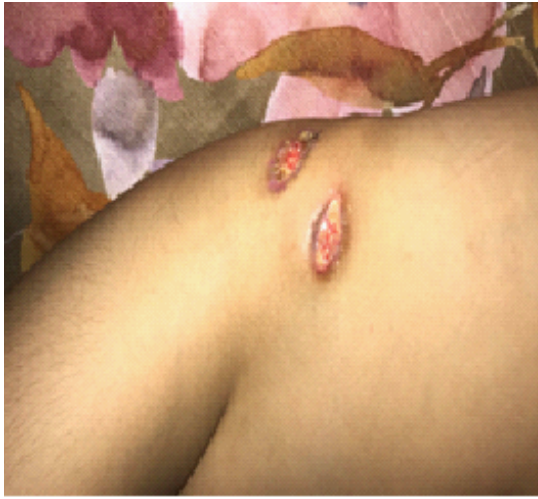

Figure 10: Ulcerations and exposure of calcinosis in the right iliac wings.

Case 5

Jamila, a 02 and a half years old girl, had a muscular deficit, periorbital erythroderma since 06 months, diagnosed as a JDM.

The blood analysis showed elevated muscle enzymes, myogenic damage on electroneuromyographic, and severe interstitial myositis on muscle biopsy. Under corticosteroid treatment, improvement of muscle signs was noted with stabilization of skin lesions, but during the degression, calcium deposits appeared in the two forearms, which worsened and became disseminated to the buttocks, thighs, and knees (Figure 11,12,&13).

A treatment with colchicine, then biphosphonates was prescribed. The immediate evolution was favorable, but this treatment could not be followed up due to lack of resources.

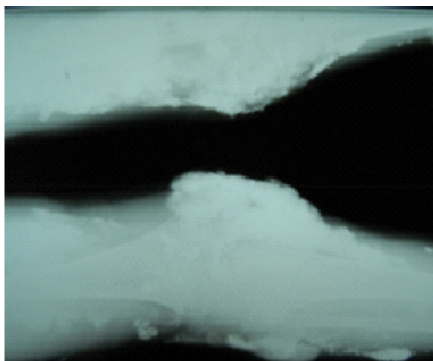


Figure 11: Calcareous deposit on the legs and thighs.

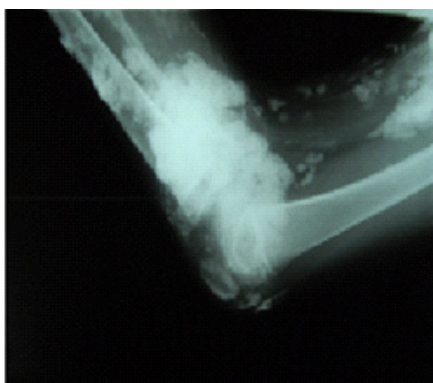


Figure 12: Calcareous streaks extending to the forearm.

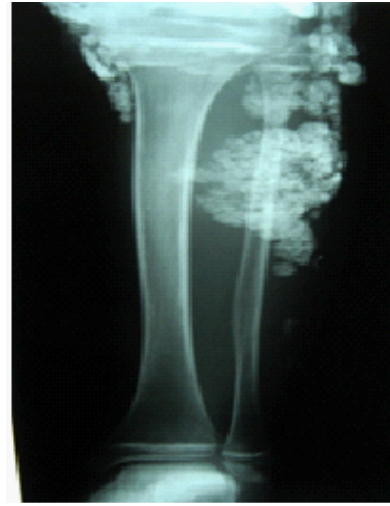

Figure 13: Calcareous deposits of the leg.

Results and discussion

Calcinosis is a common complication of connectivities, which is difficult to treat. It is responsible for pain, ulcerations and a significant functional impact which affects the quality of life. Its medical care is difficult and many treatments have been tried [1].

According to serum calcium/phosphate levels, Calcinosis is classified into several subgroups: dystrophic, metastatic, idiopathic and iatrogenic. Dystrophic calcinosis is associated with autoimmune diseases and its physiopathology is still unclear [4].

In many systemic diseases, cutaneous calcinosis may occur. Most of the time, these calcifications are not associated with alterations in phosphocalcific metabolism.

Among the child's connectivities, dermatomyositis is the most frequent disease after lupus. The calcinosis represents the specificity of this affection in children and by which it differs from that of adults.

Calcinosis remains a significant source of morbidity for many JDM patients, yet it is poorly understood and lacks uniform treatment approaches compared to other aspects of JDM [5].

In our study, calcinosis was secondary to dermatomyositis in 04 patients (80% of cases).

Dystrophic calcinosis is the most frequently described form; however the idiopathic variant is the rarest [6], which agrees with the data from our study where there are 04 cases of dystrophic calcinosis and one case of idiopathic calcinosis.

In the literature, there is a male predominance in idiopathic cutaneous calcinosis [7]. However, no sexual predominance has been documented in other types of calcinosis [6]. While a female predominance was found in our series (05 girls and 0 boys).

In dystrophic calcinosis caused mainly by connective tissue diseases, an aggressive treatment is proposed to achieve a fast and complete control of tissue inflammation, allowing the regression of the calcinosis [5].

No single treatment has been generally accepted as standard therapy, although a variety of treatments have been reported to be beneficial, including warfarin, bisphosphonates, minocycline, ceftriaxone, diltiazem, aluminum hydroxide, probenecid, intralesional corticosteroids, intravenous immunoglobulin, car-

bon dioxide laser, lithotripsy, and surgical excision [3].

The treatment of primary or secondary localized calcinosis is based on surgical excision of the lesions [8,9], and the associated lesion (tumor). These little ones lesions have a positive prognosis, shown in worse by the prognosis of the associated tumor [2].

The medical treatment of calcinosis associated with connectivities is a real challenge because no drug has been able to reproducibly demonstrate its efficacy in stopping the progression or reducing dystrophic calcifications.

Biphosphonates: IV pamidronate has been So far the most used product at the child, it seems to be effective in child's dermatomyositis [10]. The frequency of injections and the dosage of the treatment are specific to each child and takes into account his age and weight.

In a 14-year-old girl followed for juvenile dermatomyositis complicated by calcinosis, administration of pamidronate at a dose of 15mg every three months for the first year, then 30mg every four months for the second year, equivalent to 2mg/kg per year, associated with prednisone (4mg/day) allowed complete disappearance of the calcinosis [11].

Biphosphonates were the treatment of 2 cases in our study: partial improvement in one case and favorable improvement in the other.

Biphosphonates remain a therapeutic option mostly in Dermatomyositis, with at least partial response noted in 4 studies. Nevertheless, a lack of substantive data precludes recommending a specific regimen of biphosphonates [12].

Diltiazem: Has recently been implicated in cutaneous calcinosis reduction, its favorable effect has already been reported in a few patients. Cutaneous calcinosis in dermatomyositis has been successfully treated with diltiazem (2-4 mg/kg/d). Lower doses of diltiazem had no effect on calcinosis [13]. In addition, Ichiki et al. treated a 3-year-old girl with calcification secondary to JDM with diltiazem. After one year of treatment with a daily dose of diltiazem of 30 mg, the calcium deposits had practically disappeared [13].

In our study, a patient initially treated by corticosteroid therapy with methotrexate without improvement, then put on bisphosphonates with partial improvement. Diltiazem made it possible to obtain regression of calcinosis with remission of myositis.

Probenecid: Has been proposed as a treatment for calcinosis complicating juvenile dermatomyositis [14]. The recommended dosage is 8 to 30 mg/kg/d for 2 to 18 months [15]. Probenecid acts by increasing renal tubular reabsorption of phosphate, leading to decrease in serum phosphorus and consequently reduction of tissue calcium deposition [16].

Sodium thiosulfate (STS): An antioxidant and chelator of cations may increase calcium solubility when it combines with cations. Intravenous, intralesional and topical STS have been successfully used to treat calciphylaxis, while topical and intralesional STS, as well as topical sodium metabisulfite, have been reported as effective in several cases of localized calcinosis cutis [17].

The authors have recently used it for ulcerated calcinosis of the lower limbs of 2 patients. After 12 to 15 weeks of applying a solution 25% in zinc oxide, the lesions were completely resolved [18].

Jost J, et al have published a successful treatment of hyperphosphatemic familial tumoral calcinosis with topical sodium thiosulfate in a 12-year-old male and 10-year-old female. Given the location of the lesion, and the lack of significant functional impairment, surgical resection was ruled out in favor of topical STS. A significant clinical and radiological decrease of ectopic calcifications was observed after at least 5 months of treatment. Overall 440mg of STS was delivered over a 13-month period. The STS treatment was well tolerated and no clinical or biological side effects were observed [19,20].

Colchicine: has anti-inflammatory properties and is widely prescribed in the treatment of microcrystalline arthritis. By analogy with this situation, which causes inflammation around a "foreign body", it has therefore been prescribed in calcinosis. The literature reports efficacy in almost half of the patients reported, with a dose ranging from 1 to 1.8 mg per day [3].

Aluminum hydroxide: Has been evaluated orally in patients with calcinosis associated with juvenile dermatomyositis, satisfactory responses were observed within 4 to 8 months of initiation [21].

Warfarin: Berger et al. and Matsuoka et al. were able to use low doses of warfarin for patients with JDM and nodular calcinosis. These authors reported a decrease in lesion size after the use of warfarin for three years [21]. In a study testing warfarin 1 mg daily in 8 patients, morphological results were noted [3]. However, even when response is clinically measurable, it can sometimes be delayed for up to 1 year.

Anti-TNF-alpha: Riley, et al. report therapeutic success in 5 patients with juvenile dermatomyositis treated with infliximab, while a recent case of anti-PMScl scleromyositis also seems to have benefited from this molecule, with a follow up of 41-month without worsening infiltrative pneumopathy [3].

Rituximab: The use of anti-CD20 antibodies has recently been proposed for the treatment of certain infiltrative lung diseases associated with systemic scleroderma.

It is in this indication that patients with refractory calcinosis have benefited. However, its efficacy is very inconsistent as in a prospective multicenter trial treating 9 dermatomyositis patients less than 16 years of age with rituximab, there were 5 patients with calcinosis (including one treated for this indication) but no one benefited from the treatment [22].

Intravenous immunoglobulin: Its efficacy in dermatomyositis has been well established, particularly in corticoreistant forms, but its efficacy in calcinosis has only been described in a few cases [23].

Conclusion

Calcinosis is a redoubtful complication of juvenile dermatomyositis; its disabling character puts the functional prognosis at stake. Several unknowns still persist in the etiopathogeny and therapeutic choice. Biphosphonates and/or diltiazem seem to be the treatments that could be proposed as first line in the treatment of extensive diffuse calcinosis of JDM.

References

1. Mageau A, Guignon V, Ratzimbasafy V, Bardin T, Richette P, et al. Traitement par thiosulfate de sodium intraveineux pour les calcinosis liées aux connectivites: A propos de 4 cas. *Revue du Rhumatisme*. 2017; 84: 547-550.

2. Battistella M, Cribier B. Les calcinoses cutanées. *Revue du rhumatisme monographies*. 2011 ; 1; 78: 178-186.
3. Bienvenu B. Traitement des calcinoses sous-cutanées des connectivites. *La Revue de médecine interne*. 2014; 35: 444-452.
4. Fabreguet I, Saurat JH, Rizzoli R, Ferrari S. Calcinose cutanée associée aux connectivites. *Rev Med Suisse*. 2015; 11: 668-672.
5. Orandi AB, Baszis KW, Dharnidharka VR, Huber AM, Hoeltzel MF. Assessment, classification and treatment of calcinosis as a complication of juvenile dermatomyositis: A survey of pediatric rheumatologists by the Childhood Arthritis and Rheumatology Research Alliance (CARRA). *Pediatric Rheumatology*. 2017; 15: 1-10.
6. Nunley JR. *Cutis calcinosis*. 2009.
7. Calonje E, Brenn T, Lazar A, McKee PH. *Calcinosis cutis*. *McKee's Pathology of the Skin*, 4th edition published by Elsevier. 2009.
8. Giorgini S, Martinelli C, Massi D, Lumini A, Mannucci M, et al. Iatrogenic calcinosis cutis following nadroparin injection. *Int J Dermatol*. 2005; 44: 855-857.
9. Saddic N, Miller JJ, Miller OF, Clarke JT. Surgical debridement of painful fingertip calcinosis cutis in CREST syndrome. *Arch Dermatol*. 2009; 145: 212-213.
10. Marco Puche M, Calvo Penades I, Lopez Montesinos B. Effectiveness of the treatment with intravenous pamidronate in calcinosis in juvenile dermatomyositis. *Clin Exp Rheumatol* 2010; 28:135-140.
11. Slimani S, Abdessemed A, Haddouche A, Ladjouze-Rezig A. Résolution complète d'une calcinose universelle compliquant une dermatomyosite juvénile traitée par pamidronate. *Revue du rhumatisme*. 2010; 77: 91-93.
12. Traineau H, Aggarwal R, Monfort JB, Senet P, Oddis CV, et al. Treatment of calcinosis cutis in systemic sclerosis and dermatomyositis: A review of the literature. *Journal of the American Academy of Dermatology*. 2020; 82: 317-325.
13. Reiter N, El-Shabrawi L, Leinweber B, Berghold A, Aberer E. Calcinosis cutis: part II. Treatment options. *Journal of the American Academy of Dermatology*. 2011; 65: 15-22.
14. Nakamura H. Efficacy of probenecid for a patient with juvenile dermatomyositis complicated with calcinosis. *Journal of Rheumatology*. 2006; 33: 1691-1693.
15. Lisa G. Rider. Treatment of Refractory Juvenile Dermatomyositis", 66 th Annual American College of Rheumatology Meeting. 2002.
16. Harel L, Harel G, Korenreich L, Straussberg R, Amir J. Treatment of calcinosis in juvenile dermatomyositis with probenecid: the role of phosphorous metabolism in the development of calcifications. *J Rheumatol*. 2001; 28: 1129-1132.
17. Song P, Fett NM, Lin J, Merola JF, Costner M, Vleugels RA. Lack of response to intravenous sodium thiosulfate in three cases of extensive connective tissue disease-associated calcinosis cutis. *British Journal of Dermatology*. 2018; 178: 1412-1415.
18. Bair B, Fivenson D. A novel treatment for ulcerative calcinosis cutis. *J Drugs Dermatol*. 2011; 10: 1042-1044.
19. Jost J, Bahans C, Courbebaisse M, Tran TA, Linglart A, et al. Topical sodium thiosulfate: A treatment for calcifications in hyperphosphatemic familial tumoral calcinosis?. *The Journal of Clinical Endocrinology & Metabolism*. 2016; 101: 2810-2815.
20. Goossens J, Courbebaisse M, Caudron E, Bahans C, Vacquerie V, et al. Efficacy of intralesional sodium thiosulfate injections for disabling tumoral calcinosis: Two cases. *In Seminars in arthritis and rheumatism*. 2017; 47: 451-455.
21. Touimy M, Janani S, Rachidi W, Étaouil N, Mkinsi O. Calcinose universelle compliquant une dermatomyosite juvénile: Amélioration sous immunoglobulines intraveineuses. *Revue du rhumatisme*. 2013; 1: 93-94.
22. Bader-Meunier B, Decaluwe H, Barnerias C, Gherardi R, Quartier P, et al. Safety and efficacy of rituximab in severe juvenile dermatomyositis: Results from 9 patients from the French Autoimmunity and Rituximab registry. *The Journal of rheumatology*. 2011; 38: 1436-1440.
23. Al-Mayouf SM, Laxer RM, Schneider R, Silverman ED, Feldman BM. Intravenous immunoglobulin therapy for juvenile dermatomyositis: Efficacy and safety. *J Rheumatol*. 2000; 27: 2498-2503.