



CF Newborn Screening Positive, Initial Repeated Sweat Test Negative, CF Anyways?

Hildebrandt J¹; Keßler A¹; Hauenstein C²; Müller C³; Ballmann M^{1*}

¹University Medical Center, Department of Pediatrics, Rostock Germany.

²University Medical Center, Department of Pediatric Radiology, Rostock Germany.

³University Medical Center, Department of Clinical Chemistry and Laboratory Medicine, Greifswald Germany.

***Corresponding Author(s): Manfred Ballmann**

Department of Pediatrics, Rostock University Medical Centre, Ernst-Heydemann Strasse 8, DE 18057 Rostock, Germany.

Email: Manfred.Ballmann@Med.Uni-Rostock.de

Abstract

Nationwide CF newborn screening in Germany was established in 2016. Through the failsafe section of screening algorithm an IRT > 99.9 percentile is rated screening positive and conformation diagnostic (Sweat Test) is initiated without any further (e.g. Genetic) testing.

We present the case of a boy with positive CF newborn screening through the failsafe section, but 2 negative sweat tests carried out at 3 weeks and 5 months of age. At 3 years he presented in our hospital with characteristic CF symptoms, e.g. Fatty Stools, for at least 2 years. Sweat test was now pathological, MR imaging showed signs of pulmonary consolidation and bronchiectasis. Genetic diagnostic revealed a compound heterozygosity for CF.

All in all, if there are CF-suspicious symptoms the referral to a CF center and advanced diagnostics are indicated. Furthermore, it is to discuss whether the failsafe arm of German CF newborn screening should be complemented by genetic testing.

Received: Apr 23, 2021

Accepted: May 12, 2021

Published Online: May 13, 2021

Journal: Annals of Pediatrics

Publisher: MedDocs Publishers LLC

Online edition: <http://meddocsonline.org/>

Copyright: © Ballmann M (2021). *This Article is distributed under the terms of Creative Commons Attribution 4.0 International License*

Keywords: CF newborn screening; False-negative results in conformation diagnostics; Rare CF mutation; Late diagnosis.

Introduction

We present the case of a boy with positive newborn screening and 2 negative sweat tests carried out at 1 and 5 months of age. At 3 years he presented again with characteristic CF symptoms, recurring abdominal pain and fatty stools, starting in the first year of life.

Nationwide CF (cystic fibrosis) newborn screening in Germany was established in 2016 [1]. Through the failsafe section of the screening algorithm an IRT (immunoreactive trypsin) > 99.9 percentile is called "Screening Positive" and the newborn is sent to confirmation diagnostic (sweat test) without any other diagnostic test (Figure 1) [2].



Cite this article: Hildebrandt J, Keßler A, Hauenstein C, Müller C, Ballmann M. CF Newborn Screening Positive, Initial Repeated Sweat Test Negative, CF Anyways?. *Ann Pediatr.* 2021; 4(1): 1070.

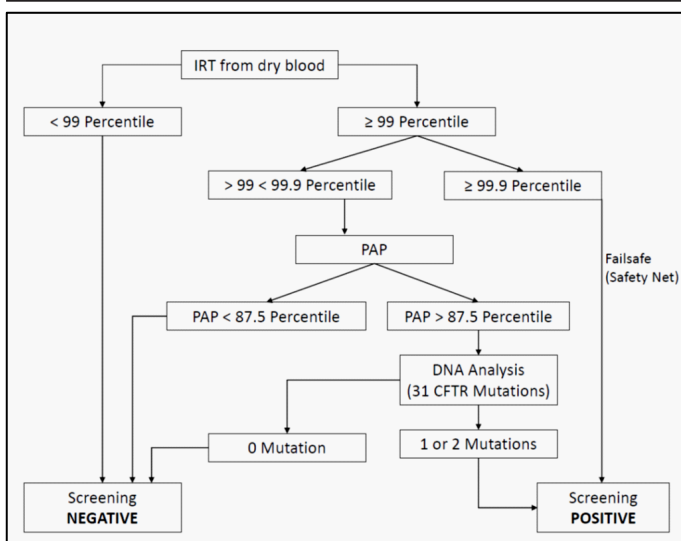


Table 1: German algorithm of Cystic Fibrosis Newborn Screening. Abbreviations: IRT: Immunoreactive Trypsin; PAP: Pancreatitis Associated Protein.

Case report

The patient first presented at our clinic at 1 month of age because of positive newborn screening for CF (IRT: 158.6 ng/ml (> 99.9 percentile), PAP (pancreatitis associated protein) (as additional determination): 6.3 ng/ml (Cut off 2,1 ng/ml)). Pregnancy, delivery and postnatal adaptation were without abnormalities. Two independent sweat tests were performed for conformation according to the failsafe arm of German diagnostic algorithm. Sweat test were carried out at the age of 3 weeks and 5 months. Results were within normal limits (chloride concentration of 19 mmol/L and 24 mmol/L in 20 µL sweat volume, respectively). Patient was sent back into family pediatrician's care.

At age 3 we saw a boy with long-lasting abdominal problems with fatty stools. Abdominal sonography revealed a chronically inflamed pancreas with an extended pancreatic duct. Yet the patient presented in good nutritional state (BMI z-score 0.94).

Further medical history included recurring partly febrile episodes of bronchitis in the past as well as one episode of pneumonia. However, there was no increased susceptibility to infection compared to peers.

The retake of sweat test was now pathological (chloride concentration 103 mmol/L in 45 µL sweat). Stool elastase was reduced (<15 µg/g). Blood work showed hypovitaminosis E and K. There were no signs of hepatopathy. MR imaging revealed pulmonary consolidation of the right inferior lobe and dorsobasal bronchiectasis. Bronchoalveolar lavage provided evidence of *H. influenzae* colonization, which was treated with antibiotics. After start of routine CF therapy including substitution of pancreatic enzymes gastrointestinal symptoms disappeared.

Genetic diagnostics were performed via preliminary sequencing of the CFTR gen (gen locus 7q31.2; reference transcript NM_000492.3) with subsequent sequencing of the accompanying intron/exon junctions of the CFTR-gen. Exon-overlapping deletions and duplications were analysed through MLPA (multiplex ligation-dependent probe amplification; MRC-Holland

Kit-Nr. P091-D2). Genetic diagnostics revealed a compound heterozygosity (het.c.1521_1523del; het.c.3000_3014del). While the 1st mutation is well-known, the 2nd is a mutation of unknown significance causing an in-frame deletion of 15 nucleotides and therefore does not cause a shift of the reading frame. There are only 2 listings in international data bases for this mutation [3,4]. Unfortunately, there was no further information on nutritional state and/or clinical manifestation or references of publication of these cases.

Discussion

We believe that sweat test results of the 1st and 5th month of life were real, since enough sweat volume was obtained and sweat tests were performed independently by two well-trained colleagues. Thus, a methodical error seems unlikely. Even in the CF-SPID (Cystic Fibrosis Screening Positive Inconclusive Disease) diagnostic algorithm, which was developed over the last couple of years, our patient would not have been diagnosed at first since the failsafe arm does not include genetic testing and sweat tests were within normal limit.

Question is whether we need to rethink follow up of positive NBS by failsafe only and repeated confirmation diagnostic. Although there was no increased susceptibility to pulmonary infections one could discuss that the patient should have been referred back to the CF centre for further diagnostics within the first year of life, when recurring abdominal symptoms and fatty stools indicated possible CF symptoms.

Further one can discuss whether this is a very rare mutation showing worsening sweat tests over time like Highsmith mutation [5]. Another CF causing mutation (e. g. in introns) is not excluded up to now, even if this is unlikely. There is a medical need to expand our knowledge about this rare second mutation.

Nevertheless, this case stresses the need for education of general paediatricians about the possible pitfalls of CF-newborn screening. Despite normal weight for his age this boy presented CF typical abdominal clinical signs (fatty stools, abdominal pain) over years before an ultrasound of the abdomen or CF diagnostic was initiated.

References

1. Richtlinie K. Richtlinie des gemeinsamen Bundesausschusses über die Früherkennung von Krankheiten bei Kindern (Kinder-Richtlinie). Gemeinsamer Bundesausschuss der Ärzte und Krankenkassen (G-BA). 2017.
2. Arbeitsgemeinschaft der Wissenschaftlichen Medizinischen Fachgesellschaften. S2k-Leitlinie: Neugeborenen-Screening auf angeborene Stoffwechselstörungen, Endokrinopathien, schwere kombinierte Immundefekte (SCID) und Mukoviszidose. 2019.
3. CFTR1, Cystic Fibrosis Mutation Database. 2001.
4. CFTR2 Clinical and Functional Translation of CFTR. 2011.
5. Highsmith WE, Burch LH, Zhou Z, Olsen JC, Boat TE, Spock A, et al. A novel mutation in the cystic fibrosis gene in patients with pulmonary disease but normal sweat chloride concentrations. *N Engl J Med.* 1994; 331: 974-980.