



Axillary Mass in Pediatric Age: Rare Case of Schwannoma of the Median Nerve

M Corain¹; M Giardini^{2*}; R Sartore²; G Zanette³; N Zampieri⁴

¹Director Hand Surgery and Microsurgery Unit, Verona University Hospital, Italy.

²Hand Surgery and Microsurgery Unit, Verona University Hospital, Italy.

³Department of Neurology, P.Pederzoli Hospital, Peschiera, Verona, Italy.

⁴Pediatric Surgery Unit, Verona University Hospital, Italy.

***Corresponding Author(s): Mattia Giardini**

Hand Surgery and Microsurgery Unit, Verona University Hospital, Verona, Italy.

Tel: 3466727374; Email: nicola.zampieri@univr.it &

nicola.zampieri@aovr.veneto.it

Abstract

Axillary fossa masses can be due to a very different kind of medical causes like lymphadenopathy, lymphomas, metastasis. Schwannoma is just one of these. We present a case of a median nerve Schwannoma in a pediatric patient that is a new clinical finding in literature.

A 15-year old male patient presented to his primary care physician with a palpable mass in his right axillary fossa. After an axillary ultrasound investigation, the pediatric oncohematologist confirmed the diagnosis of reactive lymphadenopathy; she suggested the lymph node removal and analysis. During surgical exploration a vascularized and roundish mass was identified; it was noted proximal and a distal peduncle so the mass was not removed. After surgery the patient was investigated with an axillary fossa MRI to understand the nature of the neoformation. According to clinical-anamnestic profile the image indicates the suspect of neurinoma that was removed and analyzed.

A lymph node abscess incision, biopsy or excision, in pediatric age, are usually suggested for common infections or in cases of antibiotics therapy unresponsive masses. Many different pathologic conditions can present as axillary masses) Awareness of the variety of these disease entities and characteristic sonographic findings can aid in correct diagnosis of an axillary mass.

Received: May 27, 2022

Accepted: Jun 28, 2022

Published Online: Jun 30, 2022

Journal: Annals of Pediatrics

Publisher: MedDocs Publishers LLC

Online edition: <http://meddocsonline.org/>

Copyright: © Giardini M (2022). *This Article is distributed under the terms of Creative Commons Attribution 4.0 International License*

Keywords: Schwannoma; Axillary mass; Pediatric.



Introduction

Axillary fossa masses can be due to a very different kind of medical causes like lymphadenopathy, lymphomas, metastasis. Schwannoma is just one of these.

Schwannomas, are a benign encapsulated tumor that grow in the peripheral nervous system. They develop in the nerve sheath from Schwann cell, giving the tumor its name. These tumors are more common in people between 20-50 years old, with no difference about sex or race [1,2]. These tumors usually appear as isolated lesions even though sometimes they can be related to neurofibromatosis and arise in multiple clusters [3]. Malignant transformation is rare [4]. They are found mostly in the head and in the neck (25%) or in the flexion surfaces of legs and arms, and only the 5% is in the axillary fossa [5]. It could take many years from the presentation to diagnose the mass. Because of its rarity, some cases can be missed or misdiagnosed, so it should be kept in consideration as one of the differential diagnosis about an axillary mass originating from a nerve branch [6].

In this report we describe an axillary mass, initially misdiagnosed as an axillary inflamed lymph node, that eventually resulted a median nerve schwannoma in a teenaged patient.

Case report

A 15-year old male patient presented to his primary care physician with a palpable mass in his right axillary fossa since for 4 months. No pain or other symptoms referred. He had no fever for more than 2 years, 2 kilos weight lost after a period of diet. Hematological exams were normal. Axillary ultrasound shown a lymphadenopathy of the axillary fossa with a node of about 30 mm and an altered echo structure (Figure 1).

A pediatric oncohematologist visited the patient and confirmed the diagnosis of reactive lymphadenopathy. She suggested a specialist pediatric surgical evaluation to consider the lymph node removal and analysis.

The patient underwent surgery: During surgical exploration a well vascularized and roundish mass was identified; it was noted proximal and a distal peduncle. Trying to dissect the vascular and nerval structures surgeons reported the flexion of the third finger of the right hand. Due to the suspect of a wrong diagnosis it was decided to stop the procedure and to add other diagnostic studies. The skin has been closed and the surgery was demanded. Patient parent were informed and agreed (Figure 2).

After surgery the patient was investigated with a right axillary fossa MRI and brain/encephalic trunk MRI to understand the nature of the neoformation and verify the eventual presence of any tumors. MRI refers: "Near to axillar vessels, there's a roundish formation with sharp edges, 23x19mm on the axial plan, 26mm on craniocaudal axis. According to clinical-anamnesic profile the image indicates the suspect of neurinoma. No other alterations were found in brain or in the encephalic trunk". The patient had a second sonographic examination performed by a specialist to investigate the ultrasound aspect of schwannomas. He was investigated with an EMG, no alteration in conduction were reported.

After this finding the case was taken over by the Hand Surgery and Microsurgery Dep.

The preoperative evaluation consisted of anamnesis, physical examination of the tumor, superficial sensory function testing (touch, pain, and static and dynamic sensory discrimination), muscle tone, and strength examination as well as testing for Hoffmann-Tinel sign. We managed to test the relation about the mass and the median nerve, so with flexion-extension movement of the elbow and the wrist (median nerve neurodynamic stretching) we could see the mass moving in the axillary fossa. The patient reported about some kind of sporadic and paroxysmal dysesthesia and paresthesia to the median nerve territory that he had never mentioned before (Figure 2).

The patient underwent a second surgery under general anesthesia. The incision was made directly on longest axis of the mass. The vessel were detected and protected, accurate hemostasis permitted to recognize the structures involved. We isolated proximally and distally the nerve branch and we protected the peduncles with surgical loops. The perinevrium has been incised keeping attention in its preservation. We dissect the adherent fascicula from the proximal pole of the tumor to the distal one. Once they were completely detached and the mass isolated, it was exited and sent for the histopathological examination. The nerve fascicle of the median branch were intact and only stretched and adapted to the capsuled mass; this macroscopic aspect oriented for a possible Schwannoma. Eventually we stitch the perinevrium and we applied human fibrin glue (Tissucol). The skin was closed with stitches, a soft bandage was made as medication. We allowed the patient to freely move the arm after 2 days since surgery. The scar has been treated with dedicate cream application for 2 months after surgery (Figure 3 & 4).

Histopathology confirmed the diagnosis of right axillary fossa schwannoma of the median nerve. Its section showed a tumor formed of benign-looking spindle cells with hypocellular areas. Immuno-histo-chemistry was positive for S100 and BC34. With no evidence of malignancy.

The postsurgical progress was regular, some mild neurological sensitive symptoms concerning the middle finger endured for the next three months after surgery and they were treated with neurotrophic (Palmitoilethanolamide - PEA) integration. At the 3 moths post-op check these symptoms completely disappeared.

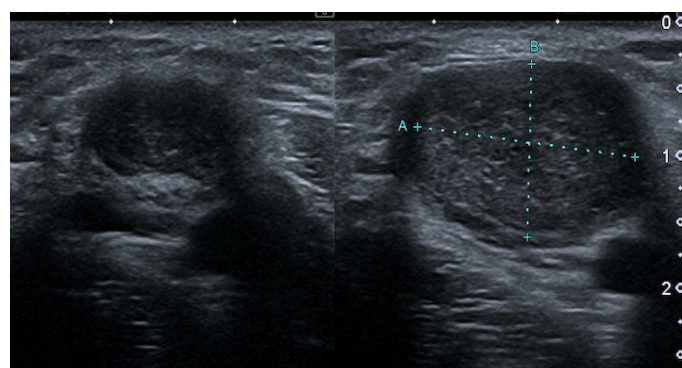


Figure 1: Sonographic appearance of axillary mass, this is the imaging of our patient at the first examination.

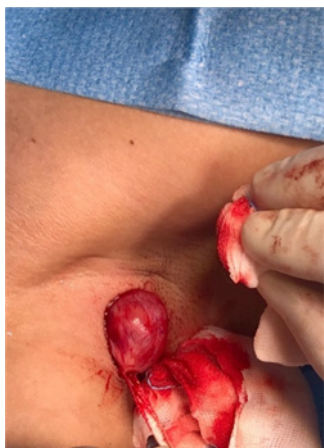

Figure 2: First surgery: Isolation of the mass with proximal and distal peduncle.

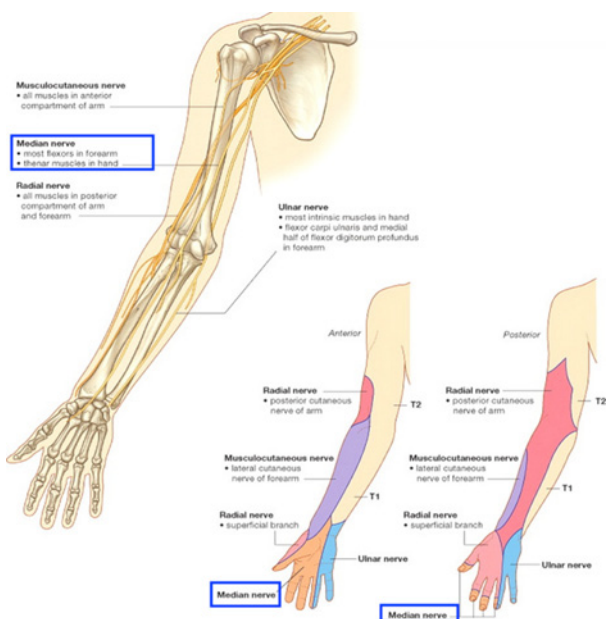


Figure 3: Median nerve course and innervation area.

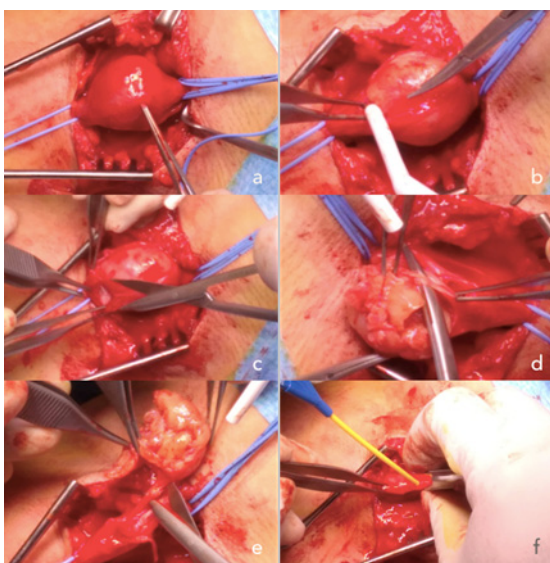


Figure 4: (a) Median nerve isolation; (b) Perinevrium incision; (c) Schwannoma's capsule incision; (d) Fascicula isolation; (e) Schwannoma excision; (f) Human fibrin glue application.

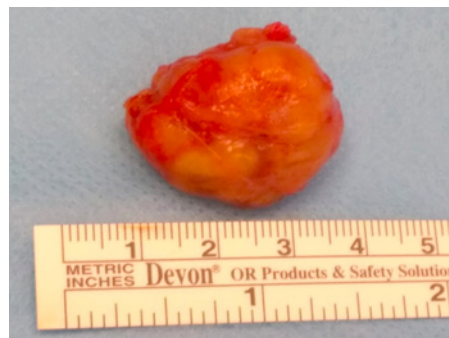


Figure 5: Excised schwannoma.

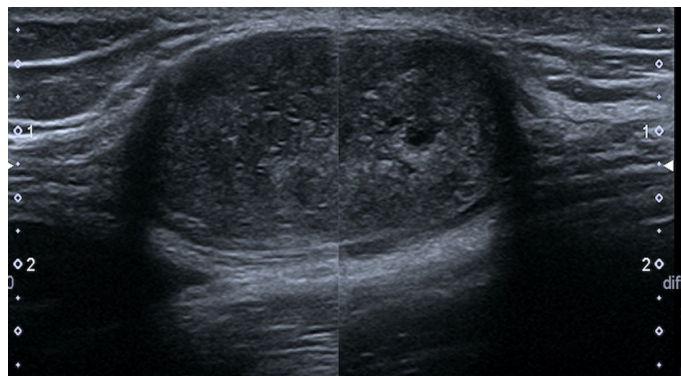


Figure 6: Sonographic imaging of Schwannoma associated to median nerve.

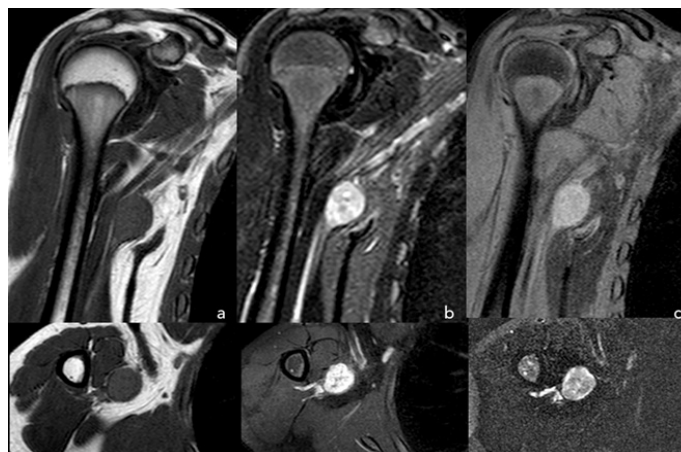


Figure 7: MRI appearance of axillary schwannoma of the patient. (a) T1-weighted; (b) T2-weighted; (c) STIR.

Discussion

A lymph node abscess incision, biopsy or excision, in pediatric age, are usually suggested by oncohematologists or by pediatricians for common infections or in cases of antibiotics therapy unresponsive masses.

Generally, neck, inguinal and axillary area are the most common surgical sites.

In pediatric age, without suspicious of neoplastic disease, ultrasound is the most common radiological test used; on ultrasound a normal lymph node has a hypoechoic cortex but often shows a central hyperechoic hilum containing fat and intranodal blood vessels referred to as a hilar line. The hilar line is more prominent in adolescents.

Many different pathologic conditions in addition to lymph node enlargement can present as axillary masses (fibroadenomas, hamartomas, fat necrosis, carcinomas, lipomas,

schwannomas). Awareness of the variety of these disease entities and characteristic sonographic findings can aid in correct diagnosis of an axillary mass [7].

Verocay described Schwannoma in 1908 as a slow-growing benign tumor of the sheath of peripheral nerves [8]. It is the most common peripheral nerve tumor. It affects mainly the head, the neck and the extremities. Axillary schwannomas are very uncommon as described in Gosk et al. study where were found just six cases of axillary schwannoma between all the patients treated for extremities schwannomas between 1985 and 2013 [9]. Only 10% of schwannomas are diagnosed in patients less than 21yo [10].

The patient presented is a 15yo young male with any risk factor for developing schwannoma during pediatric age. One of these is schwannomatosis [3] which arises the risk in developing multiple schwannomas during the second decade of life.

There are no other cases about an axillary median nerve schwannoma in a 15yo patient referred in literature.

We suggest to test the mass with upper limb and surrounding joints active and passive movements. If the mass moves in association with the stretching of the nerves it could indicate a nerve origin mass (Video1). Pain, Tinel test, muscular deficit or sensitive disturbs have to be considered.

The imaging diagnosis course of axillary mass should start with an US examination. Distinction of a nerve sheath tumors from abnormal lymph nodes may be difficult because abnormal lymph nodes could lose their hila and can exhibit posterior acoustic enhancement. However, the most reliable method to differentiate a lymph node from a nerve sheath tumor is the identification of the associated nerve [11] (Figure 5).

In presence of schwannoma sonography shows a well defined oval homogeneous hypoechoic mass with or without posterior enhancement [12]. Collagen deposit areas appear as a coarse echo texture or as focally increased echogenic areas. An echogenic ring within the mass is rare but a pathognomonic feature of nerve sheath tumors [13]. An echogenic capsule is usually seen, and cystic spaces represent the presence of degenerated portions of the mass. Sonography can provide confirmation of a neurovascular bundle adjacent to the mass [14]. In addition could be useful performing a sonoelastography in order to evaluate the elasticity of the lesion and to provide more information about its eventual growth pattern [15].

Diagnosis and classification of the tumor is challenging. Fine Needle Aspiration (FNA) could be a method even though it is difficult to recognize tissue architecture pattern [16]. A tru-cut [17] biopsy is another option for diagnosis as shown in a reported case of gastric schwannoma diagnosed using this procedure [18]. A new study published in the early 2020 by Roberto J. Perez Roman et al. affirm that benign tumors (namely schwannoma and neurofibroma) biopsy poses an unacceptably high risk for neurological deficit [19], changing the usual approach to the diagnosis.

The MRI can surely provide to visualize the anatomy of brachial plexus and the interrelated anatomic structures on relatively artifact-free images with a large field-of-view and can facilitate in better detection and characterization of the lesions. This is the gold standard for differential diagnosis.

On MRI [20], the tumor appears as a well-defined mass of intermediate signal intensity on T1-weighted images and as a

mass of high intensity on T2-weighted images, with an inhomogeneous central low-signal area and strong enhancement after contrast agent administration. On T2-weighted images, the peripheral hyperintense signal is due to the presence of myxoid tissue, and the central low signal intensity is due to the presence of fibrocollagenous tissue [21,22] (Figure 7).

The treatment for schwannoma of the brachial plexus is resection of the tumor [23].

The tumor is located eccentrically in the peripheral nerve and is well encapsulated by the perineurium. For this reason, it has generally been accepted that careful dissection under magnification could achieve complete enucleation without causing neurological deficit [24]. Different surgical techniques are described. In any case surgeons should attempt to perform a gross total resection of benign peripheral nerve sheath tumors without causing new neurological deficits. An ideal dissection plane can be identified between the pseudocapsule and true capsule [25]. Muramatsu et al. in their study show the advantages of the effective intracapsular enucleation using the microsurgery technique instead of extracapsular [26].

Conclusion

Axillary schwannoma is a very challenging condition itself, in terms of diagnosis and treatment. Everything becomes more difficult when it cares about a pediatric patient. Lymphadenopathy is of course the first option in case of axillary mass in young patients but as we seen it could not be the only possible diagnosis. Because of unspecific symptoms many cases could be mismanaged. It's very important to perform an accurate clinical exam, including Tinel sign and evaluating the relative motion of the mass correlate with the movement of the arm. US examination of the axilla fossa is the first step between the imaging exams but often it is not enough to identify the right nature of the mass. Considering the age of the patient an MRI and eventually a guided biopsy should be performed. Once made the definitive diagnosis the surgeon can perform and choose the best way to approach and remove the mass.

Statements

Statement of ethics

Conflict of interest statement: The Authors declare that they have no conflict of interest.

Statement of informed consent: Informed consent was obtained from individual legal guardian of the participant included in the study.

Statement of human and animal rights: All procedures followed were in accordance with the ethical standards of the responsible committee on human experimentation (institutional and national) and with the Helsinki Declaration of 1975, as revised in 2008.

Funding sources: The Authors received no financial support for the research, authorship, and/or publication of this article.

References

1. Lin J, Martel W. Cross-Sectional Imaging of Peripheral Nerve Sheath Tumors: Characteristic Signs on CT, MR Imaging, and Sonography. *Am J Roentgenol.* 2001; 176: 75-82.
2. Oi H, Watanabe Y, Shojaku H, Mizukoshi K. Nasal Septal Neurofibroma. *Acta Otolaryngol (Stockh).* 1993; 113: 151-154.

3. Gonzalvo A, Fowler A, Cook RJ, Little NS, Wheeler H, et al. Schwannomatosis, sporadic schwannomatosis, and familial schwannomatosis: a surgical series with long-term follow-up. *Journal of neurosurgery*. 2011; 114: 756-762.
4. Webb DE, Ward BB. Soft Tissue Tumors of the Neck. *Atlas Oral Maxillofac Surg Clin*. 2015; 23: 79-93.
5. Huang JH, Samadani U, Zager EL. Brachial Plexus Region Tumors: A Review of Their History, Classification, Surgical Management, and Outcomes: *Neurosurg Q*. 2003; 13: 151-161.
6. Roche P-H, Bouvier C, Chinot O, Figarella-Branger D. Genesis and Biology of Vestibular Schwannomas. In: Régis J, Roche P-H, eds. *Progress in Neurological Surgery*. Karger; 2008; 21: 24-31.
7. Kim EY, Ko EY, Han BK, Shin JH, Hahn SY, et al. Sonography of axillary masses: What should be considered other than the lymph nodes?. *Journal of Ultrasound in Medicine*. 2009; 28: 923-939.
8. FM Enzinger, SW Weiss. Benign tumors of peripheral nerves. In: *Soft Tissue Tumors*. Mosby, St. Louis; 1995: 4: 821-888.
9. Gosk J, Gutkowska O, Urban M, Wnukiewicz W, Reichert P, et al. Results of Surgical Treatment of Schwannomas Arising from Extremities. *BioMed Res Int*. 2015; 2015: 1-8.
10. Gaikwad N, Sathe NU, Wadkar G, Chiplunkar D. Schwannoma of the Cervical Vagus Nerve in a Child: A Case Report. *Indian J Otolaryngol Head Neck Surg*. 2013; 65: 188-191.
11. Sohn YM, Kim SY, Kim EK. Sonographic appearance of a schwannoma mimicking an axillary lymphadenopathy. *J Clin Ultrasound*. 2011; 39: 477-479.
12. Beggs I. Sonographic appearances of nerve tumors. *J Clin Ultrasound*. 1999; 363-368.
13. Beggs I. The ring sign: A new ultrasound sign of peripheral nerve tumours. *Clin Radiol*. 1998; 53: 849-850.
14. Beggs I. Pictorial review: Imaging of peripheral nerve tumours. *Clin Radiol*. 1997; 52: 8-17.
15. Hung CY, Chang KV, Chen PT, Ho YT, Han DS, et al. Sonoelastography for the evaluation of an axillary schwannoma in a case of quadrilateral space syndrome. *Clinical Imaging*. 2014; 38: 360-363.
16. Nikumbh DB, Janugade HB, Mali RK, Madan PS, Wader JV. Axillary schwannoma: Diagnosed on fine needle aspiration cytology. *Online Journal of Health and Allied Sciences*. 2011; 10.
17. Aref H, Abizeid GA. Axillary schwannoma, preoperative diagnosis on a tru-cut biopsy: Case report and literature review. *Int J Surg Case Rep*. 2018; 52: 49-53.
18. Hong SW, Cho WY, Kim JO, Chun CG, Shim KY, et al. Gastric schwannoma diagnosed by endoscopic ultrasonography-guided trucut biopsy. *Clinical endoscopy*. 2013; 46: 284-287.
19. Perez Roman RJ, Shelby Burks S, Debs L, Cajigas I, Levi AD. The Risk of Peripheral Nerve Tumor Biopsy in Suspected Benign Etiologies. *Neurosurgery*. 2020; 86: E326-E332.
20. Kichari JR, Hussain SM, Den Hollander JC, Krestin GP. MR imaging of the brachial plexus: Current imaging sequences, normal findings, and findings in a spectrum of focal lesions with MR-pathologic correlation. *Curr Probl Diagn Radiol*. 2003; 32: 88-101.
21. Suh JS, Abenzo P, Galloway HR, Everson LI, Griffiths HJ. Peripheral (extracranial) nerve tumors: correlation of MR imaging and histologic findings. *Radiology*. 1992; 183: 341-346.
22. Verstraete KL, Achten E, De Schepper A, Ramon F, Parizel P, et al. Nerve sheath tumors: evaluation with CT and MR imaging. *Journal belge de radiologie*. 1992; 75: 311-320.
23. Lusk MD, Kline DG, Garcia CA. Tumors of the brachial plexus. *Neurosurgery*. 1987; 21: 439-453.
24. Uchida K, Nakajima H, Sato R, Yayama T, Kobayashi S, et al. Microsurgical intraneural extracapsular resection of neurinoma around the cervical neuroforamen: A technical note. *minimally Invasive Neurosurgery*. 2009; 52: 271-274.
25. Stone JJ, Spinner RJ. Go for the Gold: A "Plane" and Simple Technique for Resecting Benign Peripheral Nerve Sheath Tumors. *Oper Neurosurg*. 2020; 18: 60-68.
26. Date R, Muramatsu K, Ihara K, Taguchi T. Advantages of intracapsular micro-enucleation of schwannoma arising from extremities. *Acta Neurochir (Wien)*. 2012; 154: 173-178.