



# Acute Onset of Dysphagia, Odynophagia, and Abdominal Pain in a 3 Year Old

Matthew Hwang<sup>1\*</sup>; Umair Iqbal<sup>2</sup>

<sup>1</sup>Department of pediatrics, University of Illinois, USA.

<sup>2</sup>Assistant Professor of Clinical Pediatrics University of Illinois at Peoria, pediatrics.

**\*Corresponding Author(s): Matthew Hwang**

Department of pediatrics, University of Illinois, USA.

Tel: 3156010258; Email: hwangmatt5@gmail.com

Received: Apr 09, 2022

Accepted: Apr 28, 2022

Published Online: May 02, 2022

Journal: Annals of Pediatrics

Publisher: MedDocs Publishers LLC

Online edition: <http://meddocsonline.org/>

Copyright: © Hwang M (2022). *This Article is distributed under the terms of Creative Commons Attribution 4.0 International License*

## Initial history and presentation

A 3-year-old immunized male with a history of prematurity at 34 weeks, asthma, elevated blood lead levels, and speech delay presented with an acute episode of drooling, grunting, and abdominal pain after waking up from a nap. He was taken to the emergency department as his respiratory distress worsened. His mother denied any recent illness, ingestion of caustic substance, trauma, or history of anaphylaxis. His dietary intake that day involved drinking a Carpi Sun juice box and eating Doritos chips, which were unwitnessed by any member of the family.

## Physical exam

Vitals: BP and heart rate were elevated at 120/67 and 135 bpm. He had a normal respiratory rate with no distress, with SpO<sub>2</sub> 100%. Exam showed copious secretions, a small non-bleeding abrasion on a non-deviated uvula, and < 2 cm laceration in the right mid oropharynx. The neck was supple without crepitus. Lungs were clear to auscultation, without wheezing. Belly was soft, with active bowel sounds, and without distention or tenderness to palpation.

## Diagnostic evaluation

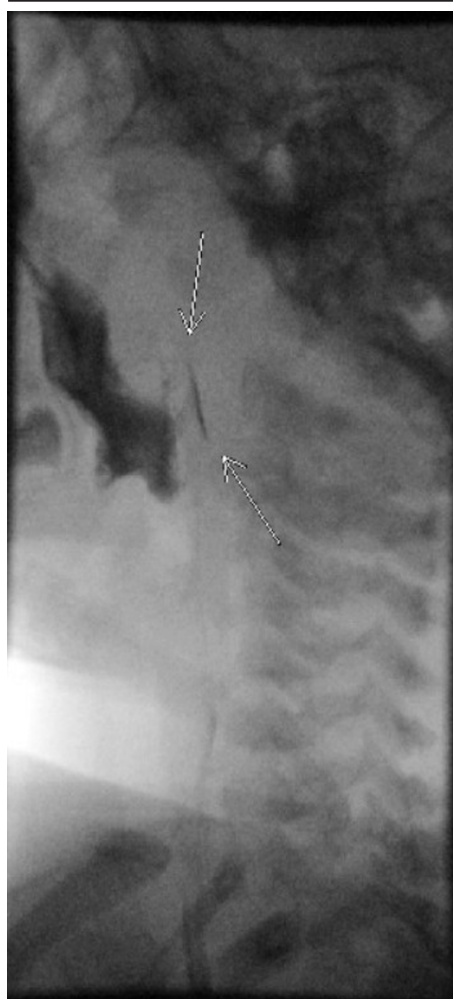CBC, CMP, and chest and abdominal X-rays were normal. Lateral soft tissue neck X-ray revealed retropharyngeal air with 1.1 cm of tissue thickening. CT showed gas tracking in the retropharyngeal space, without an abscess or a radiopaque foreign body. ENT surgeon recommended a Gastrografin esophagram, Unasyn for infection control, and Decadron to reduce swelling. Esophagram showed leakage of contrast only with thin barium, with persistent retropharyngeal soft tissue air. Due to improvement in respiratory distress, ENT surgeon chose medical management of the oropharyngeal perforation, with 72 hours of NPO status and IV hydration. Soft diet was initiated after repeat Gastrografin esophagram did not show extravasation of contrast in the retropharyngeal space.

## Diagnosis

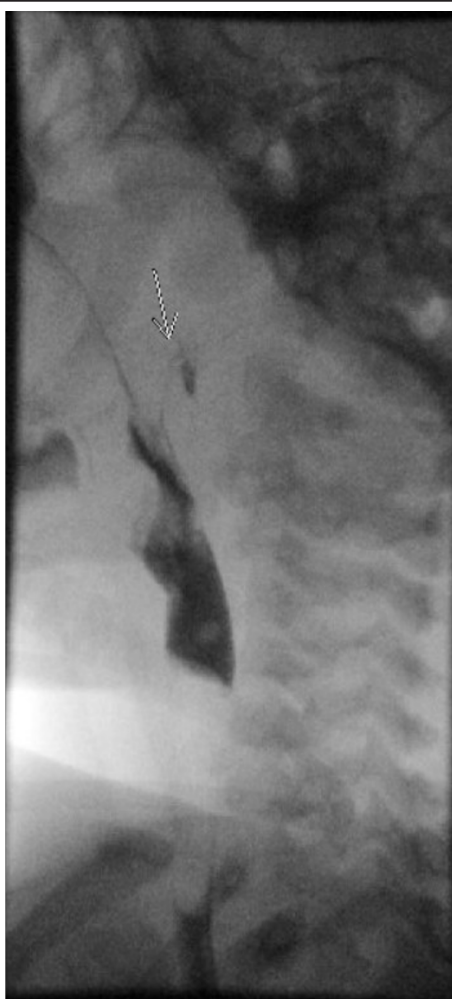Traumatic pharyngeal perforation from Doritos chips.



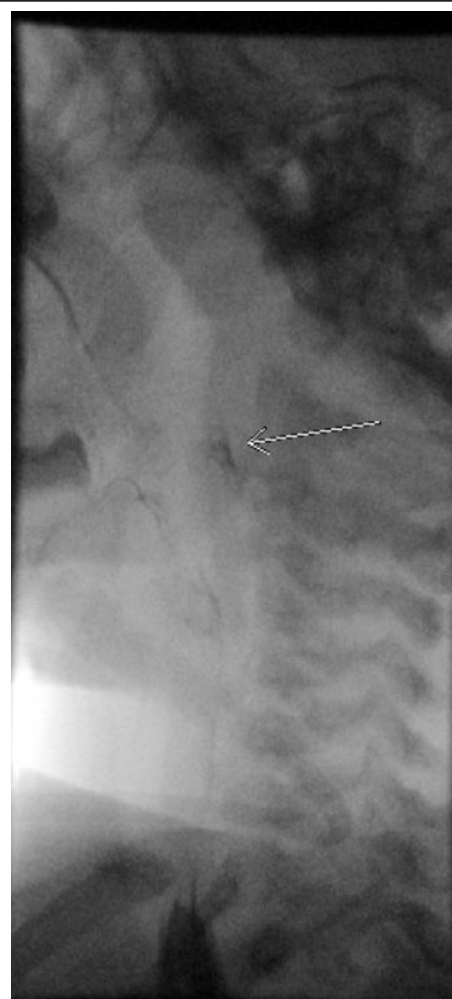
**Cite this article:** Hwang M, Iqbal U. Acute Onset of Dysphagia, Odynophagia, and Abdominal Pain in a 3 Year Old. *Ann Pediatr.* 2022; 5(1): 1097.



X-ray esophagram showing a small amount of contrast in the posterior pharyngeal wall and retropharyngeal soft tissues at the superior C1 level and inferior margin of the soft palate.



X-ray esophagram showing a small amount of contrast in the posterior pharyngeal wall and retropharyngeal soft tissues at the superior C1 level and inferior margin of the soft palate.



X-ray esophagram showing a small amount of contrast in the posterior pharyngeal wall and retropharyngeal soft tissues at the superior C1 level and inferior margin of the soft palate.

### Discussion/conclusion

The patient made a full recovery and was discharged on 10 days of antibiotics and 2 weeks of soft diet, devoid of sharp items like chips, peanuts, and popcorn. Esophageal perforations occur 3 in 100,000 in the US, with approximately 1/3 involving the cervical region frequently due to iatrogenic causes [1,2]. There is limited data in pediatrics. One case involved a 14-year-old with esophageal perforation from a Dorito chip leading to pneumomediastinum, requiring conservative management in the ICU [3]. Our case expands the differential for acute distress and dysphagia for children and demonstrates how history remains the hallmark of good clinical investigation.

### References

1. Kassem MM, Wallen JM. Esophageal Perforation and Tears. In: StatPearls. StatPearls Publishing. 2020. 2021.
2. White RK, Morris DM. Diagnosis and management of esophageal perforations. *Am Surg*. 1992; 58: 112-119.
3. Zahouani TS, Lopez R, Reynoso C, Ventura Y, Mendez M. Pneumomediastinum Secondary to Corn Chip Ingestion. *J Intensive Crit Care*. 2016; 2.