



# A Case of Reversible Obstructive Sleep Apnea with Treatment of Epiglottitis

Emily V Singer<sup>1\*</sup>; Kanika Bagai<sup>1</sup>; Lana Jeradeh Boursoulian<sup>2</sup>

<sup>1</sup>Department of Neurology, Vanderbilt University Medical Center, Nashville, TN, USA.

<sup>2</sup>Division of Pediatric Pulmonology, Department of Pediatrics, Vanderbilt University Medical Center, Nashville, TN, USA.

## \*Corresponding Author(s): Emily Singer

Department of Neurology, Vanderbilt University Medical Center, 1211 Medical Center Drive, Nashville, TN, 37232, USA.

Tel: 615-936-0060, Fax: 615-343-2589;

Email: Emily.v.singer@gmail.com

## Abstract

We present a reversible case of Obstructive Sleep Apnea (OSA), disseminated histoplasmosis with epiglottitis. The patient had resolution of OSA after treatment of the underlying upper airway infection. This case underlies the importance of recognizing reversible causes of OSA. It also reinforces the importance of repeating Polysomnogram (PSG) in certain settings.

Received: Feb 23, 2022

Accepted: Mar 10, 2022

Published Online: Mar 14, 2022

Journal: Annals of Pediatrics

Publisher: MedDocs Publishers LLC

Online edition: <http://meddocsonline.org/>

Copyright: © Singer E (2022). *This Article is distributed under the terms of Creative Commons Attribution 4.0 International License*

## Introduction

We describe the case of a 7-year-old immunocompromised boy with infectious epiglottitis and severe Obstructive Sleep Apnea (OSA) that completely resolved with treatment of his underlying infection. Upper airway pathologies of the epiglottis, such as cysts, have been reported in the literature to cause apnea or obstructive sleep apnea [1,2].

## Case presentation

A 7-year-old boy with history of maple syrup urine disease with subsequent liver failure requiring transplant and chronic immunosuppressants presented with acute onset snoring, hoarse voice, barking cough, and swelling of the neck. The

patient had a history of clinically diagnosed sleep-disordered breathing and was treated successfully with Tonsillectomy and Adenoidectomy (T&A) one year prior to presentation. After his surgery, the patient had resolution of OSA symptoms, including snoring and daytime sleepiness.

The patient was referred to the Emergency Department (ED) based on his symptoms of snoring, neck swelling, poor oral intake, and cough. His physical examination was remarkable for a normal body mass index of 14.7 kg/m<sup>2</sup>, temperature of 36.8 °C, pulse of 112, respiratory rate of 20, blood pressure of 109/72 and oxygen saturation of 99 %. He had hoarseness, which normalized after coughing. Oral exam revealed absent tonsils, clear pharynx, minimal neck adenopathy and two small aphthous ulcers in the posterior aspect of the palate.



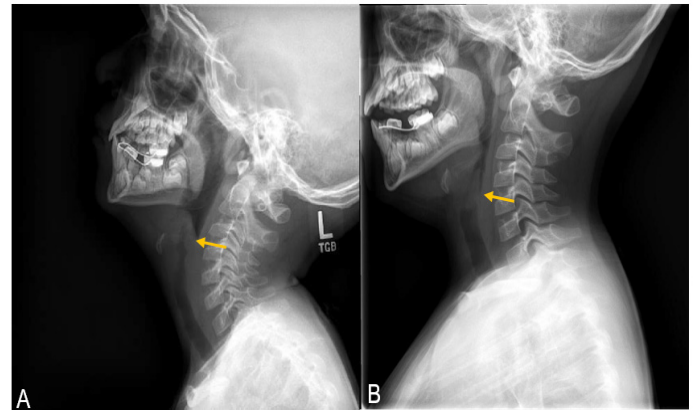
**Cite this article:** Singer EV, Bagai K, Boursoulian LJ. A Case of Reversible Obstructive Sleep Apnea with Treatment of Epiglottitis. *Ann Pediatr.* 2022; 5(1): 1092.

Lateral X-ray of the neck, soft tissue and larynx demonstrated subglottic tracheal narrowing and thickened aryepiglottic folds, presented in **Figure 1**. A CT soft tissue of the neck supported the diagnosis of epiglottitis. A CT of the chest showed lung nodules, calcified hilar nodes and calcified splenic lesions. Labs demonstrated a transaminitis with aspartate aminotransferase and alanine aminotransferase both elevated at 258 and 158, respectively. Direct laryngoscopy showed diffuse edema of the epiglottis, aryepiglottic folds, and left level II cervical lymphadenopathy.

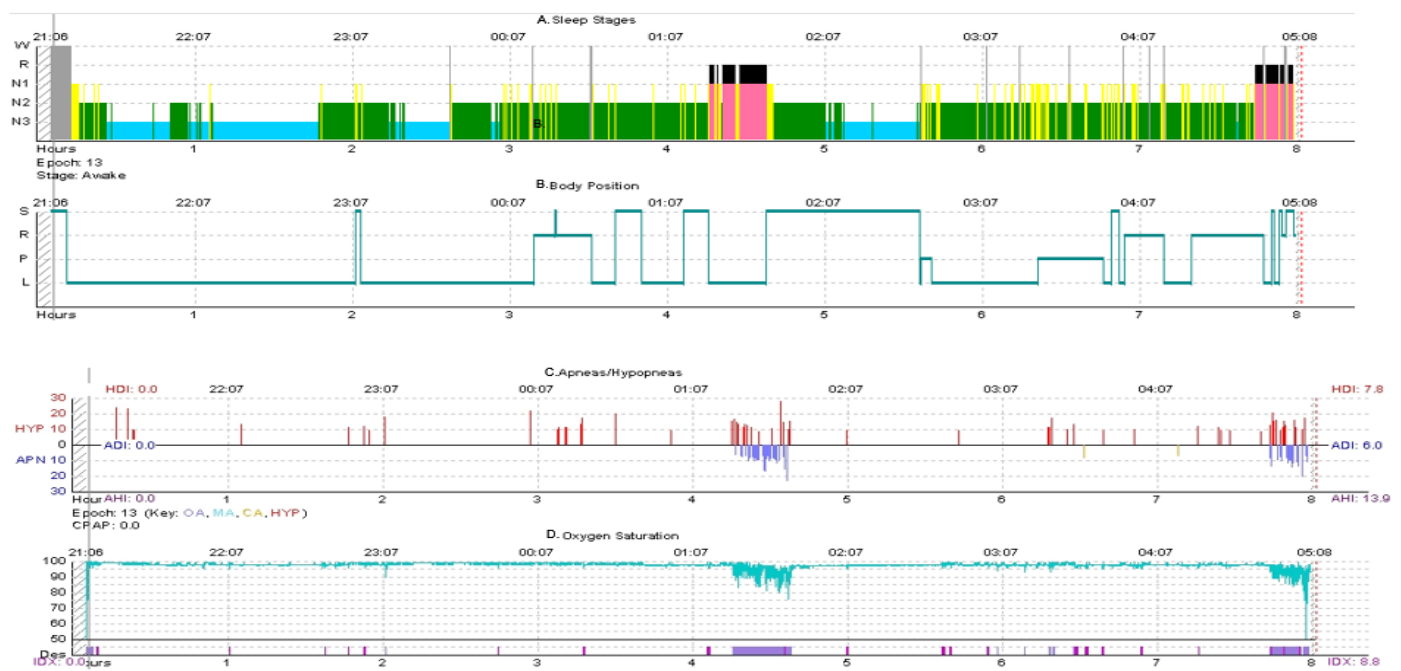
His airway was secured during direct laryngoscopy. He was kept intubated for 24 hours due to concern for airway compromise and started on Intravenous (IV) steroids. On day four of admission, histoplasma yeast antibody by complement fixation was positive at 1:32 (reference <1:8). He was started on amphotericin B for the treatment of disseminated histoplasmosis infection. He completed one week of amphotericin B prior to transitioning to itraconazole. With treatment, he had improvement in some of his symptoms, but was still snoring. He was discharged after two weeks to complete a prolonged course of itraconazole.

Two days after discharge, he had his first sleep study, which had been ordered prior to his admission. The in-laboratory overnight Polysomnogram (PSG) showed severe OSA, represented in **Table 1** and **Figure 2A**. The Apnea-Hypopnea Index (AHI) was 13.9 events/hr. Oxygen nadir was 75 %. The obstructive AHI was 13.6 events/hr. The REM AHI was 118 events/hr. He was seen by ENT and given a second course of steroids. No surgical intervention was done.

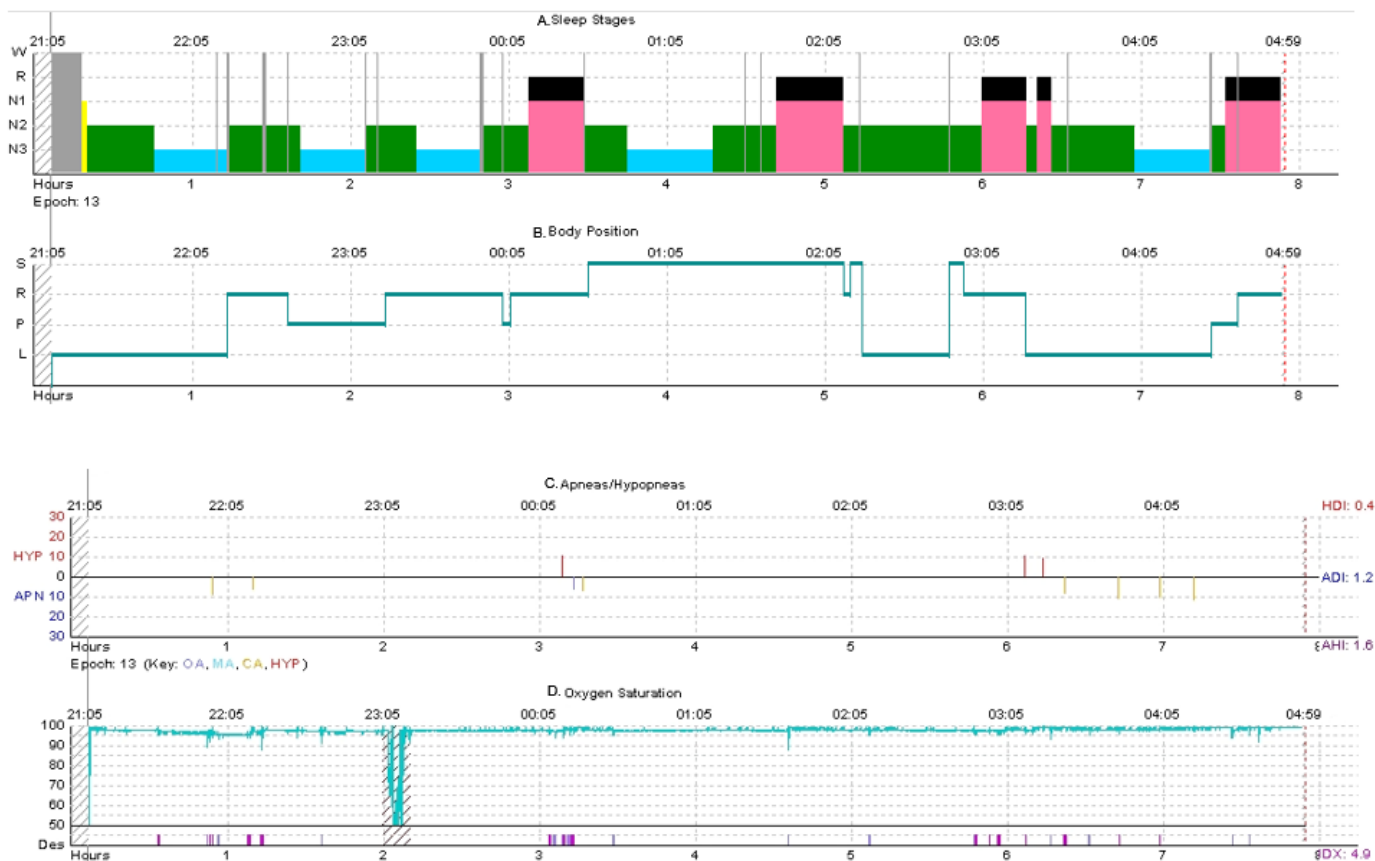
After six months on antifungal therapy, the patient’s mother reported significant improvement in snoring. A lateral neck and soft tissue X-Ray was obtained and demonstrated normal epiglottis appearance. Follow-up evaluation with an overnight PSG, represented in **Table 1** and **Figure 2B**, revealed minimal evidence for OSA, with rare hypopneas that were not associated with significant oxygen desaturations. The baseline AHI was 1.6 events/hr. The obstructive AHI was 0.5 events/hr. Minimum oxygen saturations during REM and NREM sleep were 94 and 89, respectively.



**Figure 1:** Lateral view soft tissue neck XR. **A)** Initial XR showing thickened aryepiglottic folds and mild distention of the pharynx (yellow arrow); **B)** Normal appearance of epiglottis six months after initial XR (yellow arrow).



**Figure 2:** Initial PSG Hypnograms. Arranged as follows: **A)** Sleep Stages - gray bar: Wake, yellow bar: N1 sleep, green bar: N2 sleep, blue bar: N3 sleep, pink/black bar: REM sleep; **B)** Body Position- S: Supine sleep, R: Right-side sleep, P: Prone sleep, L: Left-side sleep; **C)** Apnea/Hypopneas- red bar: Hypopnea, purple bar: Obstructive apnea, yellow bar: Central apnea; **D)** Oxygen Saturation- blue line: Oximetry signal; purple bar: Oxygen desaturations.



**Figure 2b:** Follow-up PSG Hypnograms.

Arranged as follows: **A)** Sleep Stages- gray bar: Wake, yellow bar: N1 sleep, green bar: N2 sleep, blue bar: N3 sleep, pink/black bar: REM sleep; **B)** Body Position- S: Supine sleep, R: Right-side sleep, P: Prone sleep, L: Left-side sleep; **C)** Apnea/Hypopneas- red bar: Hypopnea, purple bar: Obstructive apnea, yellow bar: Central apnea; **D)** Oxygen Saturation- blue line: Oximetry signal; purple bar: Oxygen desaturations.

**Table 1:** Comparison of Initial and Follow-up PSG.

PSG	TST (min)	SE (%)	Sleep Latency (min)	REM Latency (min)	AHI (events/hr)	Obstructive AHI (events/hr)	REM AHI (events/hr)	NREM AHI (events/hr)	Min O2 (%)	Time Spent <88%(min)
Initial PSG	459	97	8	243	13.9	13.6	118	6.7	75	5
Follow-up PSG	444	95	11	169	1.6	0.5	5	0.8	89	0

PSG: Overnight Polysomnogram; TST: Total Sleep Time; SE: Sleep Efficiency; AHI: Apnea-Hypopnea Index; Min O2: Minimum Oxygen Saturation.

**Discussion**

Pediatric OSA is the most common sleep disorder-affecting children with a prevalence of 1-5% [3]. OSA results from upper airway narrowing or increased upper airway collapsibility [4]. Unlike in adult OSA, pediatric OSA is most commonly attributed to adenotonsillar hypertrophy. However, many children with adenotonsillar hypertrophy do not have OSA and some children have persistent OSA despite undergoing T and A [5]. Therefore, adenotonsillar hypertrophy is not the only contributing factor in the development of pediatric OSA. These observations suggest an underlying predisposition to the development of OSA. Thus, children with a history of OSA, because of anatomical differences of their airway, may be at increased risk of redevelopment of OSA if additional factors are acquired.

Airway inflammation is also a contributor to the development of OSA. Children with a history of asthma, frequent viral infection or allergic rhinitis have increased proliferation of lymph tissue in the adenoids and tonsils [6]. In the upper air-

way, the oropharynx and nasopharynx are the most common sites of obstruction due to their semi rigid nature and resultant collapse. The hypopharynx, where the epiglottis is located, is comparatively more rigid and less prone to collapse [7]. Upper airway structural pathologies at the level of the epiglottis, such as cysts, have been reported in the literature to cause apnea or obstructive sleep apnea [1,2]. Because of this anatomical difference, the epiglottis may be an overlooked site for OSA. Our case demonstrates an infection causing airway obstruction below the level of the adenoids and tonsils.

It is known that children tend to have REM-related OSA. A study by Goh et al. found that children had 55% of their obstructive events during REM sleep even though REM sleep made up on 22% of their total sleep time [8]. This finding is thought to be related to decreased neuromuscular tone during REM sleep. Our patient had a particularly high REM AHI of 118 events/hr. This differed significantly from his NREM AHI of 6.7 events/hr. This is displayed in Table 1 and graphically in Figure 2A.

While fungal epiglottitis is certainly rare, this case underlies the importance of a thoughtful evaluation of the patient that has recurrence of OSA symptoms. Furthermore, it provides support that any acute upper airway symptom should be evaluated and visualized by ENT. In our patient, snoring was one of the first symptoms noticed that ultimately led to his diagnosis of disseminated histoplasmosis. Our case serves an important reminder that appropriate intervals for follow up and re-evaluation of OSA symptoms are necessary when there is severe OSA or ongoing symptoms of OSA to consider [9]. Our patient demonstrated severe OSA two weeks into his treatment for disseminated histoplasmosis but complete reversal of OSA after six months of treatment. We found obtaining a soft tissue neck XR to be helpful in determining sleep study timing. Our patient had the appearance of a normal epiglottitis in a follow up soft tissue neck XR obtained six months into treatment. This finding corresponded with resolution of his OSA on PSG. There are certain indications when follow up PSG is of particular importance including patients who present with severe OSA or those who develop recurrent symptoms.

## References

1. Dahm MC, Panning B, Lenarz T. Acute apnea caused by an epiglottic cyst. *International Journal of Pediatric Otorhinolaryngology*. 1998; 42: 271-276.
2. Picciotti PM, Agostino S, Galla S, Marca GD, Scarano E. Aryepiglottic fold cyst causing obstructive sleep apnea syndrome. *Sleep Medicine*. 2006; 7: 389.
3. Marcus CL, Moore RH, Rosen CL, Giordani B, Garetz SL, et al. A Randomized Trial of Adenotonsillectomy for Childhood Sleep Apnea. *New England Journal of Medicine*. 2013; 368: 2366-2376.
4. Dehlink E, Tan H-L. Update on paediatric obstructive sleep apnoea. *Journal of Thoracic Disease*. 2016; 8: 224-235.
5. Marcus CL, McColley SA, Carroll JL, Loughlin GM, Smith PL, et al. Upper airway collapsibility in children with obstructive sleep apnea syndrome. *Journal of Applied Physiology*. 1994; 77: 918-924.
6. Tauman R, Gozal D. Obstructive sleep apnea syndrome in children. *Expert Review of Respiratory Medicine*. 2011; 5: 425-440.
7. Kryger M, Roth T, Dement W. *Principles and Practice of Sleep Medicine* (6th edition). Saunders/Elsevier. 2011.
8. Goh DYT, Galster P, Marcus CL. Sleep Architecture and Respiratory Disturbances in Children with Obstructive Sleep Apnea. *American Journal of Respiratory and Critical Care Medicine*. 2000; 162: 682-686.
9. Aurora RN, Zak RS, Karipott A, Lamm CI, Morgenthaler TI, et al. Practice parameters for the respiratory indications for polysomnography in children. *Sleep*. 2011; 34: 379-388.