



4-Year-Old Girl with Abdominal Pain and Malnutrition

Eletra Vestri; Federica Bianchi; Nicola Zampieri; Simone Patanè; Francesco Saverio Camoglio*

Woman & Child Hospital, Department of Surgery, Dentistry, Paediatrics and Gynecology, Division of Pediatric Surgery, University of Verona, Italy.

***Corresponding Author(s): Federica Bianchi**

Pediatric surgical unit, Woman & Child Hospital,
Azienda Ospedaliera Universitaria Integrata Piazzale
Aristide Stefani 1, 37100, Verona, Italy.

Tel: +39-045-8127129;

Email: federica.bianchi1987@gmail.com &
FBianchix@santpau.cat

Received: Mar 03, 2021

Accepted: Mar 23, 2021

Published Online: Mar 25, 2021

Journal: Annals of Pediatrics

Publisher: MedDocs Publishers LLC

Online edition: <http://meddocsonline.org/>

Copyright: © Bianchi F (2021). *This Article is distributed under the terms of Creative Commons Attribution 4.0 International License*

Keywords: Subocclusion; Child; Lipomatosis.

Clinical image description

A 4-year-old patient presented with abdominal pain and intestinal sub-occlusion. On physical examination, she had an evident state of malnutrition, marked abdominal distention, non-tender abdomen with resistance to palpation, and two cutaneous lipomas. She underwent ultrasound evaluation, x-ray and Computed Tomography (CT) scan with evidence of a large mass occupying most of the abdominal cavity, from the retro-peritoneum to the anterior abdominal wall and displacing cranially the small intestine (Figure 1).

She underwent laparotomy with intraoperative finding of a massive lipoma embedded in transverse colon mesentery extending until its origin and into the retro-peritoneum, with hypertrophy of epiploic appendices on transverse, descending and sigmoid colon (Figure 2). The mass was then excised from the colon and the mesentery, with careful dissection along the inferior mesenteric artery. Abdominal lipoma had a weight over 1 kg. Skin lipomas were excised as well. Histological examination of the mass showed regular mature adipocytes without areas of necrosis and no mitoses.



Cite this article: Vestri E, Bianchi F, Zampieri N, Patanè S, Camoglio FS. 4-Year-Old Girl with Abdominal Pain and Malnutrition. *Ann Pediatr.* 2021; 4(1): 1063.

Final diagnosis was diffused lipomatosis, associated with general malnutrition and lipodystrophy. It is a rare pathology; in the literature only two similar cases are described in association with colonic polyposis in adult age [1,2]. At this time, the patient is in gastrointestinal and nutritional follow up.

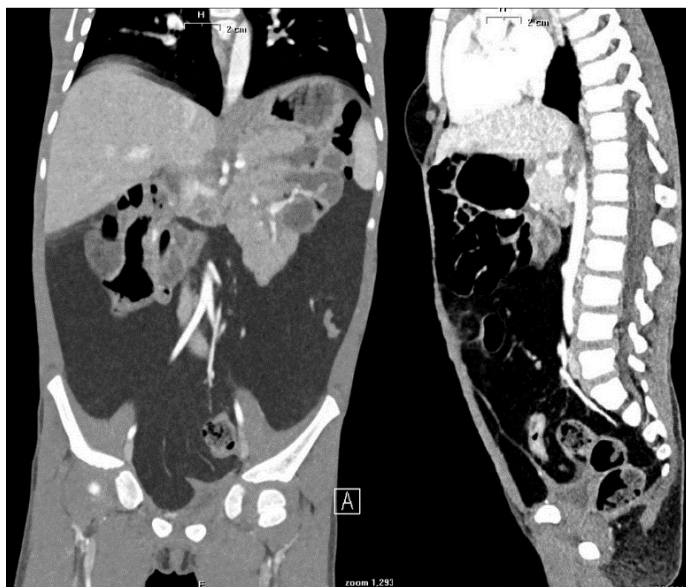


Figure 1: Abdominal CT scan - coronal and sagittal sections.

References

1. O'Connell DJ, Shaw DG, Swain VA. Epiploic lipomatosis and lipomatous polyposis of the colon. *Br J Radiol.* 1976; 49: 969-971.
2. Brouland JP, Poupard B, Nemeth J, Valleur P. Lipomatous polyposis of the colon with multiple lipomas of peritoneal folds and giant diverticulosis: report of a case. *Dis Colon Rectum.* 2000; 43:1767-1769.

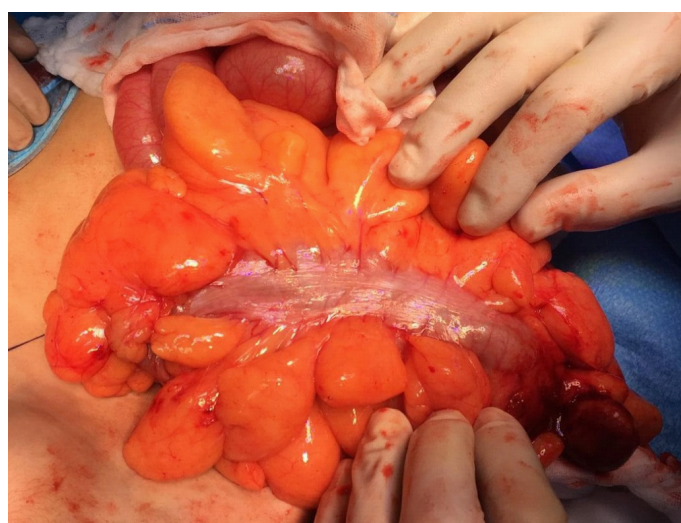
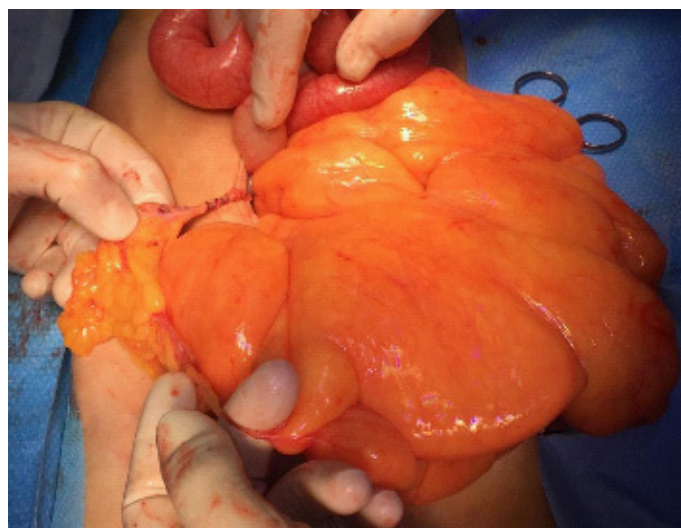


Figure 2: Intraoperative finding: Massive lipoma.