



# The 'Om' Sign

**Anubhav Chauhan\***; **Deepak Sharma**

Department of Ophthalmology, Shri Lal Bahadur Shastri Government Medical College and Hospital, Nerchowk, Distt. Mandi, Himachal Pradesh, India.

**\*Corresponding Author: Anubhav Chauhan**

Department of Ophthalmology, Shri Lal Bahadur Shastri Government Medical College and Hospital, Nerchowk, Distt. Mandi, Himachal Pradesh, India.

Tel: +91-9816991482;

Email: chauhan.anubhav2@gmail.com

Received: Jan 04, 2022

Accepted: Jan 31, 2022

Published Online: Feb 04, 2022

Journal: Annals of Ophthalmology and Visual Sciences

Publisher: MedDocs Publishers LLC

Online edition: <http://meddocsonline.org/>

Copyright: © Chauhan A (2022). *This Article is distributed under the terms of Creative Commons Attribution 4.0 International License*

## Introduction

A 65-year-old male came to our OPD for routine eye checkup. He had no ocular complaints. His history was uneventful. On examination, his best-corrected visual acuity was 6/6 in both the eye. Ocular movements, pupillary reaction, intraocular pressure and Colour vision were normal. Examination of the fundus of the left eye was within normal limits with a cup disc ratio of 0.3 while the right optic disc had a cup disc ratio of 0.7 with a vertically oval disc as well as the cup, baring of circumlinear blood vessels, loss of nasal neuroretinal rim and nasalization of vessels (Figure 1) which was highly suggestive of glaucoma in the right eye. The pattern of blood vessel in the optic disc gave quite a similar resemblance to 'OM'(Figure 1a) which is a sacred spiritual symbol in Indian religions. Further glaucomatous investigations were carried out and a diagnosis of primary open angle glaucoma was made.

The optic disk is vertically oval and the cup is horizontally oval thus the rim has a characteristic configuration where the Inferior (I) rim is the widest, followed by the Superior (S) and Nasal rims (N) and the Temporal (T) rim is the thinnest. This is the 'ISNT rule', which helps to determine the glaucomatous optic nerve head changes. The cardinal feature of glaucomatous optic neuropathy is the loss of NRR from the inner edge of the rim. The sequence of loss is usually first in the inferotemporal and superotemporal disk regions [1].

The paper being submitted has not been published, simultaneously submitted, or already accepted for publication elsewhere.

**Cite this article:** Chauhan A, Sharma D. The 'Om' Sign. Ann Ophthalmol Vis Sci. 2022; 5(1): 1024.



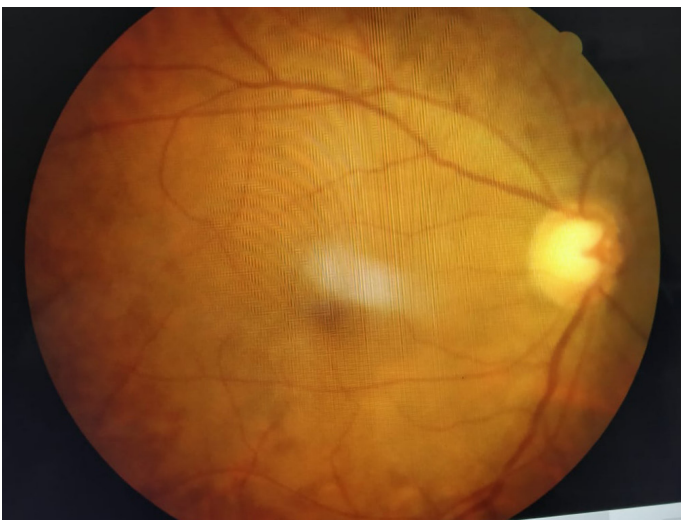

Figure 1

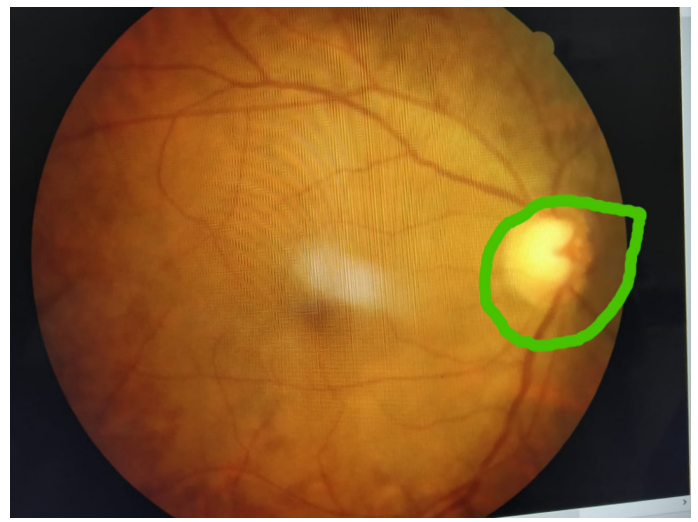


Figure 1a

### References

1. Gandhi M, Dubey S. Evaluation of the Optic Nerve Head in Glaucoma. *J Current Glau Prac.* 2013; 7: 106-114.