



# Ocular Chemical Burn Due to an Intentional Self-Administration of Bitter Melon Juice to Ocular Surface and Mini-Review of the Literature about the Traditional Eye Medication Related Ocular Burns

Ilayda Korkmaz; Seray Sahin; Ozlem Barut Selver\*

Ege University, Department of Ophthalmology, Izmir, Turkey.

**\*Corresponding Author: Ozlem Barut Selver**

Ege University Faculty of Medicine Department of Ophthalmology 35040 Bornova, Izmir, Turkey.

Fax: 90-232-390-37-87;

Email: Ozlem.barut.selver@yahoo.com

**Abstract**

**Purpose:** To report a case of ocular chemical burn caused by intentional topical self-administration of bitter melon (*Momordica charantia*) juice to treat presbyopia symptoms.

**Methods:** This is a case report and brief review of related literature

**Results:** A 45-year-old male presented with irritation, pain and discharge in the right eye after an intentional instillation of bitter melon juice in order to treat his new-onset of presbyopia symptoms. Best corrected visual acuity (BCVA) was 20/100 OD. Slit-lamp examination of the right eye revealed a 4x4 mm corneal epithelial defect in the central cornea without any stromal haze, conjunctival staining and limbal ischemia. Following copious irrigation with saline, topical antibiotic, corticosteroid and preservative-free artificial tears were initiated. Additionally, doxycycline and vitamin C were administered orally. After 4 weeks, the symptoms and the findings were completely resolved in the right eye. The final BCVA was 20/20 OU.

**Conclusion:** The use of traditional eye medication is common in developing countries. It may cause severe ocular chemical burn if not used with caution. Especially poorly educated individuals may suffer from such ineffective and dangerous treatment myths. To avoid further damage, off-the-counter home remedies should be restricted, public awareness and prevention strategies must be established.

Received: Dec 17, 2021

Accepted: Jan 15, 2022

Published Online: Jan 21, 2022

Journal: Annals of Ophthalmology and Visual Sciences

Publisher: MedDocs Publishers LLC

Online edition: <http://meddocsonline.org/>

Copyright: © Selver OB (2022). *This Article is distributed under the terms of Creative Commons Attribution 4.0 International License*

**Keywords:** Ocular chemical burn; traditional eye medication; Home remedies.

**Cite this article:** Korkmaz I, Sahin S, Selver OB. Ocular Chemical Burn Due to an Intentional Self-Administration of Bitter Melon Juice to Ocular Surface and Mini-Review of the Literature about the Traditional Eye Medication Related Ocular Burns. Ann Ophthalmol Vis Sci. 2022; 5(1): 1023.



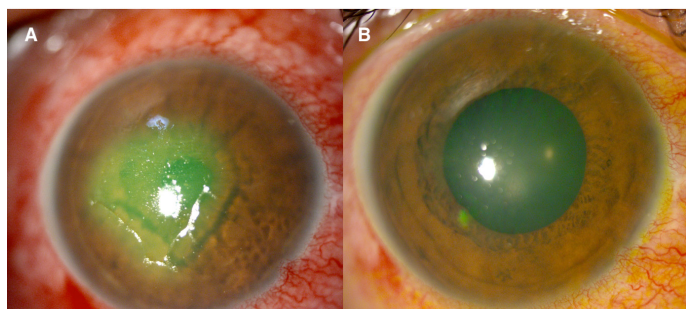
## Introduction

Chemical burn of the eye is an ocular emergency. Thus, immediate treatment is essential. Causative agent can be alkaline or acidic and the cause of the burn mostly accidental [1]. Rarely it occurs as a complication of intentional traditional eye medication usage [2]. There are only a few reports from undeveloped countries about the issue [2,3].

Hereby we aimed to report a case of ocular chemical burn caused by self-administration of bitter melon (*Momordica charantia*) juice to the ocular surface and to review similar previous reports about traditional eye medication related ocular chemical burn. To the best of our knowledge, ocular chemical burn caused by instillation of bitter melon has not been previously reported in the literature.

## Case presentation

A 45-year-old male presented with irritation, pain and discharge in the right eye. According to the patient's history, there was an intentional administration of a drop of bitter melon juice in his right eye half an hour ago, as a remedy for his new-onset presbyopia symptoms. The Best-Corrected Visual Acuity (BCVA) was 20/100 OD and 20/20 OS. The slit-lamp examination of the right eye revealed a 4x4 mm corneal epithelial defect in the central cornea. No stromal haze, conjunctival staining and limbal ischemia were observed. The severity of chemical burn was Grade 1 according to the Dua Classification. The slit-lamp examination and refractive status of the left eye were unremarkable. The fundus examination and intraocular pressures were within the normal limits in both eyes. Immediate management including copious irrigation with saline was performed. Subsequently, the affected eye was treated with a combination of topical 0.5% moxifloxacin (Vigamox, Alcon, US), 0.5% loteprednol etabonate (Lotemax, Bausch and Lomb, US) and preservative-free artificial tears 4 times a day and 1% cyclopentolate HCL (Sikloplejin, Abdi Ibrahim, Turkey) three times a day. Additionally, 100 mg doxycycline (Tetradox, Teva Ilac, Turkey) and 1000 mg vitamin C were administered orally. Pressure patching was also applied as a conservative treatment. The topical antibiotic and cyclopentolate HCL were discontinued when the epithelial defect was completely healed; the patient was examined daily during this period. The topical steroid was discontinued on the 7th day of the injury, restarted at the 3rd week and tapered according to the severity of inflammation. After 4 weeks, the symptoms and the findings were completely resolved with a clear cornea in the right eye (Figure 1). The final BCVA was 20/20 OU.



**Figure 1:** Anterior segment photographs of the right eye; (A) At presentation; 4x4 mm epithelial defect was present in the central cornea. (B) After 4 weeks, the ocular surface healed completely without any sequelae. The final BCVA was 20/20 OU with stable and quiet eye.

## Discussion

Ocular chemical burn is a significant public health problem that has a deleterious impact on visual acuity and quality of life. Exposure of the eye to a corrosive substance is usually caused by a home or work-related accident or criminal assault [1]. Ocular chemical burns due to accidental self-administration of the corrosive substance have also been reported earlier in the literature [4,5]. Blackburn et al., [1], in their study with 640 chemical eye injury patients, stated that 6% of chemical burns were caused by the instillation of chemicals to the eye by accident. It often occurs due to confusing non-ophthalmologic medications, which are stored in plastic dropper bottles, with eye drops [4].

Additionally, ocular chemical burns have been reported as intentional self-inflicted eye injuries. They are often associated with a variety of comorbidities, including psychological and neurological disorders [6].

Also, self-administration of eye drops without consulting an ophthalmologist is common in developing and undeveloped countries. Ajite et al., [3], reported the usage rate of traditional eye medication following ocular trauma as 45.8%. Beside the self-prescribed ophthalmic drops, homemade preparations are also significant part of such treatment modalities. Gupta et al., [7], in their population-based study with 2055 participants, reported that 25.7% of the study population used traditional eye medications, especially home remedies. This kind of usage can damage the ocular surface and may result in permanent ocular morbidity. Ocular chemical or thermal injury, corneal ulceration, corneal perforation and secondary suppurative keratitis are the most common causes of blindness associated with traditional eye medicine usage [2,3].

Although the most preferred home remedies vary by region, plant-based preparations constitute a significant part [7]. Eze et al., [8] reported that 37.7% of 149 patients used plant-based products as traditional eye medication. Aloe vera, palm oil, rose water, ginger juice, garlic, lemon juice, coconut oil, tea leaves and onion juice are some of the plant-based products that are frequently used in developing countries [7,8]. *Momordica charantia*, also known as bitter melon or bitter gourd, is an edible fruit which is consumed as a traditional medicine in Turkey. It consists of vitamins A and C, iron, polyphenolic compounds and alkaloids and is often used in the treatment of clinical conditions such as diabetes mellitus, gastrointestinal system diseases and respiratory diseases. It is also reported that the beta carotene in bitter melon fruit has a potential benefit on visual acuity [9]. However, it is considered a weak acid with a pH value of 4.33 and only oral administration is recommended [10].

In the presented case, the patient intentionally instilled bitter melon juice into his right eye as a traditional eye remedy to treat his new-onset presbyopia. Only one drop of the juice was sufficient to cause an ocular chemical burn. Fortunately, the severity of the burn was low, the appropriate and immediate treatment approach provided full recovery in the presented case.

## Conclusion

In conclusion, uncontrolled use of traditional eye medications may result in ocular surface damage and blindness. Especially poorly educated individuals may suffer from such ineffective and hazardous treatment myths. To avoid further damage, off-the-counter treatment options such as home remedies and plant-based products should be used with caution. Public awareness and preventive strategies must be developed to avoid such accidents caused by indigenous medications.

## References

- Blackburn J, Levitan EB, MacLennan PA, Owsley C, McGwin Jr G et al. The epidemiology of chemical eye injuries. *Curr Eye Res.* 2012; 37: 787-793.
- Foster A, Johnson GG. Traditional eye medicines-good or bad news? *Br J Ophthalmol.* 1994; 78: 807.

3. Ajite KO, Fadamiro OC. Prevalence of harmful/traditional medication use in traumatic eye injury. *Glob J Health Sci.* 2013; 5: 55-59.
4. Port A, Brissette A, Sippel K. A case of the blues: Inadvertent ocular injury from accidental instillation of blue ink. *Am J Ophthalmol Case Reports.* 2020; 19: 100773.
5. Carvalho RS, Kara-José N, Temporini ER, Kara-Junior N, Noma-Campos. Self-medication: initial treatments used by patients seen in an ophthalmologic emergency room. *Clinics (Sao Paulo).* 2009; 64: 735-741.
6. Patton N. Self-inflicted eye injuries: a review. *Eye (Lond).* 2004; 18: 867-872.
7. Gupta N, Vashist P, Tandon R, Gupta SK, Kalaivani M, et al. Use of traditional eye medicine and self-medication in rural India: A population-based study. *PLoS One.* 2017; 12: e0183461.
8. Eze BI, Chuka-Okosa CM, Uche JN. Traditional eye medicine use by newly presenting ophthalmic patients to a teaching hospital in south-eastern Nigeria: Socio-demographic and clinical correlates. *BMC Complement Altern Med.* 2009; 9: 40.
9. Kumar KPS, Bhowmik D. Traditional medicinal uses and therapeutic benefits of *Momordica charantia* Linn. *Int J Pharm Sci Rev Res.* 2010; 4: 23-28.
10. Siti Rashima R, Maizura M, Kang WM, Fazilah A, Tan LX. Influence of sodium chloride treatment and polysaccharides as debittering agent on the physicochemical properties, antioxidant capacity and sensory characteristics of bitter melon (*Momordica charantia*) juice. *J Food Sci Technol.* 2017; 54: 228-235.

