



# Cutaneous Metastasis of Esophageal Adenocarcinoma: A Rare Presentation and Diagnostic Challenge

**Naser Asfoor BA<sup>2\*</sup>; Mohamad Jabin BS<sup>3</sup>; Mojahed Mohammad K Shalabi MD<sup>1</sup>**

<sup>1</sup>Department of Internal Medicine, Baylor All Saints Fort Worth, Texas.

<sup>2</sup>University of North Texas Health Science Center- Texas College of Osteopathic Medicine, Fort Worth, TX.

<sup>3</sup>Texas A&M Health Science Center School of Medicine, Dallas, TX.

**\*Corresponding Author(s): Naser Asfoor**

University of North Texas Health Science Center-Texas  
College of Osteopathic Medicine, Fort Worth, TX.

Email: ngasfoor@yahoo.com & ngasfoor@gmail.com

Received: May 24, 2023

Accepted: June 09, 2023

Published Online: June 16, 2023

Journal: Annals of Oncology Case Reports

Publisher: MedDocs Publishers LLC

Online edition: <http://meddocsonline.org/>

Copyright: © Naser Asfoor BA (2023). *This Article is distributed under the terms of Creative Commons Attribution 4.0 International License*

## Abstract

Cutaneous metastases of internal malignancies are rare, but they can be the first sign of clinically silent visceral cancers, making it important for physicians to be vigilant in recognizing the possibility of visceral malignancies to the skin. Cutaneous metastases can have significant impacts on treatment, prognosis, and morbidity, with an average life expectancy of approximately 7.5 months. In this case study, a 68-year-old female presented with a hard nodule on her trunk, leading to the diagnosis of metastatic mucin-producing esophageal adenocarcinoma. The patient had a past medical history of basal cell carcinoma and was initially reassured by her primary care provider that the cyst was likely benign. The cyst continued to expand, and the patient presented with symptoms of dyspepsia and dysphagia, leading to a biopsy and the eventual diagnosis of metastatic adenocarcinoma. Esophageal adenocarcinoma has a low survival rate, and any cutaneous metastasis of cancer divulges an even poorer prognosis. When esophageal cancer is suspected, physicians should start with a thorough history and physical exam, followed by gastroenterology and oncology consultations, endoscopy and biopsy, and imaging for pre-treatment staging and evaluation. Patients with cutaneous manifestations of esophageal adenocarcinoma will likely be treated with neoadjuvant chemotherapy and radiation therapy, with a palliative care consult potentially indicated. This case study highlights the importance of considering esophageal adenocarcinoma in patients presenting with suspicious skin pathology, particularly those with risk factors such as family history, smoking, and alcohol consumption, as earlier detection can help mitigate patient well-being, prognosis, and management.



## Introduction

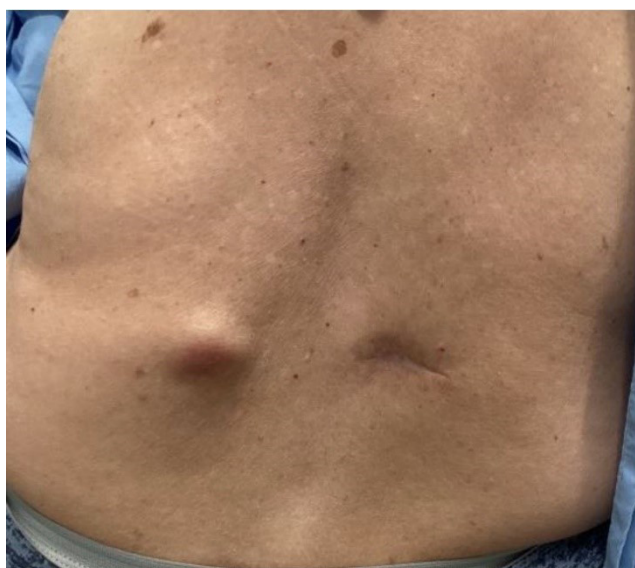
Cutaneous metastases of internal malignancies are very uncommon, occurring in only 0.5% to 9% of patients, with the incidence increasing as patients approach their seventh decade of life [1,2]. The most common internal malignancies that can present with cutaneous metastases are cancers of the breast, lungs, and intestines which account for 2% of all skin cancers [3]. Dermatologists and other physicians must be vigilant in recognizing the possibility of visceral malignancies to the skin as a delay or failure in diagnosis can have significant impacts on treatment, prognosis, and morbidity. Cutaneous manifestations may be the first sign of clinically silent visceral cancers [4]. Once these metastases are observed, the average life expectancy of patients is approximately 7.5 months [5].

We herein report an unusual case of a patient who presented with a hard nodule on the trunk, leading to the diagnosis of metastatic mucin-producing esophageal adenocarcinoma.

## Case presentation

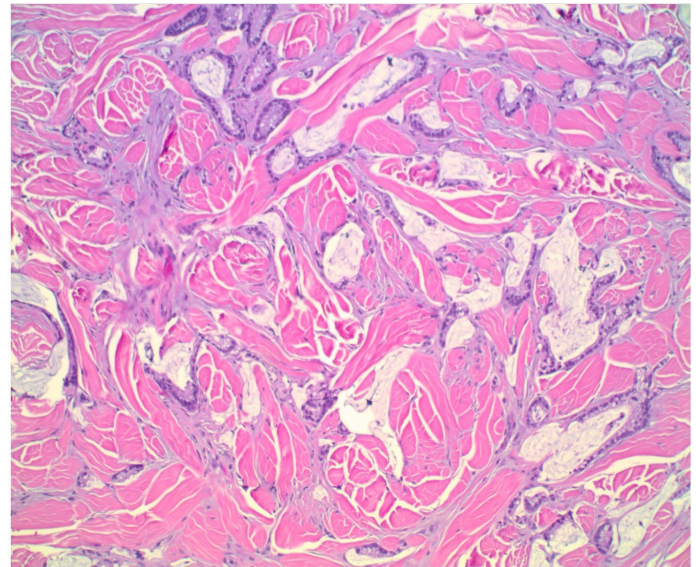
A 68-year-old Caucasian female with a past medical history of basal cell carcinoma that was removed in June 2022, presented as a new patient to establish care at a primary care clinic. At this time, she presented with no symptoms and was diagnosed with hypertension and hyperlipidemia. At her visit, the patient noted a barely visible but palpable cyst on her left lower medial back. Her Primary Care Provider (PCP) reassured her that this was most likely a benign finding. The cyst continued to expand and was referred to dermatology in September 2022 for incision and drainage; however, nothing was expressed from the cyst. She was placed on doxycycline due to erythema that developed around the lesion which had no effect on reducing the size of the cyst. In November of 2022, the patient presented to her PCP's office once more complaining of generalized fatigue, chest pain on exertion, and symptoms of dyspepsia and was placed on a proton pump inhibitor.

Due to the nature of the cutaneous lesion (Figure 1), the patient returned to the dermatology clinic in January of 2023 to undergo a biopsy. A few weeks after, the patient returned to her PCP with complaints of dysphagia and the sensation of "food getting stuck in her throat". Shortly thereafter, the pathology reports returned and showed evidence of metastatic mucin-

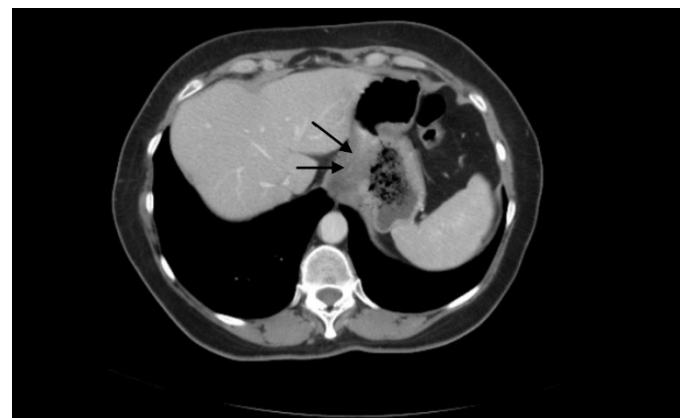

**Figure 1 Left:** Soft well demarcated nodule on the left lower lumbar region.

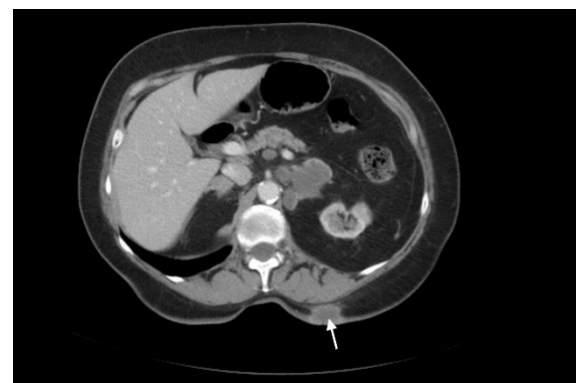producing adenocarcinoma (Figure 2). Immunohistochemical staining was positive for cytokeratin 7 & 20, CEA, and CDX2, but negative for GATA-3, all suggestive of upper GI tumor. Patient was sent for CT and endoscopy to locate the primary lesion, which was in the esophagus (Figure 3, 4).



**Figure 2 Right:** Metastatic mucin-producing adenocarcinoma, immunohistochemical staining was positive for cytokeratin 7&20, CEA, and CDX2, but negative for GATA-3.



**Figure 3 Top:** Large gastroesophageal mass measuring 5.6 x 3.6 x 6.9 cm, extending from the distal esophagus into the lesser curvature of the stomach.



**Figure 4 Bottom:** Soft tissue mass extending through the skin and subcutaneous adipose tissue in the left posterior upper abdomen measuring 3 x 1.8 x 2.3 cm.

## Discussion

Esophageal adenocarcinoma has a low survival rate, with only 20% of patients surviving beyond 5 years. Unfortunately, any cutaneous metastasis of a cancer divulges an even poorer prognosis [6]. When esophageal cancer is suspected, physicians should start with a thorough history and physical exam aiming at family history of cancer and focused questions on symptoms of dysphagia or weight loss. Consulting gastroenterology and oncology and obtaining endoscopy and biopsy of suspicious lesions falls next followed by imaging (CT/PET) for pretreatment staging and evaluation [7]. Patients such as the one herein described will likely be treated with a neoadjuvant chemotherapy regimen of oxaliplatin or ramucirumab and paclitaxel depending on immunohistochemistry markers, staining, and patient tolerance and later treatment with radiation therapy. A palliative care consult may also be indicated [8].

Skin metastases are an exceedingly rare presentation for any cancer with the most common primary sources being breast, malignant melanoma, the lung, and the colon in that order [9]. Normally, cutaneous metastases present as multiple skin nodules. This case was made even more challenging to diagnose by the appearance of only one known nodule which later turned erythematous, further complicating the differential.

## Conclusion

In this case study, we present a unique case of esophageal adenocarcinoma presenting with cutaneous manifestations. This is a rare presentation but should be kept in consideration for patients presenting with suspicious skin pathology with risk factors such as family history, smoking, alcohol consumption, etc. Earlier detection of esophageal adenocarcinoma can help mitigate patient well-being, prognosis, and management [10].

## References

1. Schwartz RA. Cutaneous metastatic disease. *J Am Acad Dermatol*. 1995; 33: 161-186.
2. Spencer PS, Helm TN. Skin metastases in cancer patients. *Cutis*. 1987; 39: 119-121.
3. Nashan D, Meiss F, Braun-Falco M, Reichenberger S. Cutaneous metastases from internal malignancies. *Dermatol Therapy*. 2010; 23: 567-580.
4. Lookingbill DP, Spangler N, Sexton FM. Skin involvement as the presenting sign of internal carcinoma. A retrospective study of 7316 cancer patients. *J Am Acad Dermatol*. 1990; 22: 19-26.
5. Saeed S, Keehn CA, Morgan MB. Cutaneous metastases: a clinical, pathological and immunohistochemical appraisal. *J Cutan Pathol*. 1994; 31: 419-430
6. Esophageal Cancer. National Cancer Institute. 2023.
7. Saltzman, JR. Clinical manifestations, diagnosis, and staging of esophageal cancer. In: Post TW, editors. In: UpToDate. Waltham, MA: UpToDate Inc. 2023.
8. Ajani JA, D Amico TA, Bentrem DJ, Chao J, Corvera C, et al. Esophageal and Esophagogastric Junction Cancers, Version 2.2019, NCCN Clinical Practice Guidelines in Oncology. *J Natl Compr Canc Netw*. 2019; 17: 855-883.
9. Neel VA, Sober AJ. Metastatic Tumors to the Skin. In: Kufe DW, Pollock RE, Weichselbaum RR, et al., editors. In: Holland-Frei Cancer Medicine. 6th edition. Hamilton (ON): BC Decker; 2003.
10. Triantafyllou S, Georgia D, Gavriella-Zoi V, Dimitrios M, Stulianos K, et al. Cutaneous metastases from esophageal adenocarcinoma. *Int Surg*. 2015; 100: 558-561.