



# Quadruplet Pregnancy Following Single Blastocyst Transfer

Olga Pavlidi<sup>1</sup>; Julia K Bosdou<sup>1</sup>; Polixeni Kyrou<sup>2</sup>; Alexandra Tokmakidou<sup>2</sup>; Angeliki Gerede<sup>3</sup>; Apostolos Athanasiadis<sup>3</sup>; Efstratios M Kolibianakis<sup>1\*</sup>

<sup>1</sup>Unit for Human Reproduction, 1st Department of Obstetrics and Gynecology, Medical School, Aristotle University of Thessaloniki, Greece

<sup>2</sup>FIVI fertility and IVF center, European Interbalkan Medical Center, Thessaloniki, Greece

<sup>3</sup>Third Department of Obstetrics and Gynaecology, Medical School, Aristotle University of Thessaloniki, Greece

## \*Corresponding Author(s): Efstratios M Kolibianakis

Unit for Human Reproduction, 1<sup>st</sup> Department of Obstetrics and Gynecology, Medical School, Aristotle University of Thessaloniki, Greece.  
Email: stratis.kolibianakis@gmail.com

## Abstract

**Purpose:** To report a monochorionic monoamniotic quadruplet pregnancy after frozen, single blastocyst transfer and Intracytoplasmic Sperm Injection (ICSI).

**Methods:** Case report of a 36-year-old woman with her husband aged 39 presented at the out-patient infertility clinic with a history of 4 years infertility, due to tubal factor and oligoasthenospermia.

**Results:** During ovarian stimulation, due to the high risk of developing ovarian hyperstimulation syndrome, final oocyte maturation was triggered with Gonadotrophin Releasing Hormone (GnRH) agonist and all embryos were frozen at the blastocyst stage. Frozen blastocyst transfer was performed, following preparation of endometrium with oral estrogens and progesterone, resulting in a positive pregnancy test. A vaginal scan at eight weeks of gestation revealed an intrauterine monochorionic monoamniotic quadruplet pregnancy which ended in miscarriage at nine weeks of gestation.

**Conclusion:** Monozygotic quadruplet pregnancy is possible after single blastocyst transfer. This is the first case report of a monochorionic monoamniotic quadruplet pregnancy following transfer of a single blastocyst.

Received: Oct 18, 2022

Accepted: Nov 03, 2022

Published Online: Nov 07, 2022

Journal: Annals of Obstetrics and Gynecology

Publisher: MedDocs Publishers LLC

Online edition: <http://meddocsonline.org/>

Copyright: © Kolibianakis EM (2022). *This Article is distributed under the terms of Creative Commons Attribution 4.0 International License*

**Keywords:** Monozygotic quadruplet; Pregnancy; Blastocyst; ICSI.

## Introduction

Monozygotic pregnancies can occur as a result of natural conception, however, they are far more frequent after assisted reproduction techniques (ART) [1]. Monozygotic pregnancies are considered as high-risk pregnancies due to increased inci-

dence of preterm birth, early pregnancy loss, congenital anomalies, growth restriction and perinatal death [2-5]. Possible maternal complications include pregnancy-induced hypertension, gestational diabetes, peripartum hemorrhage and operative delivery [6].



**Cite this article:** Pavlidi O, Bosdou JK, Kyrou P, Tokmakidou A, Gerede A, Athanasiadis A, Kolibianakis E M. Quadruplet pregnancy following single blastocyst transfer. *Ann Obstet Gynecol.* 2022; 5(2): 1040.

Factors, possibly associated with the incidence of monozygotic pregnancy following In Vitro Fertilization (IVF), include extended embryo culture, insemination method [conventional IVF and Intracytoplasmic Sperm Injection (ICSI)], embryo biopsy for Preimplantation Genetic Testing (PGT) for aneuploidies (PGT-A) or for monogenic/single-gene defects (PGT-M) programs, Assisted Hatching (AH), oocytes donation, female age and embryo cryopreservation [7]. In the past, several case reports have been published on high order multiple pregnancies. A case of quintuplet monochorionic diamniotic and a monochorionic triamniotic pregnancy in a 39 year old woman following transfer of two blastocysts was reported in 2004 [8]. Similarly, a monozygotic triplet and dizygotic twin pregnancy after IVF and embryo transfer of 3 poor quality cleavage stage embryos in a 29 year old woman was published in 2012 [9]. More recently, a quadruplet pregnancy, monochorionic diamniotic and dichorionic diamniotic, was reported in a 29 year old woman following transfer of two blastocysts after ICSI [10]. Additionally, Ota et al referred a case of a dichorionic triamniotic triplet pregnancy in a 32 year old woman after transfer of a single blastocyst in a frozen thawed cycle [11]. This is, however, the first case report of a monochorionic monoamniotic quadruplet pregnancy following transfer of a single blastocyst in a 35 year old woman who underwent ICSI.

### Case report

A 35 year old woman presented with her husband, aged 39 and smoker, at the infertility outpatient clinic, with primary infertility since 4 years due to oligoasthenospermia and tubal factor (presence of peritubal adhesions at hysterosalpingography). The female partner had regular menstruation (30-35 days) and a vaginal scan showed polycystic ovaries. Her Anti-Mullerian Hormone (AMH) level was 3.4 ng/ml and she was diagnosed with hypothyroidism, which was well-regulated with T4 oral intake. The couple underwent their first ICSI attempt at the FIVI Fertility and IVF Center - European Interbalkan Medical Center in August 2020. Informed consent has been obtained from the patient for this case report.

Ovarian stimulation was performed with a daily dose of 200 IU of recombinant Follicle Stimulating Hormone (FSH) (Gonal F, MERCK, Greece), while inhibition of premature Luteinizing Hormone (LH) surge was achieved using ganirelix acetate (Orgalutran MSD Greece), starting on day 5 of stimulation. Triggering of final oocyte maturation was performed with 0.2 mg triptorelin (Arvekap, IPSEN Pharma Biotech Greece) following nine days of stimulation due to the presence of high risk for developing ovarian hyperstimulation syndrome.

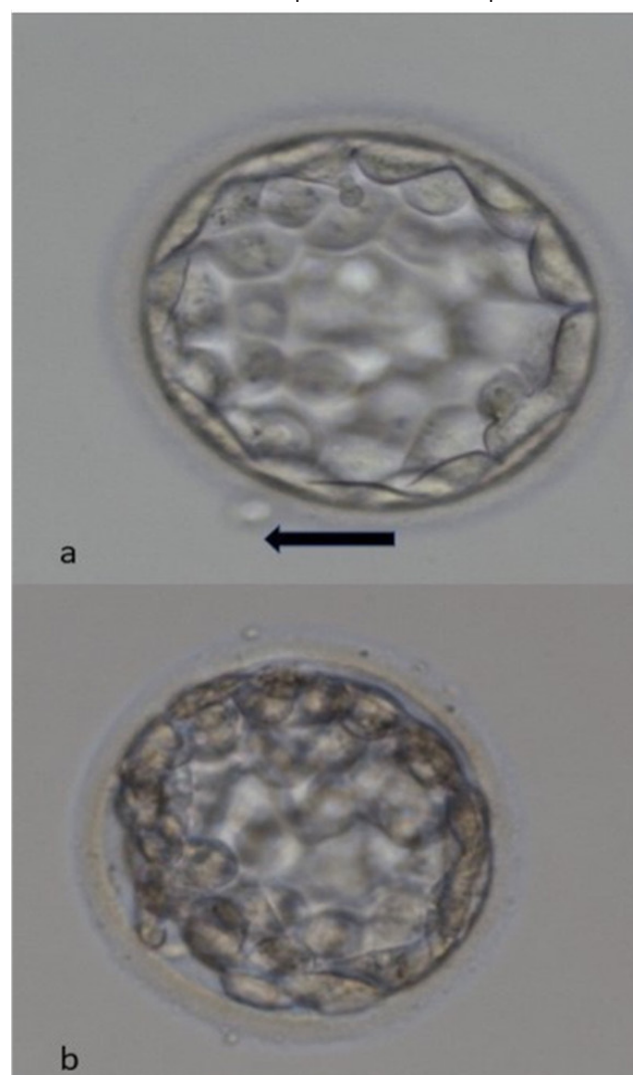
Twenty-one Cumulus-Oocyte Complexes (COCs) were retrieved and twenty Metaphase II (MII) oocytes were identified after cumulus removal with hyalase (IrvineScientific, FUJIFILM global). Regarding sperm morphology, an increased proportion of head and neck abnormalities was observed. Fertilization assessment the day after egg collection showed sixteen two-pronuclei oocytes and four one-pronuclei oocytes. Six out of sixteen of these normally fertilized oocytes had an oval/elongated shape. Ten blastocysts were cryopreserved five days after oocyte retrieval using the Cryotop vitrification method (Kitazato, Shizuoka-Japan).

Embryo culture was performed using continuous single culture complete with human serum albumin media (IrvineScientific, FUJIFILM global). Continuous Single Culture Complete (CSCM-C) media with Human Serum Albumin is a culture sys-

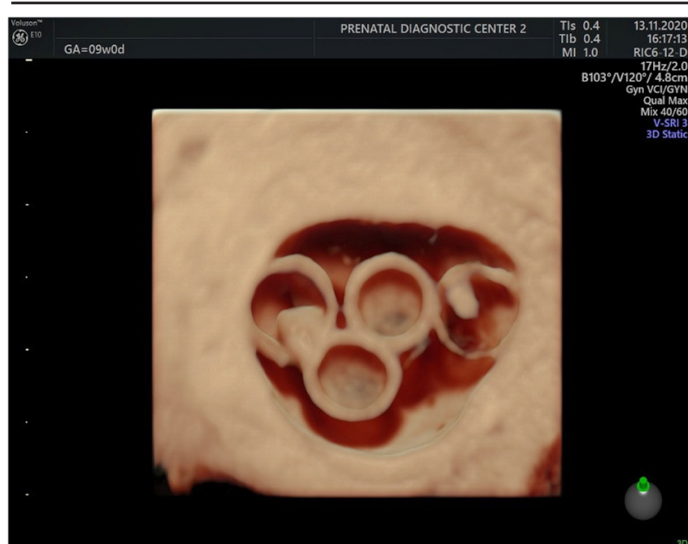
tem designed for fertilization and embryo culture through day 5/6 of embryo development. This medium is optimized to be used in an uninterrupted culture system without dish change or medium renewal. The media are pre-supplemented with HSA for a final total protein concentration of 5 mg/ml.

Following menstruation, preparation of endometrium for frozen-thawed blastocyst transfer was performed using oral estrogens (Cyclacur, Bayer Greece) and subcutaneous progesterone (Prolutex, IBSA Italy). On the sixth day after progesterone initiation, a single Grade AA expanded blastocyst was transferred in the uterus (**Figure 1b**). Prior to freezing, the blastocyst was characterized as Grade AA spontaneously hatching blastocyst and originated from one of the oval shaped oocytes (**Figure 1a**).

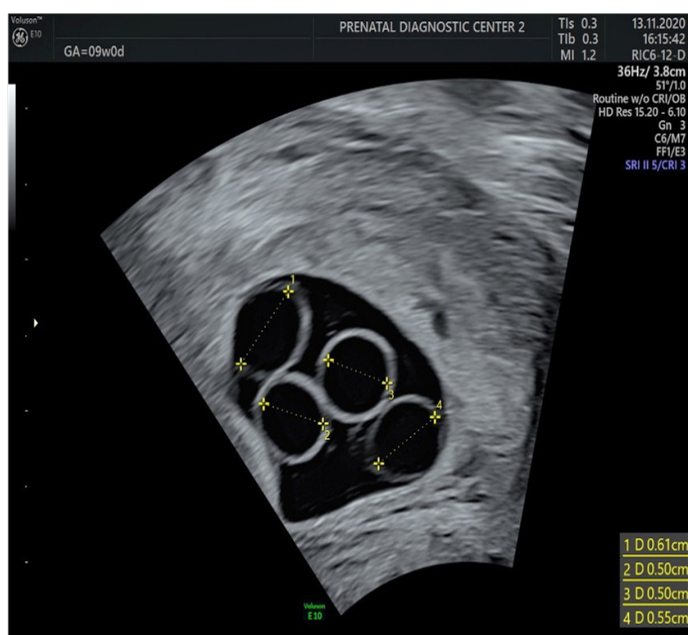
Following a positive pregnancy test,  $\beta$ -chorionic gonadotrophin levels increased normally and a transvaginal scan on the eighth week of gestation showed the presence of four yolk sacks and two fetal poles with fetal heartbeat present in both of them. A follow-up scan on the ninth week of gestation confirmed these findings, however, fetal heartbeat was not anymore detected (**Figures 2,3**). Subsequently, the patient underwent evacuation of retained products of conception.



**Figure 1:** Image of the grade AA hatching blastocyst prior to vitrification. The initiation of the hatching process is marked by an arrow. Image of the grade AA expanded blastocyst that was transferred in the uterus two hours after the warming process.



**Figure 2:** Four yolk sacs and two fetal poles with fetal heart-beat present in two of them at 9 weeks of gestation, following transfer of a single blastocyst.



**Figure 3:** Four yolk sacs at 9 weeks of gestation following transfer of a single blastocyst.

## Discussion

To our knowledge, this is the first report of a monozygotic quadruplet pregnancy resulting from a transfer of a single blastocyst after ICSI. Monozygotic pregnancies are rare, with an estimated incidence of monozygotic twinning after natural conception 0.45% of all births [12]. Their incidence, however, after assisted conception is 2.25 times higher [13].

Monozygotic multiple pregnancy occurs after embryo splitting into more than one embryos. A division on days 1-4 generates a dichorionic-diamniotic pregnancy. When the division occurs on days 4-8, it results in a monoamniotic dichorionic, while a division on days 8-12 results in a monoamniotic-monochorionic twin pregnancy [14].

In the current couple, four yolk sacs were identified after the transfer of a single blastocyst, indicating a quadruplet pregnancy (monozygotic monoamniotic). Yolk sac is an extraembryonic structure which provides nutritional, immunologic, metabolic,

endocrine and hematopoietic functions until the placental circulation is established [15]. It is visible when the gestational sac reaches 5 to 6 mm and is attached to the embryo via the vitelline duct [16]. Its size increases from the 5th until the 10th week of gestation [17]. In multiple monozygotic pregnancy, the number of yolk sacs does not define the number of amniotic sacs, especially in early pregnancy when it is hard to visualize. Therefore, it should be carefully examined after the 8th week of gestation [18-21].

Several factors have been associated with the occurrence of monozygotic multiple pregnancies, some of which are present and may have contributed to the occurrence of the quadruplet pregnancy in the current case report.

It has been suggested that monozygotic multiple pregnancy is associated with extended in-vitro culture, leading to embryo splitting [13,22]. This has also been confirmed in a subsequent meta-analysis [7], in which the risk of monozygotic pregnancy after transfer at the blastocyst stage was higher compared to transfer at the cleavage stage (OR 1.88; 95% CI: 1.54-2.30). Further support comes from a large retrospective analysis of frozen-thawed cycles, which showed a higher incidence of monozygotic twin pregnancy after transfer of a single blastocyst (n=7913) compared with the transfer of two cleavage embryos (n=13,004) (0.9% versus 2.3% respectively) [23]. It has been hypothesized that when an embryo is cultured for an extended amount of time in low calcium media, Inner Cell Mass (ICM) division can occur due to intercellular bond destabilization [14]. Moreover, extended culture appears to be associated with an excessive growth of ICM [24] or its disruption due to apoptosis. This might be explained by the generation of free radicals in culture medium in the absence of growth factors and the presence of high glucose content [14].

Artificially induced damage to the zona pellucida, as in the case of AH, may be also associated with inner cell mass splitting during hatching and herniating, resulting in monozygotic twinning in the human. This might be due to a premature disruption in the zona, interfering with signalling mechanisms within the embryo as well as due to the artificial hole created that might allow for blastomere separation and division [25].

Although a significant association between AH and monozygotic pregnancies after IVF has been shown in a recent meta-analysis (OR 1.17; 95% CI: 1.09-1.27) [7], this was not confirmed when analysis was limited to high-quality cohort (Newcastle-Ottawa scale score >7) and case control studies (random-effects model, OR 1.00; 95% CI: 0.81-1.24) [7]. Similarly, no association was shown between embryo biopsy for PGT-A and PGT-M and the incidence of monozygotic (OR 1.52; 95% CI: 0.76-3.02) [7].

Interestingly, in the same meta-analysis an increased risk of monozygotic pregnancy was present after conventional IVF as compared to ICSI (OR 1.13; 95% CI: 1.02-1.26). This finding, which remained constant even when analysis was limited to high-quality cohort (Newcastle-Ottawa scale score > 7) and case control studies (OR 1.14; 95% CI: 1.02-1.26) [7], suggests that oocyte manipulation is not associated with zygotic splitting.

Another factor that seems to contribute to the formation of monozygotic is female age [7]. A significantly higher risk for monozygotic twinning has been reported in women younger than 35 years of age (OR 1.29; 95% CI: 1.03-1.62), which might be associated with the fact that blastocyst transfer is more frequently performed in this age group. The risk, however,



for monozygotic monochorionic twinning after IVF is higher in women older than 35 years of age (OR 2.34; 95% CI: 1.69-3.23) [7]. This might be associated with a gradual reduction in the thickness of the Zona Pellucida (ZP) with increasing age that renders it more vulnerable to inner cell protrusion at multiple sites during zona lysis, facilitating in this way the division of the ICM [14].

The current case report shows that monozygotic quadruplet pregnancy after single blastocyst transfer is possible. Interestingly, extended embryo culture and transfer at the blastocyst stage, which were performed in the current case report, have been associated with monozygotic pregnancy. Moreover, although no assisted hatching took place, spontaneous hatching was initiated prior to freezing (**Figure 1.a**). On the other hand, fertilization was performed by ICSI, while female age was not advanced. Whether oval or irregular shaped oocytes are associated with the probability of monozygotic pregnancy needs to be further evaluated.

**Funding:** This research did not receive any specific grant from funding agencies in the public, commercial, or not-for-profit sectors.

**Conflict of interest:** No conflict of interest to declare.

## References

- Mateizel I, Santos-Ribeiro S, Done E, Van Landuyt L, Van de Velde H, et al. Do ARTs affect the incidence of monozygotic twinning? *Hum Reprod.* 2016; 31: 2435-2441.
- Hoskins RE. Zygosity as a risk factor for complications and outcomes of twin pregnancy. *Acta Genet Med Gemellol (Roma).* 1995; 44: 11-23.
- Layde PM, Erickson JD, Falek A, McCarthy BJ. Congenital malformation in twins. *Am J Hum Genet.* 1980; 32: 69-78.
- Grennert L, Persson PH, Gennser G, Gullberg B. Zygosity and intrauterine growth of twins. *Obstet Gynecol.* 1980; 55: 684-687.
- Sebire NJ, Snijders RJ, Hughes K, Sepulveda W, Nicolaides KH. The hidden mortality of monochorionic twin pregnancies. *Br J Obstet Gynaecol.* 1997; 104: 1203-1207.
- Chambers GM, Ledger W. The economic implications of multiple pregnancy following ART. *Semin Fetal Neonatal Med.* 2014; 19: 254-261.
- Busnelli A, Dallagiovanna C, Reschini M, Paffoni A, Fedele L, et al. Risk factors for monozygotic twinning after in vitro fertilization: a systematic review and meta-analysis. *Fertil Steril.* 2019; 111: 302-317.
- Zikopoulos K, Platteau P, Kolibianakis E, Albano C, Van Steirteghem A, et al. Quintuplet pregnancy following transfer of two blastocysts: Case report. *Hum Reprod.* 2004; 19: 325-327.
- Tal R, Fridman D, Grazi RV. Monozygotic Triplets and Dizygotic Twins following Transfer of Three Poor-Quality Cleavage Stage Embryos. *Case Rep Obstet Gynecol.* 2012; 2012: 763057.
- Calero Ruiz MM, Mangano Armada AI, Gutiérrez Romero JM, Torrejón Cardoso R. Quadruple pregnancy after post-IVF/ICSI transfer of blastocysts. *Rev Int Androl.* 2020; 18: 39-42.
- Ota K, Takahashi T, Katagiri M, Matsuoka R, Sekizawa A, et al. Successful monozygotic triplet pregnancy after a single blastocyst transfer following in vitro maturation of oocytes from a woman with polycystic ovary syndrome: a case report. *BMC Pregnancy Childbirth.* 2020; 20: 57.
- Derom C, Vlietinck R, Derom R, Van den Berghe H, Thiery M. Increased monozygotic twinning rate after ovulation induction. *Lancet.* 1987; 1: 1236-1238.
- Vitthala S, Gelbaya TA, Brison DR, Fitzgerald CT, Nardo LG. The risk of monozygotic twins after assisted reproductive technology: a systematic review and meta-analysis. *Hum Reprod Update.* 2009; 15: 45-55.
- Sobek A, Prochazka M, Klaskova E, Lubusky M, Pilka R. High incidence of monozygotic twinning in infertility treatment. *Biomed Pap Med Fac Univ Palacky Olomouc Czech Repub.* 2016; 160: 358-362.
- Lindsay DJ, Lovett IS, Lyons EA, Levi CS, Zheng XH, et al. Yolk sac diameter and shape at endovaginal US: predictors of pregnancy outcome in the first trimester. *Radiology.* 1992; 183: 115-118.
- Tan S, Pektas MK, Arslan H. Sonographic evaluation of the yolk sac. *J Ultrasound Med.* 2012; 31: 87-95.
- Nyberg DA, Mack LA, Harvey D, Wang K. Value of the yolk sac in evaluating early pregnancies. *J Ultrasound Med.* 1988; 7: 129-135.
- Corbett SL, Shmorgun D. Yolk sac number does not predict reliably amnionicity in monochorionic twin pregnancies: a case of a monochorionic monoamniotic twin pregnancy with two distinct yolk sacs on early first-trimester ultrasound. *Ultrasound Obstet Gynecol.* 2012; 39: 607-608.
- Park SY, Chung JH, Han YJ, Lee SW, Kim MY. Prediction of Amnionicity Using the Number of Yolk Sacs in Monochorionic Multifetal Pregnancy. *J Korean Med Sci.* 2017; 32: 2016-2020.
- Shen O, Samueloff A, Beller U, Rabinowitz R. Number of yolk sacs does not predict amnionicity in early first-trimester monochorionic multiple gestations. *Ultrasound Obstet Gynecol.* 2006; 27: 53-55.
- Doubilet PM, Benson CB, Bourne T, Blaivas M, Society of Radiologists in Ultrasound Multispecialty Panel on Early First Trimester Diagnosis of M, Exclusion of a Viable Intrauterine P, et al. Diagnostic criteria for nonviable pregnancy early in the first trimester. *N Engl J Med.* 2013; 369: 1443-1451.
- Behr B, Fisch JD, Racowsky C, Miller K, Pool TB, et al. Blastocyst-ET and monozygotic twinning. *J Assist Reprod Genet.* 2000; 17: 349-351.
- Long X, Wang Y, Wu F, Li R, Chen L, et al. Pregnancy Outcomes of Single/Double Blastocysts and Cleavage Embryo Transfers: a Retrospective Cohort Study of 24,422 Frozen-Thawed Cycles. *Reprod Sci.* 2020; 27: 2271-2278.
- Scott L. The origin of monozygotic twinning. *Reprod Biomed Online.* 2002; 5: 276-284.
- Alikani M, Noyes N, Cohen J, Rosenwaks Z. Monozygotic twinning in the human is associated with the zona pellucida architecture. *Hum Reprod.* 1994; 9: 1318-1321.