



Pheochromocytoma During Pregnancy: Two Cases and Management Review

Rachel Bond¹; Thi Hoang Lan Nguyen¹; Florence Weber²; Michèle Mahone²; Isabelle Bourdeau¹; Ariane Godbout^{1*}

¹Endocrinology Division, Department of Medicine, Center de recherche du Center hospitalier de l'Université de Montréal (CR-CHUM), Montreal, Quebec, Canada.

²Internal Medicine Division, Department of Medicine, Center hospitalier de l'Université de Montréal (CHUM), Montreal, Quebec, Canada.

*Corresponding Author(s): Ariane Godbout

Endocrinology Division, Department of Medicine, Center de recherche du Center hospitalier de l'Université de Montréal (CR-CHUM), Hôtel-Dieu de Montréal, 1000 rue Saint-Denis, Pavillon Jeanne-Mance, 4th floor, Montreal (Québec), Canada, H2X 0C1.

Tel: 514-890-8444, Fax: 514-412-7365

Email: ariane.godbout.1@umontreal.ca

Abstract

Background: Unrecognized pheochromocytoma during pregnancy is associated with a high rate of maternal and fetal mortality.

Objective: To report 2 cases of pheochromocytoma managed during pregnancy and provide recommendations for clinicians based on the literature.

Case 1: A 21-year-old woman diagnosed at 16 Weeks of Gestation (WG) with high Blood Pressure (BP) and bilateral adrenal masses compatible with pheochromocytomas and von Hippel-Lindau syndrome. Bilateral adrenalectomy was performed with temporary normalization of BP. The patient later developed severe Pre-Eclampsia (PE) and delivered at 29 WG.

Case 2: A 24-year-old women was found to be pregnant after diagnosis of pheochromocytoma. Left adrenalectomy was performed at 17 WG. Labor was induced at 39 WG because of Pregnancy-Induced Hypertension (PIH).

Discussion: Uncontrolled high BP during early pregnancy caused by pheochromocytomas was likely responsible for the occurrence of PE/PIH, despite successful adrenalectomy in both patients. Preconception management and early pregnancy BP control is essential.

Received: Feb 28, 2021

Accepted: Mar 24, 2021

Published Online: Mar 26, 2021

Journal: Annals of Obstetrics and Gynecology

Publisher: MedDocs Publishers LLC

Online edition: <http://meddocsonline.org/>

Copyright: © Godbout A (2021). *This Article is distributed under the terms of Creative Commons Attribution 4.0 International License*

Introduction

Hypertensive disorders of pregnancy occur in 10% of pregnancies and are the leading causes of maternal and perinatal morbidity and mortality [1]. Pheochromocytoma, a rare cause of hypertension, can be mistaken for pre-eclampsia if presents during pregnancy [2] and is associated with a high mortality rate [3]. Early diagnosis and treatment of pheochromocytoma

with timely tumor resection and aggressive Blood Pressure (BP) control can improve outcomes [2,4]. We report 2 cases of pheochromocytoma managed during pregnancy as well as a literature review and management recommendations for pheochromocytoma during pregnancy.



Cite this article: Bond R, Nguyen THL, Weber F, Mahone M, Bourdeau I, Godbout A. Pheochromocytoma During Pregnancy: Two Cases and Management Review. *Ann Obstet Gynecol.* 2021; 4(1): 1025.

Case description

Case 1: A 21-year-old primiparous woman was diagnosed with high Blood Pressure (HBP) and bilateral adrenal masses at 16 Weeks of Gestation (WG). This adopted patient was not previously known to have HBP or diabetes mellitus. She was admitted to hospital with a BP attaining 190/130 mmHg and anti-hypertensive medication was introduced. She had no signs of pre-eclampsia, however Gestational Diabetes Mellitus (GDM) was diagnosed and insulin therapy was initiated. An Ultrasound (US) revealed 2 large adrenal masses, which were later confirmed on abdominal Magnetic Resonance Imaging (MRI) (left, 9.5 x 5.5 x 5.0 cm and right, 9.5 x 4.5 x 4.0 cm) (Figure 1). A complete work-up for secondary causes of HBP revealed high levels of urinary metanephrines, confirming the diagnosis of pheochromocytoma (Table 1). A low-dose dexamethasone suppression test was performed (despite known limitations of interpretation during pregnancy) and had a low result. therefore not suggestive of Cushing syndrome [5]. Ophthalmologic examination revealed a retinal hemangioma on the left optic nerve highly suggestive of Von Hippel-Lindau (VHL) syndrome, a diagnosis later confirmed by genetic testing.

Prazosin, an alpha-blocker, was introduced and titrated up to 4 mg five times per day, targeting a systolic BP of 100-110 mm Hg and a pulse of 70 bpm. Aggressive intravenous fluid hydration was started. Amlodipine 5 mg daily was added 14 days after optimal alpha-blockade. BP remained uncontrolled, with peak at 200/115 mmHg, therefore the patient was transferred to the Intensive Care Unit (ICU) and intravenous Labetalol was added. Bilateral adrenalectomy was performed by laparotomy within 48 hours of ICU admission (at 18 WG) without complication. Intravenous hydrocortisone was given for the procedure (100 mg loading dose followed by 50 mg every 6 hours). Pathologic analysis confirmed 2 large pheochromocytomas with low mitotic index and without atypical mitosis. GDM resolved post-operatively. The patient was discharged at 19 WG with replacement doses of hydrocortisone (15 mg in the morning, 10 mg at noon and 5 mg in the evening), and fludrocortisone at 0.05 mg per day. Despite the bilateral adrenalectomy, at 27 WG, her BP rose and she developed proteinuria, with a protein-to-creatinine ratio (PCR) of 0.061 g/mmol (normal \leq 0.04 g/mmol) without deterioration of kidney function. Fludrocortisone was stopped and hydrocortisone was slightly reduced to a total of 25 mg per day without signs or symptoms of adrenal insufficiency. Urinary collections for fractionated catecholamines and metanephrines at 19, 27 and 28 WG remained normal.

Delivery and perinatal care

The patient was re-hospitalized at 28 WG because of severe PE and fetal Intrauterine Growth Restriction (IUGR). An urgent cesarean section was performed under intravenous hydrocortisone coverage due to breech presentation and suspicion of fetal distress. A 1.08 kg baby girl was delivered at 29 6/7 WG with an Apgar score of 6, 8 and 9. The placenta showed congested vessels with advanced villous maturation and focal chorangioma-tous transformation. The newborn died at 25 days of life from necrotizing enterocolitis.

Long-term follow-up

BP normalized over the first year postpartum and all anti-hypertensives were stopped. Urinary collection and MRI (Table 1) showed no pheochromocytoma recurrence. Detailed work-up did not show any other stigmata of VHL syndrome. Genetic

testing demonstrated an intragenic mutation in the VHL gene (c.499C>T). Genetic counseling was offered to her only known living relative.

Long-term follow-up

BP normalized over the first year postpartum and all anti-hypertensives were stopped. Urinary collection and MRI (Table 1) showed no pheochromocytoma recurrence. Detailed work-up did not show any other stigmata of VHL syndrome. Genetic testing demonstrated an intragenic mutation in the VHL gene (c.499C>T). Genetic counseling was offered to her only known living relative.

Preconception care and subsequent pregnancy

Despite teaching on the importance of preconception care, a subsequent unplanned pregnancy was noted at 5 WG. She was 26-year-old at that time and was with a new partner. No signs of pheochromocytoma recurrence or hypertension were found. Early GDM was diagnosed and treated. Low dose aspirin, Calcium 500 mg daily and prophylactic dose Low Molecular Weight Heparin (LMWH) were started for PE prevention. Semi-urgent ophthalmologic examination was organized and the retinal hemangioma was stable, and cerebral and spinal MRI performed at fourth month of pregnancy were normal. Careful follow-up with a multidisciplinary team was performed. This second pregnancy progressed favorably without occurrence of PE, prematurity or low birth weight. The patient underwent elective repeat cesarean at term and delivered a healthy baby girl weighing 3,69 kg.

Case 2: A 24-year-old obese (BMI 40 kg/m²) and hypertensive woman, was referred for management of a left pheochromocytoma (Table 1). The diagnosis was made after discovering a left adrenal incidentaloma identified on a scan performed for unexplained anemia. She was known to have had HBP for the past 4 years. However, HBP was mild at 130-140/80 mm Hg and pulse at 100 bpm at first evaluation without medication. MRI showed a left adrenal mass of 3.7 cm. Prazosin was introduced and increased progressively to 1 mg 3 times per day. An unplanned pregnancy as well as GDM were diagnosed at 7 WG when she presented to the emergency room with nausea and vomiting less than 3 months after initial investigations. The patient underwent a successful left adrenalectomy by laparoscopy at 17 WG after medical optimization of BP with prazosin and bisoprolol. Post-operatively, BP and pulse normalized. Pathology reports confirmed presence of a pheochromocytoma with rare presence of mitosis and no necrosis.

Delivery and perinatal care

The rest of the pregnancy in this primiparous woman was uneventful with resolution of HBP and GDM. At 21 WG, BP gradually rose but stayed under 140/90 without medication and negative PE work-up until delivery. Labor was induced at 39 WG because of high BP (170/84) without PE. A healthy baby boy of 2.8 kg was delivered vaginally with Apgar score of 9-9-9.

Long-term follow-up

BP normalized postpartum. BP and urinary catecholamine and metanephrine levels remained normal over five years of follow-up (Table 1). MRI showed no recurrence of adrenal mass at the surgical site. Search for known germline genetic mutations (VHL, SDHB, SDHD and RET genes) did not show any mutations. No further pregnancy is desired.

Table 1: Biochemical testing in our subjects.

Endocrine tests	CASE 1			CASE 2		
	Before surgery (16WG)	1 week after surgery	2.5 years after surgery	Before surgery and pregnancy	10 months after surgery	5 years after surgery
24 hour urinary fractionated catecholamines and metanephrines (nmol/L)						
Norepinephrine <i>normal</i> < 440	13 916	319	69	2707	118	197
Epinephrine <i>normal</i> < 110	32	83	< 10	61	50	37
Normetanephrine <i>normal</i> < 240	18 620	251	88	1883	78	143
Metanephrine <i>normal</i> < 275	229	109	< 30	238	< 30	121
Dopamine <i>normal</i> < 2579	1671	1581	1025	1771	1897	1856
24 hour urinary cortisol (nmol) <i>normal</i> < 330	137	NA	NA	45	NA	NA
Morning cortisol after dexamethasone 1 mg suppression test (nmol/L)	92*	NA	NA	15	NA	NA

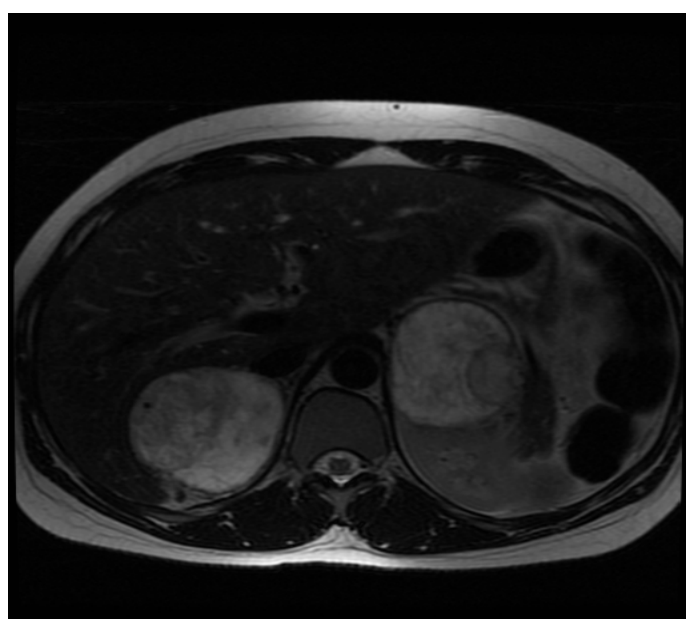


Figure 1: Bilateral adrenal masses at 17 WG (Case 1).

Discussion

Pheochromocytoma is an adrenal tumor originating from chromaffin cells, and accounts for 0.2% of hypertension cases. It has an estimated incidence of 1 in 50 000 pregnancies [6]. Approximately 25 to 35% of all pheochromocytomas and paragangliomas are associated with a hereditary syndrome such as VHL syndrome [7,8].

Presentation of pheochromocytoma during pregnancy often mimics PE [2,4]. Though rare, pheochromocytoma should be considered when severe HBP occurs before 20 WG or without proteinuria [2,4]. In our 2 cases, development of early GDM was another clue toward a diagnosis of pheochromocytoma, since elevated catecholamine levels are associated with hyperglycemia. A literature review was conducted and identified 56 other cases of early diagnosis of pheochromocytoma or paraganglioma in pregnancy (Figure 2), which are summarized below.

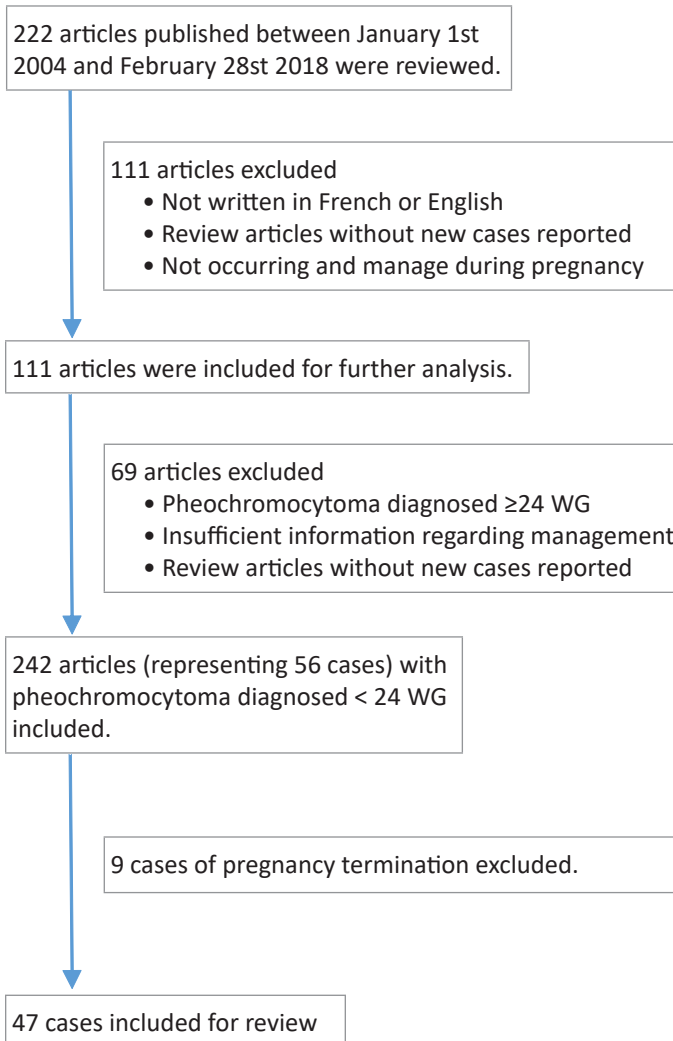


Figure 2: Algorithm for review- inclusion of cases.

Pubmed search terms included: « phaeochromocytoma » or « pheochromocytoma » or « paraganglioma » and « maternity » or « pregnancy » or « gestation » or « gravidity » or « pregnant women » or « gestational age » yielded 222 articles.

Management summary

Literature review and management

A systematic review in Pubmed of articles published between the periods of January 1st 2004 and February 28th 2018 using search terms « pheochromocytoma » or « pheochromocytoma » or « paraganglioma » and « maternity » or « pregnancy » or « gestation » or « gravidity » or « pregnant women » or « gestational age » yielded 222 articles. Only articles written in English or French, presenting new cases of pheochromocytoma/paraganglioma managed during pregnancy were included for review. A total of 111 articles were identified with new cases of pheochromocytoma/paraganglioma occurring during pregnancy. Furthermore, eligible publications presenting women with pheochromocytoma/paraganglioma diagnosed prior to 24 WG and reported management and outcomes were analysed. A total of 69 articles were excluded because pheochromocytoma or paraganglioma was diagnosed at \geq 24 WG, there was insufficient information concerning management or outcomes or they were review articles without presentation of new cases. Hence, 42 articles representing 56 cases were included.

Surgical management and outcomes

Among these cases, 9 (16%) underwent pregnancy termination with or without surgical resection of pheochromocytoma or paraganglioma and were not included in subsequent analysis [9-15]. Of the remaining, 32/47 cases (68%) underwent pheochromocytoma resection during the second trimester of pregnancy or up to 32 WG [4,12,13,16-40]. The majority of these women (25/32, 78%) had successful outcomes after surgery with early resolution of HBP, subsequent normal pregnancy with near-term delivery of healthy infants. There were two cases of preterm birth with elective cesarean being performed at 36 WG [4,27] and two cases of preterm birth with cesarean performed during bilateral adrenalectomy at 32 WG [17,35]. There were 3 cases of post-operative persistent HBP with subsequent adverse fetal outcome (jaundice) [32] including 2 cases of fetal death (1 IUFD [34], 1 neonatal death [21] (2/28, or 7%).

Medical management and outcomes

Fifteen patients (32%) were managed conservatively during pregnancy with alpha-blockade and other anti-hypertensive drugs, mainly beta-blockers and calcium blockers [4,17,40-49]. Maternal and fetal outcomes were less favorable with medical management compared to the surgical approach. With medical management alone there were 7 cases (50%) of preterm delivery [27,28,32,34,35,36 and 36 WG) [17,34,42,44,45,47,49] and 3 cases of unfavorable maternal outcomes (hypertensive crisis [44], hypertensive encephalopathy with disseminated intravascular coagulation and acute renal failure [4] and adrenal hemorrhage [46]) with 2 cases resulting in fetal death (2/12, or 16,7%) [4,44,46].

Management summary

Overall, including our 2 cases, 69% were managed surgically. No case of maternal mortality was reported and, 5/46 (11%) fetal deaths were noted. Among women treated with surgical resection of pheochromocytoma, there were two reports of PE complicating the course of pregnancy (case 1 above, [18]).

The most reliable diagnostic test for pheochromocytoma is plasma free or 24-hour urinary fractionated metanephrines measurement [50,51]. Results should not be altered during pregnancy and are only slightly elevated in patients with PE, making this a dependable method for diagnosis of pheochromocytoma in pregnancy [52]. However, it should be noted that no studies specifically examined the diagnostic accuracy of these tests in pregnant women. CT scan, the preferred imaging modality for adrenal masses, is not recommended in pregnancy and functional imaging with MIBG scintigraphy is contraindicated. MRI and US are the recommended imaging procedures during pregnancy, with MRI favored, due to higher sensitivity [3,4,50].

Aggressive treatment for rapid control of HBP is recommended to prevent maternal and fetal complications [1]. Alpha-blockers such as Phenoxybenzamine, Prazosin, Doxazosin and Terazosin are the preferred initial drugs for management of pheochromocytoma in pregnancy. Although class C medications [3,4,50], the benefits outweigh the potential fetal harm. Addition of beta-blockers and Calcium Channel Blockers (CCB) may be necessary after maximal alpha-blockade [52]. Magnesium sulfate may be added to inhibit catecholamine release and cause vasodilation [2,4,53].

It was demonstrated in our review of the literature that antenatal diagnosis and proper management of pheochromocytoma, particularly surgical resection in the second trimester of pregnancy, greatly reduced maternal and fetal mortality. Mannelli and Bemporad reported a maternal mortality reduction from 19% to 1%, and a fetal mortality reduction from 25% to 12% when the diagnosis was done antepartum compared to postpartum [6].

The vasoconstrictive effect of high catecholamine levels as well as uncontrolled HBP early in pregnancy may cause pathological changes to the uteroplacental circulation and abnormal placental development, leading to subsequent PE and IUGR despite removal of pheochromocytoma [1]. The risk for PE in subsequent pregnancies in case 1 was difficult to establish. Her pre-pregnancy BMI, early GDM and a new partner were risk factors for development of PE in her second pregnancy [1]. The occurrence of PE in a first pregnancy significantly increases risk of recurrence in a second pregnancy up to sevenfold, however this cannot be applied to our patient since uncontrolled HTN due to occurrence of pheochromocytoma probably explained the development of pre-eclampsia during the first pregnancy [54]. There are reports of repeated PE during subsequent pregnancies after pheochromocytoma removal without evidence of pheochromocytoma recurrence, although it is not known if these patients remained chronically hypertensive after surgical resection of pheochromocytoma [2]. Prevention of PE with low-dose aspirin and prophylactic LMWH was discussed with the patient to reduce the risk of placental complication in her pregnancy. Finally, her second pregnancy progressed favorably and has ended without occurrence of PE.

Suggested follow-up for pheochromocytoma diagnosed during pregnancy (Table 2).

Table 2: Recommendations for diagnosis, treatment, mode of delivery and follow-up for women with pheochromocytoma detected during pregnancy.

1. Diagnosis
1.1 Biochemical test
- Plasma free or 24-hour urinary fractionated metanephrine measurement
- Consider rapid screening for gestational diabetes upon pheochromocytoma diagnosis confirmation
1.2 Imaging
- Ultrasound imaging and/or magnetic resonance imaging (more sensitive test)
2. Treatment
2.1 Medical therapy
- Alpha-blocker (1st choice, Phenoxybenzamine, Prazosin, Doxazosin, Terazosin)
- Beta-blocker after appropriate alpha-blockade (Labetalol, Propranolol, Pindolol, Metoprolol)
- Calcium channel blocker dihydropyridine (Nifedipine XL, Amlodipine)
2.2 Medical therapy if hypertensive emergency
- Phentolamine, IV Labetalol or Esmolol, Nitroprussiate, Nitroglycerine, IV magnesium sulfate
2.3 Surgical resection if early diagnosis and should be performed before 24WG after appropriate pre - operative management with alpha-blocker +/- beta-blocker and calcium channel blocker for 7-14 days
3. Mode of delivery
3.1 If pheochromocytoma resected before delivery : Term vaginal or cesarean delivery depending on obstetrical evaluation and presentation
3.2 If pheochromocytoma not removed at moment of delivery: Term cesarean delivery preferred
4. Follow-up
4.1 Short-term follow-up
- Follow-up every 2-4 weeks during pregnancy and early post-partum for signs and symptoms of pre-eclampsia, incomplete resection of pheochromocytoma or unfound paraganglioma
- Genetic testing
- Plasma free or 24-hours urinary fractionated metanephrine measurement (1-2 weeks after surgery)
4.2 Long-term follow-up
- Annual plasma free or 24-hour urinary fractionated metanephrine measurement
- Biochemical, imaging screening and prenatal counseling depending on finding at genetic testing

During preconception care, patients with a pheochromocytoma-associated syndrome, should be screened for pheochromocytoma which should be resected if found. If pheochromocytoma is resected during pregnancy, plasma or urinary fractionated metanephrines should be monitored 1-2 weeks post-operatively to ensure complete resection [50]. Follow-up during pregnancy should be done at minimum once per trimester and include serial metanephrines testing, evaluation of glucocorticoid and mineralocorticoid dose (for patients who have previously undergone bilateral adrenalectomy) with assessment of volume status, blood pressure and serum electrolytes [55]. During labor, adequate hydration and stress doses of intravenous hydrocortisone could be required (25-50mg every 6 to 8 hours).

Some clinical clues for an underlying genetic syndrome include: Multifocal disease, young age at presentation (<30), family history of pheochromocytoma or syndrome-specific manifestations. However, it is currently recommended to discuss genetic testing with all patients diagnosed with pheochromocytoma or paraganglioma [50]. Furthermore, patients with pheochromocytoma in the course of syndromes can present

with other manifestations: Neurofibroma, café au lait patches and axillae and inguinal freckling (Neurofibromatosis type 1 syndrome), medullary thyroid cancer, hyperparathyroidism and/or marfanoid body habitus (Multiple Endocrine Neoplasia type 2), multiple paragangliomas (familial paraganglioma-pheochromocytoma syndrome). Among the 56 cases reviewed, only 31 mentioned a search for germline mutations and genetic syndromes were diagnosed in 15 cases (48%). However, among the remaining cases without genetic testing there were total of 17 cases that were suspicious of genetic causes: bilateral pheochromocytomas, large ≥ 6 cm unilateral adrenal masses, paraganglioma, concomitant pheochromocytoma and paraganglioma, unilateral pheochromocytoma with ganglioneuroma [9,18,20,24,26,28,32,37-40,45,46]. Since genetic syndromes are frequently found among women diagnosed with pheochromocytoma during pregnancy (48% in our review) it should be mandatory to search for germline mutations in this population [17]. This is particularly important for appropriate screening during follow-up of the patient and their family, as well as for prenatal counseling for subsequent pregnancies. Finally, excluding presence or recurrence of pheochromocytoma is an impor-

tant component of pregnancy planning in patients with familiar syndromes.

Annual follow-up for patients with diagnosed VHL includes a complete physical examination by a specialist physician, plasma or urinary metanephrines measurement, retinal examination by an ophthalmologist and abdominal MRI. Biennial cerebral and spinal MRI, and aural testing by an audiologist should also be performed [56]. Prenatal screening by amniocentesis or chorionic villus sampling should be discussed for pregnant patients with VHL, and, for patients planning pregnancy, pre-implantation genetic diagnosis may also be an option. Follow-up during pregnancy should include serial ophthalmologic exams and testing for plasma or urinary metanephrines in each trimester and a cerebral and spinal MRI at 4 months gestation. The patient should also be counseled on symptoms and signs of growing cerebral and spinal hemangioblastoma and pheochromocytoma. If the woman has retinal, cerebral or spinal hemangioblastoma, vaginal delivery may be contraindicated [56]. In addition, for patients who have previously undergone bilateral adrenalectomy, glucocorticosteroid replacement is aimed at reproducing physiological requirements during pregnancy, with often similar doses to non-pregnant state in first and second trimesters and a slight dose increase required during the third trimester. Adequate hydration with serial administration of stress doses of intravenous hydrocortisone are required during labor (25 mg every 6 to 8 hours) with increasing doses of hydrocortisone if labor is prolonged (50 mg every 6 to 8 hours). Mineralocorticoid replacement are often stable during pregnancy, though the dosage can be slightly reduced during the third trimester. Some women with primary adrenal insufficiency even follow normal evolution during pregnancy without mineralocorticoid replacement. Serial assessment of volume status, blood pressure and electrolytes balance are necessary (minimum once per trimester) to assure proper mineralocorticoid replacement. In case 1, increasing blood pressure prompted the discontinuation of fludrocortisone without sequelae.

Conclusion

We examined 2 cases of pheochromocytoma managed during pregnancy with different outcomes. These cases demonstrate that rapid management of pheochromocytoma in pregnancy with aggressive BP control is essential to minimize maternal and fetal morbidity. GDM screening at pheochromocytoma diagnosis is important as there is an elevated risk of hyperglycemia. Surgery appears to be safe when done in the second trimester, with improved maternal and fetal outcomes, compared, in the literature, to medical management alone. Postoperative BP needs to be followed closely until the end of pregnancy, as there is an elevated risk of PE or late gestational hypertension even after pheochromocytoma removal. Preconception and prenatal care, as well as genetic counseling, are of primary importance for women in reproductive age with a past history of, or newly diagnosed pheochromocytoma.

Declaration of Interest

For all authors, there is no conflict of interest that could be perceived as prejudicing the impartiality of the research reported.

Funding

This research did not receive any specific grant from any funding agency in the public, commercial or not-for-profit sector.

Authors contribution

All authors critically revised the manuscript and approved the final version to be published. Moreover, R.B. and THLN wrote the manuscript, researched data, reviewed the literature and contributed to discussion. F.W. and MJB reviewed/edited the manuscript. M.M. and I.B. researched data, contributed to discussion and reviewed/edited the manuscript. A.G. wrote the manuscript, reviewed the literature, contributed to discussion and reviewed/edited the manuscript.

Acknowledgements

The authors thank the study participants and their families, our endocrinology and obstetrics team, as well as John Davison for the manuscript review. Reproduction of illustrations is permitted.

References

1. Gulmezoglu AM SJ, Mathai M, Pena-Rosas JP. WHO recommendations for prevention and treatment of pre-eclampsia and eclampsia. World Health Organization. 2011; 37.
2. Gainer S, Raveendran A, Bagga R, Saha SC, Dhaliwal LK, Bhanjali AK. Pheochromocytoma in pregnancy can mimic severe hypertensive disorders. *Journal of obstetrics and gynaecology: The journal of the Institute of Obstetrics and Gynaecology*. 2011; 31: 539-541.
3. Biggar MA, Lennard TW. Systematic review of pheochromocytoma in pregnancy. *The British journal of surgery*. 2013; 100: 182-190.
4. Oliva R, Angelos P, Kaplan E, Bakris G. Pheochromocytoma in pregnancy: A case series and review. *Hypertension*. 2010; 55: 600-606.
5. Lindsay JR, Jonklaas J, Oldfield EH, Nieman LK. Cushing's syndrome during pregnancy: Personal experience and review of the literature. *The Journal of clinical endocrinology and metabolism*. 2005; 90: 3077-3083.
6. Mannelli M, Bemporad D. Diagnosis and management of pheochromocytoma during pregnancy. *Journal of endocrinological investigation*. 2002; 25: 567-571.
7. Lonser RR, Glenn GM, Walther M, Chew EY, Libutti SK, Linehan WM, et al. von Hippel-Lindau disease. *Lancet*. 2003; 361: 2059-2067.
8. Erlic Z, Neumann HP. When should genetic testing be obtained in a patient with pheochromocytoma or paraganglioma? *Clinical endocrinology*. 2009; 70: 354-357.
9. Dong D, Li H. Diagnosis and treatment of pheochromocytoma during pregnancy. *The journal of maternal-fetal & neonatal medicine: The official journal of the European Association of Perinatal Medicine, the Federation of Asia and Oceania Perinatal Societies, the International Society of Perinatal Obstet*. 2014; 27: 1930-1934.
10. Londhey VA, Kulkarni VK. Pheochromocytoma presenting as hypertension in pregnancy. *The Journal of the Association of Physicians of India*. 2010; 58: 508-510.
11. Ganguly S, LeBeau S, Pierce K, Ramanathan R, Salata R. Multiple paragangliomas in a pregnant patient with a succinate dehydrogenase B mutation. *Postgraduate medicine*. 2010; 122: 46-50.
12. Ben Hammouda S, Daaloul W, Ben Zina H, Bouguerra B, Sfar R. [Management of pheochromocytoma during pregnancy: About three cases]. *La Tunisie medicale*. 2007; 85: 1072-1074.

13. Wolf A, Goretzki PE, Rohrborn A, Feldkamp J, Simon D, et al. Pheochromocytoma during pregnancy: Laparoscopic and conventional surgical treatment of two cases. *Experimental and clinical endocrinology & diabetes: Official journal, German Society of Endocrinology [and] German Diabetes Association*. 2004; 112: 98-101.
14. Cheikhrouhou H, Khiari K, Cherif L, Hadj Ali I, Heni M, Rajhi H, et al. [Malignant pheochromocytomas: about three cases]. *Annales d'endocrinologie*. 2006; 67: 238-244.
15. Thapar PM, Dalvi AN, Kamble RS, Vijaykumar V, Shah NS, Menon PS. Laparoscopic transmesocolic excision of paraganglioma in the organ of Zuckerkandl. *Journal of laparoendoscopic & advanced surgical techniques Part A*. 2006; 16: 620-622.
16. Memon MA, Aziz W, Abbas F. Surgical management of pheochromocytoma in a 13-week pregnant woman. *BMJ case reports*. 2014; 2014.
17. Salazar-Vega JL, Levin G, Sanso G, Vieites A, Gomez R, Barontini M. Pheochromocytoma associated with pregnancy: unexpected favourable outcome in patients diagnosed after delivery. *Journal of hypertension*. 2014; 32: 1458-1463.
18. Mohamed Ismail NA ARR, Abd Wahab N, Muhammad R, Nor Azmi K. Pheochromocytoma and pregnancy: A difficult and dangerous ordeal. *Malaysian Journal of Medical Sciences*. 2012; 19: 4.
19. Miller MA, Mazzaglia PJ, Larson L, Ankner GM, Bourjeily GR, Curran P. Laparoscopic adrenalectomy for phaeochromocytoma in a twin gestation. *Journal of obstetrics and gynaecology: The journal of the Institute of Obstetrics and Gynaecology*. 2012; 32: 186-187.
20. Sbai H, Essatarra Y, Shimi A, Ankouz A, Benjelloun B, Oussaden A, et al. [Pheochromocytoma and pregnancy - Perioperative and obstetrical management: report of one case and review of literature]. *The Pan African medical journal*. 2010; 5: 19.
21. Snabboon T, Plengpanich W, Hounngam N, Buranasupkajorn P, Plengvidhya N, Sereepapong W, et al. Concurrent bilateral pheochromocytoma and thoracic paraganglioma during pregnancy. *Endocrine*. 2010; 37: 261-264.
22. Podolsky ER, Feo L, Brooks AD, Castellanos A. Robotic resection of pheochromocytoma in the second trimester of pregnancy. *JLS: Journal of the Society of Laparoendoscopic Surgeons*. 2010; 14: 303-308.
23. Sarathi V, Bandgar TR, Menon PS, Shah NS. Pheochromocytoma and medullary thyroid carcinoma in a pregnant multiple endocrine neoplasia-2A patient. *Gynecological endocrinology: The official journal of the International Society of Gynecological Endocrinology*. 2011; 27: 533-535.
24. Koroscil TM, McDonald S, Stutes S, Vila RJ. Use of fluorine-18-labelled deoxyglucose positron emission tomography with computed tomography to localize a paraganglioma in pregnancy. *Southern medical journal*. 2010; 103: 1238-1242.
25. Frayssinet C, Vezzosi D, Huyghe E, Lorenzini F, Bennet A, Caron P. [Retroperitoneal laparoscopic adrenalectomy in a pregnant woman presenting MEN2a with a pheochromocytoma: case report and review of the literature]. *Annales d'endocrinologie*. 2008; 69: 53-57.
26. Junglee N, Harries SE, Davies N, Scott-Coombes D, Scanlon MF, Rees DA. Pheochromocytoma in Pregnancy: When is Operative Intervention Indicated? *Journal of women's health*. 2007; 16: 1362-1365.
27. Moretti A, Minuto M, Berti P, Bernini GP, Mannelli M, Miccoli P. Unusual association of adrenal pheochromocytoma and para-aortic neurofibroma in pregnancy. *Journal of endocrinological investigation*. 2006; 29: 738-741.
28. Oger P, Raiffort C, Plouin PF, Mandelbrot L. [Pheochromocytoma and pregnancy. Case report]. *Gynecologie, obstetrique & fertilité*. 2006; 34: 323-325.
29. Kim PT, Kreisman SH, Vaughn R, Panton ON. Laparoscopic adrenalectomy for pheochromocytoma in pregnancy. *Canadian journal of surgery Journal canadien de chirurgie*. 2006; 49: 62-63.
30. Kamari Y, Sharabi Y, Leiba A, Peleg E, Apter S, Grossman E. Peripartum hypertension from pheochromocytoma: A rare and challenging entity. *American journal of hypertension*. 2005; 18: 1306-1312.
31. Nambirajan T, Leeb K, Neumann HP, Graubner UB, Janetschek G. Laparoscopic adrenal surgery for recurrent tumours in patients with hereditary phaeochromocytoma. *European urology*. 2005; 47: 622-626.
32. Phupong V, Witoonpanich P, Snabboon T, Tharavej C, Ultchawadi P. Bilateral pheochromocytoma during pregnancy. *Archives of gynecology and obstetrics*. 2005; 271: 276-279.
33. Valardo E, Ansaldo G, Assalino M, Massobrio A, Minuto M, Torre G, et al. Pheochromocytoma during pregnancy treated by surgery. A case report and the review of the literature. *Annali italiani di chirurgia*. 2010; 81: 227-230.
34. Huddle KR. Phaeochromocytoma in black South Africans - a 30-year audit. *South African medical journal=Suid-Afrikaanse tydskrif vir geneeskunde*. 2011; 101: 184-188.
35. Malinowski AK, Maxwell C, Sermer M, Rubin B, Gandhi S, Silver-sides CK. Pheochromocytoma in a Pregnant Woman With Prior Traumatic Aortic Injury. *Obstetrics and gynecology*. 2015; 126: 1089-1094.
36. Kitayama K, Kashiwagi S, Amano R, Noda S, Ohira G, Yamazoe S, et al. A case of bilateral pheochromocytoma during pregnancy. *BMC surgery*. 2015; 15: 55.
37. Kiroplastis K, Kambaroudis A, Andronikou A, Reklou A, Kokkonis D, Petras P, et al. Dealing with Pheochromocytoma during the First Trimester of Pregnancy. *Case reports in obstetrics and gynecology*. 2015; 2015: 439127.
38. Dattatrya KY, Vepalsingh TH, Ravikant SU, Gajendra SA, Kiran PS. Paraganglioma of Urinary Bladder Presenting as An Early Preeclampsia with Successful Perinatal Outcome After Surgery: A Case Report and Review of Literature. *Journal of clinical and diagnostic research: JCDR*. 2015; 9: 1-2.
39. Donatini G, Kraimps JL, Caillard C, Mirallie E, Pierre F, et al. Pheochromocytoma diagnosed during pregnancy: Lessons learned from a series of ten patients. *Surgical endoscopy*. 2018.
40. van der Weerd K, van Noord C, Loeve M, Knapen M, Visser W, de Herder WW, et al. ENDOCRINOLOGY IN PREGNANCY: Pheochromocytoma in pregnancy: Case series and review of literature. *European journal of endocrinology*. 2017; 177: R49-R58.
41. Muzannara MA, Tawfeeq N, Nasir M, Al Harbi MK, Geldhof G, Dimitriou V. Vaginal delivery in a patient with pheochromocytoma, medullary thyroid cancer, and primary hyperparathyroidism (multiple endocrine neoplasia type 2A, Sipple's syndrome). *Saudi journal of anaesthesia*. 2014; 8: 437-439.
42. Fraser LA, Kiaii B, Shaban J, Islam A, Diamantouros P, Jones PM, et al. Cardiac pheochromocytoma presenting during pregnancy. *BMJ case reports*. 2010; 2010.
43. Kolomeyevskaya N, Blazo M, Van den Veyver I, Strehlow S, Aagaard-Tillery KM. Pheochromocytoma and Von Hippel-Lindau in pregnancy. *American journal of perinatology*. 2010; 27: 257-263.

44. Kariya N, Nishi S, Hosono Y, Hamaoka N, Nishikawa K, Asada A. Cesarean section at 28 weeks' gestation with resection of pheochromocytoma: Perioperative antihypertensive management. *Journal of clinical anesthesia*. 2005; 17: 296-299.
45. Miller C, Bernet V, Elkas JC, Dainty L, Gherman RB. Conservative management of extra-adrenal pheochromocytoma during pregnancy. *Obstetrics and gynecology*. 2005; 105: 1185-1188.
46. Tong C, England P, de Crespigny PC, Millar R, Conn J. Diabetes mellitus as the only manifestation of occult phaeochromocytoma prior to acute haemorrhage in pregnancy. *The Australian & New Zealand journal of obstetrics & gynaecology*. 2005; 45: 91-92.
47. Melvin A, Kinsley B. Hypertension presenting early in pregnancy. *Clinical case reports*. 2015; 3: 1056-1057.
48. Wing LA, Conaglen JV, Meyer-Rochow GY, Elston MS. Paraganglioma in Pregnancy: A Case Series and Review of the Literature. *The Journal of clinical endocrinology and metabolism*. 2015; 100: 3202-3209.
49. Tingi E, Kyriacou A, Verghese L. Recurrence of phaeochromocytoma in pregnancy in a patient with multiple endocrine neoplasia 2A: A case report and review of literature. *Gynecological endocrinology : the official journal of the International Society of Gynecological Endocrinology*. 2016; 32: 875-880.
50. Lenders JW, Duh QY, Eisenhofer G, Gimenez-Roqueplo AP, Grebe SK, Murad MH, et al. Pheochromocytoma and paraganglioma: an endocrine society clinical practice guideline. *The Journal of clinical endocrinology and metabolism*. 2014; 99: 1915-1942.
51. Kudva YC, Sawka AM, Young WF, Jr. Clinical review 164: The laboratory diagnosis of adrenal pheochromocytoma: the Mayo Clinic experience. *The Journal of clinical endocrinology and metabolism*. 2003; 88: 4533-4539.
52. Lenders JW. Pheochromocytoma and pregnancy: A deceptive connection. *European journal of endocrinology*. 2012; 166: 143-150.
53. Doo AR, Kim D, Cha KN, Han YJ, Kim DC. Anesthetic management of a pregnant woman undergoing laparoscopic surgery for pheochromocytoma - A case report. *Korean journal of anesthesiology*. 2013; 64: 373-375.
54. Duckitt K, Harrington D. Risk factors for pre-eclampsia at antenatal booking: Systematic review of controlled studies. *Bmj*. 2005; 330: 565.
55. Lindsay JR, Nieman LK. The hypothalamic-pituitary-adrenal axis in pregnancy: Challenges in disease detection and treatment. *Endocrine reviews*. 2005; 26: 775-799.
56. Alliance V. In *The VHL Handbook: What You Need to Know About VHL - A reference handbook for people with von Hippel-Lindau, their families, and support personnel*. 2014: 16.