



# Cervical Pregnancy Combined with Placenta Accrete Spectrum (PAS): A Case Report

YF Chen; HW Su; MM Chou; WC Chen; JJ Tseng; MJ Chen\*

Department of Obstetrics and Gynecology, Taichung Veterans General Hospital, Taiwan.

## \*Corresponding Author(s): Chen Ming-Jer

Department of Obstetrics and Gynecology, Taichung Veterans General Hospital, No.1650, Taiwan Boulevard Sect. 4, Taichung City 40705, Taiwan.

Tel: +886-4-23592525 #5801

Email: mingjer\_chen@yahoo.com.tw

## Abstract

**Objective:** Cervical pregnancy combined with Placenta Accreta Spectrum (PAS) disorders is challenging both in diagnosis and management. Here, we present a case of cervical pregnancy complicated with placenta increta, and the following treatment and plan.

**Case report:** A 33-year-old woman, gravida 2, para 1, was diagnosed with cervical pregnancy at an estimated gestational age of 6+6/7 weeks. Local methotrexate was given initially with good response but subsequent abdominal pain with persistent vaginal bleeding was noted, and total abdominal hysterectomy was performed eventually. The pathology confirmed cervical pregnancy with placenta increta.

**Conclusions:** We present clear and diagnostic ultrasound images of cervical pregnancy, as well as our experience of the management of this rare condition.

Received: Feb 23, 2021

Accepted: Mar 11, 2021

Published Online: Mar 15, 2021

Journal: Annals of Obstetrics and Gynecology

Publisher: MedDocs Publishers LLC

Online edition: <http://meddocsonline.org/>

Copyright: © Chen MJ (2021). *This Article is distributed under the terms of Creative Commons Attribution 4.0 International License*

**Keywords:** Cervical pregnancy (ectopic pregnancy); Conservative treatment; Doppler ultrasonography; Placenta accrete spectrum (PAS); Case report.

## Introduction

Cervical pregnancy is defined as the implantation of the pregnancy within the endocervical canal. Cervical pregnancies are rare, accounting for less than 1 % of ectopic pregnancies, and the incidence is one in 2,500 to 18,000 pregnancies. It may be more common in pregnancies conceived via reproductive technologies [1,2].

Cervical pregnancy combined with Placenta Accreta Spectrum (PAS) disorders can be explained by the absence of protective decidua basalis in the cervical stroma, which results in trophoblastic invasion into the cervical tissue [3]. Either the implantation of a gestational sac or placenta into the cervix can cause disastrous consequences as the relatively non-contractile cervical stroma may not cease bleeding when the trophoblast tissue detaches [4].

**Cite this article:** Chen YF, Su HW, Chou MM, Chen WC, Tseng JJ, Chen MJ. Cervical Pregnancy Combined With Placenta Accrete Spectrum (PAS): A Case Report. *Ann Obstet Gynecol.* 2020; 4(1): 1023.



Cesarean Scar Pregnancy (CSP) is another clinical scenario which may sometimes be confused with cervical pregnancy. In cases with positive fetal cardiac activity, the higher number of maternal morbidities requires more than just expectant management [5]. The combination of cervical pregnancy with Abnormally Invasive Placenta (AIP) could be detected as early as the first trimester via sonography. Low anterior implantation of the placenta and gestational sac close to or within the scar are the most common signs suggestive of AIP [6,7].

There are only a few case reports on this situation, and some even required magnetic resonance imaging for diagnosis [8-11]. Given the rarity of this condition, we would like to share one such case with clear sonographic images and our experience of the subsequent management. From our case, we learned that Transvaginal Ultrasonography (TVUS), which is accessible in most clinical settings, is capable of detecting hints of this rare disease. Also, even though Uterine Artery Embolization (UAE) and topical injection of Methotrexate (MTX) could lead to a noticeable decrease in Beta-Human Chorionic ( $\beta$ -HCG) level, swelling of the necrotic gestational tissue could still cause troublesome pain and persistent bleeding.

### Case presentation

The patient was a 33-year-old woman, gravida 2, para 1, with a previous cesarean delivery due to twin pregnancy 5 years ago. A small amount of vaginal bleeding was noted at the time when her menstrual cycle was supposed to begin, and she went to a local gynecologic clinic, where abnormal pregnancy implantation was noted during a TVUS exam.

She was then referred to our hospital on March 04, 2017, at the estimated gestational age of 6+6/7 weeks. Cervical ectopic pregnancy was noted by TVUS (Figure 1 & Figure 2). Findings of TVUS were summarized as follows. A gestational sac, accompanied by fetal pole and cardiac activity, was located in the endocervical canal. The external cervical orifice was closed, and the internal cervical orifice was slightly dilated. The placenta was extremely swollen. Either the endometrial cavity (especially over the previous cesarean section scar) or the bilateral adnexa revealed signs of heterotopic pregnancy. The  $\beta$ -HCG level was 46,305 mIU/ml initially. Progressive growth of the mass was noted two days later on March 06, 2017, along with persistent fetal cardiac activity.

To prevent acute bleeding, UAE was performed on March 07, 2017. Because the residual cervical wall was too thin to allow hysteroscopic excision or dilatation and evacuation, local MTX injection into the gestational tissue was performed on March 08, 2017 (day 0). One week after the MTX injection, we saw only a minimal decrease in her  $\beta$ -HCG level, from 37,683 mIU/ml before injection to 35,000 mIU/ml, on March 15, 2017 (day 7). She received another MTX local injection on March 17, 2017 (day 9). Her  $\beta$ -HCG level dropped to 12,175 mIU/ml on March 24, 2017 (day 16) and decreased further to 3,755 mIU/ml on March 31, 2017 (day 23). Throughout the treatment course, she reported no vaginal bleeding or abdominal pain. However, serial TVUS demonstrated enlargement and edematous change of the cervical lesion, from 2x2cm before treatment to 4x4cm on March 31, 2017 (day 23).

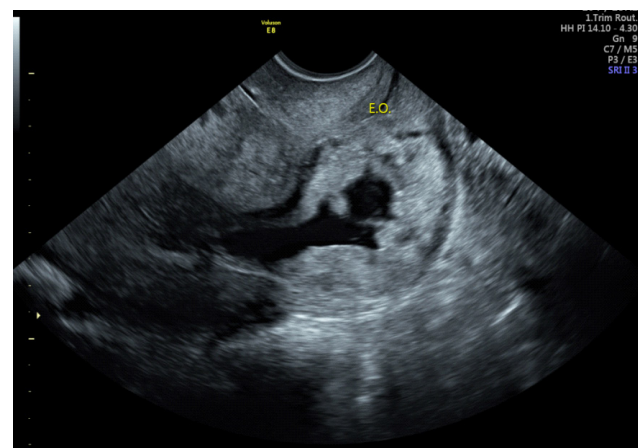
On April 06, 2017 (day 29) after the 1st MTX injection, persistent lower abdominal throbbing pain which radiated to her back and vaginal bleeding were noted. TVUS revealed enlarged ectopic mass with hypervascularity (Figure 3). Sterile Speculum

Exam (SSE) revealed that the cervix was engorged and the cervical stroma was so thin that it appeared transparent. Tenderness was noted when the lesion was lightly touched. At our ER, vital signs were stable, but mild tachycardia, 104 bpm, was noted. Hemoglobin level was as low as 9.7 g/dl compared with her previous record, which was 11.0g/dl and adequate fluid resuscitation was given.

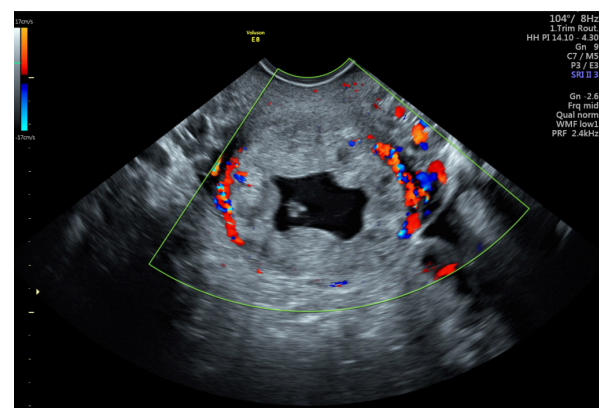
Considering the unbearable pain and uncertainty of the conservative treatment, and the patient and her husband had no desire to have more children, the patient agreed to hysterectomy. The second UAE, was performed on April 07, 2017 (day 30) in an attempt to prevent excessive surgical bleeding, and total abdominal hysterectomy was carried out subsequently. A 4-cm lesion consisting of necrotic gestational tissue and hematoma was found within the endocervical canal over the posterior wall, which was inseparable from the cervical stroma grossly. The whole surgery was performed smoothly, and the total blood loss was 150 ml.

The final histopathology report confirmed the diagnosis of cervical pregnancy with placenta increta: the gestational tissue was attached to the posterior wall of the cervix, with almost total penetration of trophoblasts, where only 1mm of the residual serosa was identified (Figure 4).

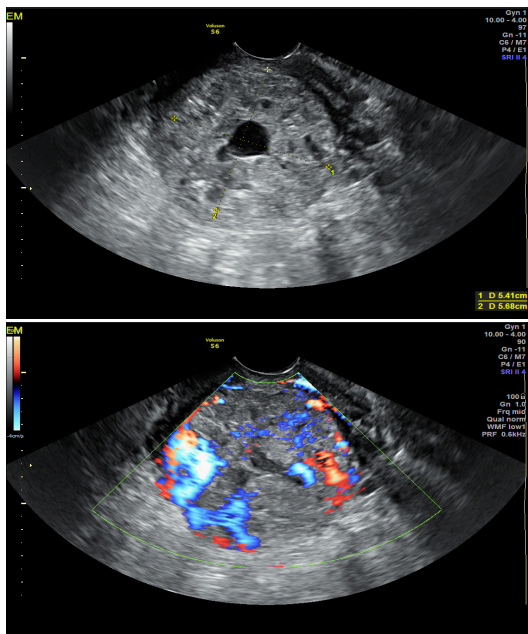
The postoperative care of the patient was uneventful, and she was discharged on the 4th day after the surgery. Her  $\beta$ -HCG level plummeted to 10.62 mIU/ml on April 21, 2017, 14 days after the hysterectomy (Figure 5).



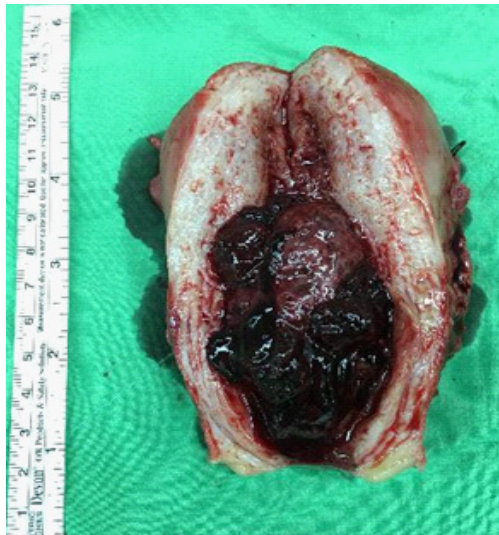**Figure 1:** March 04, 2017, Initial TVUS image: Ectopic mass located in the endocervical canal.



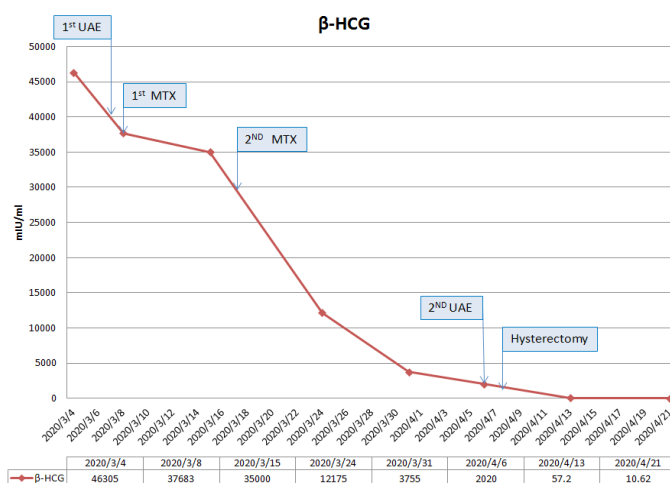
**Figure 2:** Initial TVUS image: Transverse view: Obvious gestational sac with fetal pole and strong peripheral Doppler signal.



**Figure 3:** April 6, 2017 (A,B). TVUS: Continuous enlargement of the cervical mass was noted. From 4.1 cm x 4.17 cm to 5.41 x 5.68 cm with persistent peripheral blood flow.



**Figure 4:** April 8, 2017, Main specimen of total abdominal hysterectomy. The bivalved uterus, from the anterior view, one bulging necrotic mass over the endocervical canal.



**Figure 5:** The β-HCG level along the whole treatment course.

### Discussion

We treated a rare case of cervical pregnancy in combination with PAS disorders. Only three similar cases have been reported in the literature [5,7,8].

Using TVUS, cervical pregnancy could be identified by several features, which include: (1) hourglass shape of uterus and ballooned endocervical canal; (2) visible gestational tissue within the cervix below the level of internal cervical os; (3) absence of intrauterine pregnancy and presence of endocervical canal between the gestational tissue and the endometrial canal [1,4].

The ultrasonographic diagnostic criteria of PAS disorders with concomitant cervical pregnancy have not been established. Some commonly used markers, such as vanished clear zone and interrupted bladder line, are not applicable. Based on our experience and other case reports [8,10,11], abnormally increased vascularity over the implantation site may be the only sign suggesting the possibility of PAS.

There is still no consensus on the treatment of ectopic cervical pregnancy. Physicians may offer options such as hysteroscopic resection, local or systemic MTX injection, trans-abdominal surgical intervention, and expectant management. Individualized management is crucial, based on the fertility desire of the patient, the patient’s general condition, and whether conservative treatment is an available option [11,14,15].

There are several case reports regarding MTX treatment for cervical pregnancy, whether it is given systemically or locally. Yamaguchi et al. reported that in 15 cases with cervical pregnancies, ultrasound-guided local MTX injection successfully normalized their β-HCG levels after a mean duration of 43.8 days [12]. Three patients, in whom a poor initial response was achieved, required a second dose. Our approach, inspired by Yamaguchi’s work, showed a rather good response at first. However, despite a proper decrease in the β-HCG level after the second MTX injection, the patient suffered from pain and bleeding resulting from excessive swelling of gestational tissue. In hindsight, the result seemed predictable considering the co-existence of placenta increta that allowed trophoblastic tissues to penetrate deeply into the cervical stroma. Necrosis and swelling of these tissues might even rupture the cervix. In our case, only 1mm of cervical tissue remained, which prevented possible excessive bleeding from a ruptured cervix.

Uterine Artery Embolization (UAE) serves as another treatment option, especially in patients desiring future fertility. In one case report, UAE alone was able to treat cervical pregnancy successfully [13]. It can also be provided alongside with MTX injection or intra-amniotic potassium chloride (KCL) injection [14], or as a prophylactic vascular control before surgical interventions. However, UAE presents complications, including tissue necrotic change, uterine ischemia, sciatic nerve injury, and bladder or rectum injury [13,15,16].

### Conclusions

Cervical pregnancy complicated by PAS disorders is challenging with regard to both diagnosis and management. This presentation of the clinical course, ultrasound images, and our experience from initial conservative management to hysterectomy could, hopefully, help other physicians who face similar conditions.

## References

1. Ngu SF, Cheung VYT. Non-tubal ectopic pregnancy. *Int J Gynaecol Obstet.* 2011; 115: 295–297.
2. Parker VL, Srinivas M. Non-tubal ectopic pregnancy. *Arch Gynecol Obstet.* 2016; 294: 19–27.
3. Society of Gynecologic Oncology, American College of Obstetricians and Gynecologists and the Society for Maternal–Fetal Medicine, Cahill AG, Beigi R, Heine RP, Silver RM, et al. Placenta Accreta Spectrum. *Am J Obstet Gynecol.* 2018; 219: B2–B16.
4. Mavrelou D, Jurkovic D. Non-Tubal Ectopic Pregnancy. In: Farquharson RG, Stephenson MD, editors. *Early Pregnancy.* Cambridge: Cambridge University Press. 2017; 187–195.
5. Cali G, Timor-Tritsch IE, et al. Outcome of Cesarean scar pregnancy managed expectantly: systematic review and meta-analysis. *Ultrasound Obstet Gynecol.* 2018; 51: 169–175.
6. Iacovelli A, Liberati M, Khalil A, et al. Risk factors for abnormally invasive placenta: A systematic review and meta-analysis. *J Matern Fetal Neonatal Med.* 2020; 33: 471–481.
7. D’Antonio F, Timor-Tritsch IE, Palacios-Jaraquemada J, et al. First-trimester detection of abnormally invasive placenta in high-risk women: Systematic review and meta-analysis. *Ultrasound Obstet Gynecol.* 2018; 51: 176–183.
8. Tariq A, O’Rourke M, Carstens SJ, Totten VY. Intra-abdominal Rupture of a Live Cervical Pregnancy with Placenta Accreta but Without Vaginal Bleeding. *CPCEM.* 2018; 2: 116–120.
9. Kirk E, Bottomley C, Bourne T. Diagnosing ectopic pregnancy and current concepts in the management of pregnancy of unknown location. *Hum Reprod Update.* 2014; 20: 250–261.
10. Grigoras D, Pirtea L. Cervical pregnancy with placenta percreta diagnosed after pregnancy termination at 10 weeks. *J Obstet Gynaecol.* 2014; 34: 362–364.
11. English D, Verma U, Yasin S. Conservative management of a 20-week cervical ectopic pregnancy with placenta percreta. *Arch Gynecol Obstet.* 2013; 288: 225–228.
12. Yamaguchi M, Honda R, Erdenebaatar C, Monsur M, Honda T, Sakaguchi I, et al. Treatment of cervical pregnancy with ultrasound-guided local methotrexate injection. *Ultrasound Obstet Gynecol.* 2017; 50: 781–787.
13. Headley A. Management of cervical ectopic pregnancy with uterine artery embolization: a case report. *J Reprod Med.* 2014; 59: 425–428.
14. Zakaria MA, Abdallah ME, Shavell VI, Berman JM, Diamond MP, Kmak DC. Conservative management of cervical ectopic pregnancy: utility of uterine artery embolization. *Fertil Steril.* 2011; 95: 872–876.
15. Chen H, Yang S, Fu J, Song Y, Xiao L, Huang W, et al. Outcomes of Bilateral Uterine Artery Chemoembolization in Combination with Surgical Evacuation or Systemic Methotrexate for Cervical Pregnancy. *J Minim Invasive Gynecol.* 2015; 22: 1029–1035.
16. Murji A, Garbedian K, Thomas J, Cruickshank B. Conservative management of cervical ectopic pregnancy. *J Obstet Gynaecol Can.* 2015; 37: 1016–1020.