



# Incidence of unexpected significant pathology in morcellated uterine specimens

Sherine Salama<sup>1</sup>; Nadia Ismiil<sup>1</sup>; Matthew Cesari<sup>1</sup>; Fang-I Lu<sup>1</sup>; Elzbieta Slodkowska<sup>1</sup>; Valerie Dubé<sup>1</sup>; Guangming Han<sup>1</sup>; Mark Marcus<sup>1</sup>; Ivy Heung<sup>1</sup>; Mahmoud A Khalifa<sup>2</sup>; Lilian T Gien<sup>1</sup>; Sharon Nofech-Mozes<sup>1\*</sup>

<sup>1</sup>University of Toronto, ON, Canada

<sup>2</sup>University of Minnesota, MN, USA

## \*Corresponding Author(s): Sharon Nofech-Mozes

Laboratory Medicine and Pathobiology, University of Toronto, Sunnybrook Health Sciences Centre, 2075 Bayview Ave, Toronto, ON, Canada  
Tel: 416- 480-6100  
Email: sharon.nofech-mozes@sunnybrook.ca

## Abstract

**Study objective:** To determine the frequency and outcome of significant pathology in morcellated hysterectomy and myomectomy specimens and to provide a detailed pathologic account on its relative clinical safety.

**Design:** This is a retrospective audit of morcellated uterine specimens where preoperative, operative, pathology, adjuvant therapy (when available) and follow up data were collected. Overt malignancy and high risk pathology cases were further analyzed.

**Setting:** Surgeries were performed by non-oncologic gynecological surgeons between September 1999 and May 2014 in a tertiary care academic practice.

**Measurements and main results:** Six hundred and two patients who underwent morcellated procedures were studied where 33 patients (5.5%) showed potentially significant pathological findings. These included 4 patients with overt malignancies (endometrial endometrioid adenocarcinoma in one case, leiomyosarcoma in one case, and endometrial stromal sarcoma in two cases), 12 patients with atypical endometrial hyperplasia, and 17 patients with myometrial tumors of unusual subtypes. Two of the 17 tumors in the latter group subsequently recurred as leiomyosarcoma. Only 56 of the 602 patients had preoperative endometrial biopsy within 6 months prior to morcellation.

**Conclusions:** Results of this audit highlight the potential challenge morcellation poses to pathologists as they attempt to document all pertinent pathologic features of unexpected malignancies, thoroughly evaluate high risk pathology, or confidently categorize myometrial tumors with unusual features. These limitations need to be considered while counselling patients prior to their surgery.

Received: Nov 23, 2018

Accepted: Jan 28, 2019

Published Online: Jan 31, 2019

Journal: Annals of Gynecologic Cancer

Publisher: MedDocs Publishers LLC

Online edition: <http://meddocsonline.org/>

Copyright: ©Nofech-Mozes S (2019). *This Article is distributed under the terms of Creative Commons Attribution 4.0 International License*

**Keywords:** Morcellation; Uterine malignancy; Hysterectomy; Leiomyosarcoma; Stump

**Cite this article:** Salama S, Ismiil N, Cesari M, Lu F, Nofech-Mozes S, et al. Incidence of unexpected significant pathology in morcellated uterine specimens. *Ann Gynecol Cancer*. 2019; 1(1): 1001.



## Introduction

Faster recovery from hysterectomy procedures, reduced postoperative pain, optimal cosmesis and rapid wound healing led to a trend of performing minimally invasive surgery in gynecology. The challenge of removing large uteri or fibroids through small incisions was thought to be overcome by tissue morcellation, a technique consisting of fragmenting tissues and organs into smaller pieces [1-3]. In women younger than 40 years, 40-49 years, and 50-59 years, the percentage of hysterectomies performed laparoscopically through morcellation is 33%, 44% and 16% respectively [4,5]. More recently, the practice of morcellation became under public and scientific scrutiny following public media appearance of patients associating it with dissemination of incidental leiomyosarcoma removed by morcellation for presumed leiomyomas and the increasing concerns regarding morcellator-related injuries [4, 6-12]. A retrospective cohort study evaluating the outcome of intraperitoneal morcellation of unsuspected uterine leiomyosarcoma pre-operatively confined to the uterus found that morcellation was associated with almost four times increased risk of recurrence and almost twice the risk of death when adjusted for age [13]. In April 2014, the U.S. Food and Drug Administration (FDA) issued an alert discouraging use of morcellating devices to remove fibroids due to cancer concerns [14]. The FDA's scientific analysis determined that the frequency of unsuspected uterine sarcoma in patients undergoing hysterectomy or myomectomy for presumed benign leiomyoma is 1 in 352 and that the frequency of unsuspected uterine leiomyosarcoma is 1 in 498. In November 2014 [15,16], the FDA issued a black box warning specifying that laparoscopic power morcellation should be contraindicated in perimenopausal and menopausal women. In a statement from December 2013, [17,18] the Society of Gynecologic Oncology (SGO) declared that there is no reliable method to completely exclude uterine sarcomas (leiomyosarcomas or endometrial stromal sarcomas) preoperatively in cases with presumed benign fibroids. Moreover, morcellation is contraindicated in the presence of documented or highly suspected malignancy and may be inadvisable in premalignant conditions or risk-reduction surgery [19,20].

In view of the aforementioned opinions and in an attempt to balance the risks and benefits of the procedure, the Advancing Minimally Invasive Gynecology Worldwide Association released guidelines related to morcellation limiting its use to patients with minimal risk of incidental malignancy and promoting discussion of possible adverse outcome as part of patient consenting to the procedure [21].

From a pathologist's perspective, the adequacy of the gross examination of morcellated specimens is compromised by loss of anatomical landmarks. Sampling of morcellated specimens is directed to include fragments with darker lining (thought to be endometrium), cervical tissue, ovarian or tubal structures and any abnormal looking tissue (soft consistency, hemorrhage, and necrosis). Standard determination of location, relationship to resection margins, tumor size and extent of disease is usually unavailable in morcellated specimens [22].

Limited data is available to date that objectively documents the incidence and outcome of previously unsuspected malignancies or premalignant conditions in morcellated specimens encountered in an academic group practice over an extended period of time. The current study is presented as a single academic institution audit emphasizing the pertinent pathologic aspects. The primary objective of this study is to determine the

frequency and outcome of unexpected overt malignancy or high risk pathology in morcellated hysterectomy and myomectomy specimens in our institution. A secondary objective is to provide a detailed pathologic perspective to the discussion around the relative clinical safety of morcellation.

## Methods

After obtaining Institutional Ethics Board approval, we retrospectively searched the Laboratory Information System (Co-Path™) for all in-house uterine resections performed by non-oncologic gynecological surgeons between September 1999 and May 2014. Morcellated specimens were identified from this pool through a natural language search. The Department of Anatomic Pathology services two academic general gynecology departments affiliated with the University of Toronto; Women's College Hospital and Sunnybrook Health Sciences Centre. The surgical procedure was verified through the operative reports accessed through the Electronic Medical Records. Pathologic consultation cases from surgical procedures performed at other institutions were excluded since they represented skewed, highly selected cases.

## Data collection

Patient age, date of procedure, main clinical indication for surgery, and instruments used for morcellation were retrieved from Electronic Medical Records. The corresponding pathology reports were audited to extract the specimen type, weight, diagnosis, pathologic findings in the endometrium, cervix, ovaries and tubes and number of tissue blocks. For preoperative data, the Electronic Medical Records was searched for endometrial biopsy, cervical biopsy/encocervical curettage and pelvic imaging performed for these patients within 6 months prior to their morcellation surgery and their results were recorded. Available Pap smear test results within 3 years preoperatively were also obtained.

Cases with significant pathology findings were classified into two categories: the first category included patients with any overt malignancy and the second included those with high risk pathology (atypical endometrial hyperplasia, cervical dysplasia and clinically relevant leiomyoma variants). For both the overt malignancy and high-risk pathology categories, we recorded the information pertaining to adjuvant treatment, outcomes, time to recurrence (if any), site of recurrence and overall survival. Descriptive statistics were used to analyze the data.

## Results

We identified 602 morcellated procedures during the study period. Typically, morcellation specimens were composed of cord like structures or multiple tissue fragments. There were 119 (19.8%) myomectomies, 344 (57.1%) supracervical hysterectomies, and 139 (23.1%) total hysterectomies. One patient underwent LEEP at the time of myomectomy morcellation. The mean patient age was 45±6 years. Patients 40 years old or younger accounted for 21.8% of the cases. The main indication for surgery for all patients was "fibroids" (77.9%).

We observed that the number of morcellation procedures increased over the study period. The procedure was infrequent before 2003, with gradual increase between 2003 - 2009. The peak incidence was reached in 2010 with 74 cases performed that year. A steady significant decline was noticed in 2014 (Figure 1).

The instrument used for morcellation was mentioned in 278 (46%) reports; the Stortz electric morcellator was the most widely used followed by the Rotocut morcellator. Manual morcellation was carried out using a scalpel in 45 cases and manual morcellator in 5 cases. The exact method of morcellation was not recorded in the operative notes in 324(54%) cases.

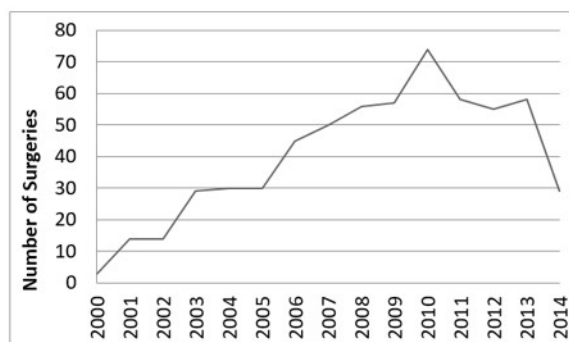


Figure 1: Number of morcellated surgeries per year (2000-2014).

### Preoperative Data

Preoperative assessment data revealed that 56 patients (9%) had an endometrial biopsy within 6 months prior to morcellation. Endometrial biopsy showed atypical endometrial hyperplasia in one case and hyperplasia without atypia in two cases. In these patients, the final pathology of the morcellated hysterectomies revealed atypical hyperplasia in one of the cases which was originally diagnosed with hyperplasia without atypia on biopsy and was negative for hyperplasia or atypia in the other two cases. Among 7 patients who had cervical biopsy within 6 months prior to morcellation, one had High Grade Intraepithelial Squamous Lesion (HSIL), one had Low Grade Squamous Intraepithelial Lesion (LSIL), 4 cases had endocervical polyps and one had reactive changes. A record of pap smears performed within 3 years prior to the morcellation procedure was available for 273 patients. One case had High Grade Squamous Intraepithelial Lesion (HSIL), 3 cases had Low Grade Squamous Intraepithelial Lesion (LSIL), 1 case had ASCUS, 3 cases had ASCUS with endometrial cells present, and 15 cases had endometrial cells present. Preoperative pelvic imaging studies were performed for 83 patients in our center and in 108 cases in other centers. Ultrasound was performed for 61 patients, MRI in 10, one case had both US and MRI, 3 cases had CT scans, and 2 patients had both US and CT scan.

### Pathology Data

The average weight of the morcellated specimens was  $411 \pm 339$  gm. On average, cases were sampled in  $14 \pm 6.3$  paraffin blocks for pathologic evaluation. The endometrium was present in 480 (79.7%) specimens, cervical tissue in 139 (23.1%) specimens, ovarian tissue in 144 (23.9%) specimens and fallopian tube tissue in 258 (42.9%) specimens.

Thirty-three of the 602 morcellated specimens (5.5%) showed potentially significant pathological findings, amongst which 4 patients (0.7% of the entire cohort, 12% of the cases with significant findings) had overt malignancies and their characteristics are summarized in Table 1. The histologic type was Endometrial Endometrioid Adenocarcinoma (EEA) in one case, Leiomyosarcoma (LMS) in one case, and Endometrial Stromal Sarcoma (ESS) in two cases. Morcellation method was known in two of the unexpected overt malignant cases, power morcellator was used in the case of endometrial Endometrioid Adenocarcinoma (EEA), and scalpel morcellation in one case with

Endometrial Stromal Sarcoma (ESS).

All 4 cases with overt malignancy were operated upon with the presumed clinical diagnosis of "fibroids". Pelvic pain and menorrhagia were noted in the case with Leiomyosarcoma (LMS), and endometrial endometrioid adenocarcinoma, respectively. None of the 4 cases had preoperative endometrial biopsies recorded in our system. Ultrasound and CT were performed in one of the incidental malignant cases with EEA.

In addition, high risk pathology was seen in 29 patients, including 12 patients (2% of the entire cohort and 36% of the cases with significant pathological findings) with atypical endometrial hyperplasia (Table 2) and 17 patients (about 2.8% of the entire cohort, 52% of the cases with significant findings) with myometrial tumors (Table 3) (3 smooth muscle tumor of unknown malignant potential or STUMP, 1 intravascular leiomyoma, 3 atypical/bizarre leiomyoma, 2 mitotically active leiomyoma, 7 cellular leiomyomas, and 1 epithelioid leiomyoma). Among cases revealing atypical endometrial hyperplasia the morcellation method was known in 6/12 cases, power morcellation was used in four cases and scalpel in two. Among cases revealing special types of myometrial tumors the morcellation method was known in 6/17 cases, power morcellation was used in four cases and scalpel in two.

### Adjuvant management and follow up

The patient with Leiomyosarcoma (LMS) received postoperative radiotherapy (brachytherapy and external beam) and chemotherapy. The tumor recurred after 9 months from the initial diagnosis with widespread pelvic and abdominal, peritoneal, and pelvic side wall involvement and the patient died of her disease within 13 months of recurrence. The other three patients with overt malignancies underwent further surgical procedures. The patient with EEA was initially treated with subtotal hysterectomy and underwent completion trachelectomy, bilateral salpingo-oophorectomy and peritoneal biopsies. One patient with ESS underwent completion trachelectomy following her subtotal hysterectomy. None of the three cases recurred after a period of follow up between 24-57 months (Table 1).

Within a median follow up of 22 months (range 1-84), none of the 12 patients with atypical endometrial hyperplasia revealed evidence of recurrence and no further management was undertaken for any of these patients (Table 2). The three cases diagnosed as Smooth Muscle Tumor with Uncertain Malignant Potential (STUMP) were followed up for 46, 31, and 34 months respectively and none recurred. One patient who had originally undergone morcellated myomectomy, received further surgery (total hysterectomy, bilateral salpingectomy and bilateral ovarian cystectomy). Two recurrences were encountered in the other myometrial tumors group, both patients had undergone power morcellation procedure. One patient (Table 3, case 6) had a morcellated myomectomy for a preoperative diagnosis of large fibroid (15 cm). The histology was reported as smooth muscle tumor with atypical features. It exhibited focal cytologic atypia, 3 mitoses per 10 high power fields and necrosis of indeterminate nature, in which the possibility of infarction was favored over tumor cell necrosis. Approximately 12 months later she presented with abdominal masses and pressure symptoms. At the time of subsequent operation she had tumor in the omentum, pelvic peritoneum and a retroperitoneal nodule just below the liver bed. She underwent completion hysterectomy, bilateral salpingo-oophorectomy, total omentectomy and removal of all visible tumor masses. The final pathology

was then reported as a STUMP and a note was made of the presence of significant mitotic activity. A second opinion was obtained following the final surgery suggesting a diagnosis of leiomyosarcoma for the subsequent resection. Upon follow up, no evidence of further progression is noted within 39 months of initial surgery. The second patient with unusual myometrial tumor who experienced recurrence (Table 3, case 10) had an initial diagnosis of cellular leiomyoma in a morcellated supracervical hysterectomy. The specimen weighed 950 grams and was sampled in 20 representative blocks. Multiple solid vascular masses within the lower abdomen and pelvis were detected on imaging performed after presenting with acute abdominal symptoms 54 months after her morcellation hysterectomy. Surgical resection of these masses revealed atypical myometrial tumor, then diagnosed as leiomyosarcoma and the patient underwent an additional cytoreductive procedure 64 months after the morcellation procedure. The pathology of the two subsequent excisions was described as histologic features in keeping with STUMP but given the clinical presentation and multiple sizable abdominopelvic masses a designation of leiomyosarcoma was favored. The patient is stable 18 month following her last procedure (Table 3).

### Discussion

Morcellated specimens can be very challenging to assess. Macroscopic evaluation and sampling are compromised by the loss of gross anatomical landmarks. Even when incidental malignancies are diagnosed, it would become difficult for the pathologist to adequately report on substantial pathological prognostic parameters mandated by the College of American Pathologists and AJCC such as tumor size, depth of invasion, and adequacy of resection [22,23]. The two study cases initially viewed as leiomyoma variants that subsequently recurred and retrospectively classified as leiomyosarcoma illustrate the limitations of sampling and evaluating morcellated specimens. We hypothesize that the initial “under-diagnosis” in these two myometrial tumors was under-sampling since the diagnosis of leiomyosarcoma is often reached with a high degree of confidence when the entire tumor is examined in an intact hysterectomy specimen.

With a “benign” clinical impression and the preoperative workup of the patient by endometrial sampling and imaging, safety of the morcellation technique for “fibroids” could be comparable to that of conventional simple hysterectomy. Overall, the majority of the patients included in our study did not have preoperative imaging or endometrial sampling, with less than a third having any pelvic imaging and less than 10% had any type of endometrial sampling. However, none of the 4 patients with unexpected overt malignancy had preoperative endometrial biopsies and only one had preoperative ultrasonography and CT exams. Of the 12 patients with unexpected atypical endometrial hyperplasia, only 3 had preoperative endometrial biopsies, none of which exhibited atypical hyperplasia and only 2 had preoperative imaging studies. Neither of the patients who recurred with leiomyosarcomas had a preoperative endometrial biopsy and only one had ultrasonography done preoperatively. Preoperative pelvic exam, imaging and even tissue sampling, although warranted, still cannot entirely rule out the possibility of significant findings on final pathology due to existing limitations. While preoperative endometrial biopsies should be obtained prior to a morcellation procedure, especially in patients with menorrhagia, tissue obtained through dilatation and curettage has a false negative rate of 20% for endometrial carcinomas

[24]. The false negative rate for uterine sarcomas is 36% since leiomyosarcomas arise from the myometrium and therefore, are less likely to be captured on the endometrial surface [25]. Another recent retrospective review of a large series of patients found that atypical spindle cells diagnostic or suspicious for LMS were identified in only 51.5% of the preoperative biopsied of their patients with final diagnosis of LMS on surgical resection [26]. Therefore, even if a preoperative endometrial sampling is performed, it would be uninformative in almost half of patients with LMS. All of these findings have led to the current perception that preoperative endometrial biopsies lack the needed sensitivity for proper patient triaging. Moreover, preoperative radiological diagnosis of malignancy is also challenging. Ultrasound is often used in perimenopausal and postmenopausal women with abnormal bleeding. However, imaging including ultrasound, CT or MRI has a limited role in differentiating benign fibroids from LMS or ESS due to overlapping features [27]. The incremental risk due to morcellation in uterine sarcomas is hard to estimate and should be examined in the context of its comparable prognosis in intact hysterectomy specimens. The overall 5-year survival rates for patients with Leiomyosarcoma (LMS) range from 15% to 25% [28,29]. The 3-year progression-free interval was 31% in a GOG series of 59 early-stage leiomyosarcomas; the first recurrence was in the pelvis in 14% of cases and in the lung in 41% [30]. Other studies have also shown a 5-year survival rate of 40–70% for stage I and II tumors [31-33]. Low grade ESS is more indolent as the five year, disease-specific survival for stage I and II is 90% [34]. In contrast, patients with undifferentiated uterine sarcoma usually die within 2 years of diagnosis [35]. In the current study, only one patient had the unexpected diagnosis of leiomyosarcoma in her morcellation specimen. It is of note that while the usual mode of recurrence in patients with LMS is lung metastasis, this patient’s disease recurred with widespread pelvic and abdominal peritoneal and pelvic side wall involvement. The unusual method of spread in this patient raises the question of whether morcellation itself may have participated and modified disease progression. Moreover, our results highlight the issue of sampling and diagnostic accuracy of myometrial tumors in morcellated specimens since two additional patients with the unexpected diagnosis of leiomyoma variants (one atypical and one cellular leiomyoma) recurred in 12 and 64 months with disseminated leiomyosarcoma. This observation raises the question of whether these two tumors would have had a better chance to be properly diagnosed as leiomyosarcomas had they been resected in an intact hysterectomy specimen.

In our study, 0.7% of the morcellated cases had unexpected malignancies (1EEA, 1LMS, and 2ESS), 0.49% had a STUMP and 2.3% had other leiomyoma variants. The low incidence of unexpected malignancies found in this study is in line with previous reports. A recent two-institution audit [36], found one case of endometrial carcinoma in a cohort of 502 patients who underwent morcellation. Previous studies looked at the likelihood of upgrading the diagnosis to LMS from presumably fibroid uteri, but did not specify the proportion of cases with other significant incidental findings. The incidence of unexpected uterine sarcomas in intact hysterectomies or myomectomies performed for presumably benign disease ranges between 0.14-0.49% [7,8]. The exact incidence of STUMP, however, is not clear and there is limited information regarding the long term prognosis after standard management [37]. This is mostly due to the inherent difficulties in making this diagnosis and the inconsistency among pathologists applying its diagnostic criteria. The data is even

more scarce for the outcome and management of patients with unexpected STUMP and ESS in morcellated uteri for benign conditions [11,38,39]. A previous study [37], reported on 6 STUMP, and 2 ESS diagnosed in morcellated uteri where none of the 4 STUMP patients who underwent secondary surgical exploration had evidence of malignancy. Similarly, one of three STUMP patients in our study had a secondary surgical procedure with no evidence of residual disease. Peritoneal dissemination was reported post-morcellation in a large retrospective study with 10 leiomyoma variants /STUMP. In 4/5 patients who underwent a follow-up laparoscopic evaluation morcellator-based peritoneal dissemination was documented [11]. Peritoneal dissemination was also reported following a primary diagnosis of ESS in a morcellated specimen in one patient [37]. In our study, one of the two ESS cases underwent secondary surgical procedure with no evidence of disease.

As expected, since the overall risk of malignancy increases with age, women undergoing morcellation were highly selected in our study with a mean age of 45±6 years. No unexpected overt malignancy was observed in any of the 94 women aged 40 years or younger in our study. However, two patients under 40 years old had potentially clinically relevant myometrial tumor variants (cases 8 and 10, Table 3), and one of them recurred (case 10, Table 3). In addition, a 46 year old patient with an atypical leiomyoma experienced recurrence (case 6, Table 3). This study was not designed or powered to detect difference in outcomes for the malignant cases, especially since 3 different malignancies were detected and the follow up period is limited

given the indolent course of low grade ESS.

We did not limit our discovery to overt malignancy but we also examined the incidence of other significant, high risk pathologies as well. The extent of targeted tissue sampling for microscopic examination is very important in such cases. Whereas, in morcellated specimens, it is very difficult to ascertain that the entire endometrium was examined. In addition, it is very challenging to identify grossly additional fragments originating from the areas of concern amongst the entire morcellated specimen or to ascertain complete removal of the lesion.

### Conclusion

In our retrospective institutional audit, the overall likelihood of unexpected overt malignancy or high risk pathology in morcellated specimen was relatively low (5.5%) despite the observed restricted use of preoperative imaging or endometrial sampling and so was the risk of recurrence following morcellation procedure. However, it highlighted the potential challenge this procedure poses to pathologists as they attempt to document all pertinent prognosticators of unexpected malignancies, thoroughly evaluate high risk pathology, or confidently categorize myometrial tumors with unusual features. These limitations need to be considered while counselling patients prior to their surgery.

The results have to be condensed and made crisp. The discussion should be condensed as the information in the results is repeated again in the discussion.

### Tables

**Table 1:** Clinical characteristics of the four patients the diagnosis of malignancy.

Type of malignancy	Age	Menopausal status	Pre-operative imaging	Surgery	Weight (gm)	Postoperative treatment	FU (months)	Outcome
EEA	48	Perimenopausal	0	SCH + RSO + LS	680	Trachelectomy, left oophorectomy, omentectomy, peritoneal biopsy.	24	NED
LMS	41	Unknown	0	SCH	683	Chemotherapy + radiotherapy (brachytherapy and external beam)	13	DOD
ESS	40	Premenopausal	0	TH+ BS	757	None	24	NED
ESS	52	Postmenopausal	US-CT	SCH	370	Trachelectomy, laparoscopy, biopsy of left round ligament, and vaginal polyp	57	NED

EEA: Endometrial Endometrioid Adenocarcinoma; LMS: Leiomyosarcoma; ESS: Endometrial Stromal Sarcoma; SCH: Supracervical Hysterectomy; TH: Total Hysterectomy; RSO: Right Salpingo-Oophorectomy; LS: Left Salpingectomy; BS: Bilateral Salpingectomy; NED: No Evidence of Disease; DOD: Died Of Disease

**Table 2:** Clinical information of cases with diagnosis of atypical endometrial hyperplasia on morcellated specimens.

Cases	Age	Menopausal status	Preoperative imaging	Preoperative endometrial biopsy	Surgery	Specimen weight	FU (month)
1	48	Premenopausal	0	0	SCH	230	67
2	47	?	0	0	SCH	930	84
3	43	Premenopausal	0	0	SCH	420	22
4	57	Postmenopausal	0	polyp	TH + RO	171	Not available
5	52	Postmenopausal	0	Focal hyperplasia without atypia	TH, + BSO	1485	24
6	49	Perimenopausal	US	0	TH, +BS	554	32
7	53	?	CT	0	TH + BSO	270	1
8	44	Perimenopausal	0	0	SCH	87	40

9	43	?	0	0	TH+ BS	1610	2
10	44	Premenopausal	0	0	TH + BS	1175	12
11	48	Perimenopausal	0	Secretory endometrium	TH + BS	122	7
12	51	Perimenopausal	0	0	TH + BSO	517	2

SCH: Supracervical Hysterectomy; TH: Total Hysterectomy; RO: Right Oophorectomy; BSO: Bilateral Salpingo-Oophorectomy; BS: Bilateral Salpingectomy; ?: Menopausal Status Unknown

**Table 3:**

Cases of unusual leiomyomas	Age	Menopausal status	Preoperative imaging	Preoperative endometrial biopsy		Postoperative treatment	FU (Months)			Outcome	
1-STUMP	49	N/A	0	0		TH + BS	651	No	46	-	NED
2-STUMP	46	peri	0	0		myomectomy	863	TH +BS + BOC	31	-	NED
3-STUMP	42	N/A	US	0		myomectomy	195	No	34	-	NED
4-IVLM	48	N/A	0	0		TH	720	No	83	-	NED
5-Atypical LM	52	N/A	US	0		TH + BSO	731	No	4	-	NED
6-Atypical LM	46	N/A	US	0		myomectomy	917	TH +BSO + removal of abdominal tumors*	39	+ (12)	NED
7-Atypical LM	53	N/A	US	0		TH + BSO	1281	No	39	-	NED
8- Mitotically active	29	pre	CT	secretory		myomectomy	185	No	48	-	NED
9- Mitotically active	50	N/A	US	secretory		SCH	222	No	68	-	NED
10- Cellular LM	33	N/A	0	0		TH + BS + ROC	949	Removal of cervical stump, cytoreduction**	64	+ (64)	AWD
11- Cellular LM	51	peri	0	0		TH+ BSO	1021	No	31	-	NED
12- Cellular LM	40	pre	0	0		myomectomy	27	No	127	-	NED
13- Cellular LM	46	pre	0	0		myomectomy	350	No	110	-	NED
14- Cellular LM	46	peri	0	0		SCH	242	No	102	-	NED
15- Cellular LM	50	peri	US	0		SCH	1016	No	91	-	NED
16- Cellular LM	43	peri	US	0		SCH	415	No	72	-	NED
17- Epithelioid LM	40	pre	0	0		TH + BSO	285	No	55	-	NED

STUMP: Smooth Muscle Tumor with Uncertain Malignant Potential; IVLM: Intravascular Leiomyoma; LM: Leiomyoma; SCH: Supracervical Hysterectomy; TH: Total Hysterectomy; BS: Bilateral Salpingectomy; BOC: Bilateral Ovarian Cystectomy; ROC: Right Ovarian Cystectomy; NED: No Evidence of Disease; AWD: Alive With Disease.

\*The patient recurred with tumor masses in the omentum, pelvic peritoneum and retroperitoneal nodule just below the liver bed.

\*\*The patient underwent several surgeries; removal of cervical stump (2012) which was positive for high grade dysplasia, laser vaginal cauterization for VAIN3 (2012), excision of peritoneal mass found during appendectomy (2015), excision of presacral mass, right abdominal wall mass, BSO, and optimal cytoreduction (2016).

## References

- Steiner RA, Wight E, Tadir Y, Haller U. Electrical cutting device for laparoscopic removal of tissue from the abdominal cavity. *Obstet Gynecol.* 1993; 81: 471-474.
- De Grandi P, Chardonnens E, Gerber S. The morcellator knife: a new laparoscopic instrument for supracervical hysterectomy and morcellation. *Obstet Gynecol.* 2000; 95: 777-778.
- Kho KA, Nezhat CH. Evaluating the risks of electric uterine morcellation. *JAMA.* 2014; 311: 905- 906.
- Wright JD, Ananth CV, Lewin SN, Burke WM, Lu YS, Neugut AI, et al. Robotically assisted vs laparoscopic hysterectomy among women with benign gynecologic disease. *JAMA.* 2013; 309: 689-698.
- Whiteman MK, Hillis SD, Jamieson DJ, Morrow B, Podgornik MN, Brett KM, et al. Inpatient hysterectomy surveillance in the United States, 2000-2004. *Am J Obstet Gynecol.* 2008; 198: e1-e7.
- Milad MP, Milad EA. Laparoscopic morcellator-related complications. *J Minim Invasive Gynecol.* 2014; 21: 486-491.
- Leibsohn S, d'Ablaing G, Mishell DR, Schlaerth JB. Leiomyosar-

- coma in a series of hysterectomies performed for presumed uterine leiomyomas. *Am J Obstet Gynecol.* 1990; 162: 968-974.
8. Parker WH, Fu YS, Berek JS. Uterine sarcoma in patients operated on for presumed leiomyoma and rapidly growing leiomyoma. *Obstet Gynecol.* 1994; 83: 414-418.
  9. Ramm O, Gleason JL, Segal S, Antosh DD, Kenton KS. Utility of preoperative endometrial assessment in asymptomatic women undergoing hysterectomy for pelvic floor dysfunction. *Int Urogynecol J.* 2012; 23: 913-917.
  10. Frick AC, Walters MD, Larkin KS, Barber MD. Risk of unanticipated abnormal gynecologic pathology at the time of hysterectomy for uterovaginal prolapse. *Am J Obstet Gynecol.* 2010; 202: 507.
  11. Seidman MA, Oduyebo T, Muto MG, Crum CP, Nucci MR, Quade BJ. Peritoneal dissemination complicating morcellation of uterine mesenchymal neoplasms. *PLoS One.* 2012; 7: e50058.
  12. Hagemann IS, Hagemann AR, LiVolsi VA, Montone KT, Chu CS. Risk of occult malignancy in morcellated hysterectomy: a case series. *Int J Gynecol Pathol.* 2011; 30: 476-483.
  13. George S, Barysaukas C, Serrano C, Oduyebo T, Rauh-Hain JA, et al. Retrospective cohort study evaluating the impact of intraperitoneal morcellation on outcomes of localized uterine leiomyosarcoma. *Cancer.* 2014; 120: 3154-3158.
  14. FDA. Laparoscopic Uterine Power Morcellation in Hysterectomy and Myomectomy: FDA Safety Communication.
  15. FDA. Recommended Labeling Statements Excerpted from: Immediately in Effect Guidance Document: Product Labeling for Laparoscopic Power Morcellators: Guidance for Industry and Food and Drug Administration Staff. 2014.
  16. FDA. UPDATED Laparoscopic Uterine Power Morcellation in Hysterectomy and Myomectomy: FDA Safety Communication.
  17. Oncology SoG. SGO Position Statement: Morcellation.
  18. Oncology SoG. Statement of the Society of Gynecologic Oncology to the Food and Drug Administration's Obstetrics and Gynecology Medical Devices Advisory Committee Concerning Safety of Laparoscopic Power Morcellation.
  19. Andy UU, Nosti PA, Kane S, White D, Lowenstein L, et al. Incidence of unanticipated uterine pathology at the time of minimally invasive abdominal sacrocolpopexy. *J Minim Invasive Gynecol.* 2014; 21: 97-100.
  20. Goff BA. SGO not soft on morcellation: risks and benefits must be weighed. *Lancet Oncol.* 2014; 15: e148.
  21. Brown J. AAGL advancing minimally invasive gynecology worldwide: statement to the FDA on power morcellation. *J Minim Invasive Gynecol.* 2014; 21: 970-971.
  22. Protocol for the Examination of Specimens From Patients With Sarcoma of the Uterus: College of American Pathologists.
  23. Edge SB, Compton CC. The American Joint Committee on Cancer: the 7th edition of the AJCC cancer staging manual and the future of TNM. *Ann Surg Oncol.* 2010; 17: 1471-1474.
  24. Twu NF, Chen SS. Five-year follow-up of patients with recurrent postmenopausal bleeding. *Zhonghua Yi Xue Za Zhi (Taipei).* 2000; 63: 628-633.
  25. Bansal N, Herzog TJ, Burke W, Cohen CJ, Wright JD. The utility of preoperative endometrial sampling for the detection of uterine sarcomas. *Gynecol Oncol.* 2008; 110: 43-48.
  26. Hinchcliff EM, Esselen KM, Watkins JC, Oduyebo T, Rauh-Hain JA, et al. The Role of Endometrial Biopsy in the Preoperative Detection of Uterine Leiomyosarcoma. *J Minim Invasive Gynecol.* 2016; 23: 567-572.
  27. Exacoustos C, Romanini ME, Amadio A, Amoroso C, Szabolcs B, et al. Can gray-scale and color Doppler sonography differentiate between uterine leiomyosarcoma and leiomyoma? *J Clin Ultrasound.* 2007; 35: 449-457.
  28. Pelmus M, Penault-Llorca F, Guillou L, Collin F, Bertrand G, et al. Prognostic factors in early-stage leiomyosarcoma of the uterus. *Int J Gynecol Cancer.* 2009; 19: 385-390.
  29. Larson B, Silfversward C, Nilsson B, Pettersson F. Prognostic factors in uterine leiomyosarcoma. A clinical and histopathological study of 143 cases. The Radiumhemmet series 1936-1981. *Acta Oncol.* 1990; 29: 185-191.
  30. Major FJ, Blessing JA, Silverberg SG, Morrow CP, Creasman WT, et al. Prognostic factors in early-stage uterine sarcoma. A Gynecologic Oncology Group study. *Cancer.* 1993; 71: 1702-1709.
  31. Gadducci A, Landoni F, Sartori E, Zola P, Maggino T, et al. Uterine leiomyosarcoma: analysis of treatment failures and survival. *Gynecol Oncol.* 1996; 62: 25-32.
  32. Nola M, Babic D, Ilic J, Marusic M, Uzarevic B, et al. Prognostic parameters for survival of patients with malignant mesenchymal tumors of the uterus. *Cancer.* 1996; 78: 2543-2550.
  33. Wolfson AH, Wolfson DJ, Sittler SY, Breton L, Markoe AM, et al. A multivariate analysis of clinicopathologic factors for predicting outcome in uterine sarcomas. *Gynecol Oncol.* 1994; 52: 56-62.
  34. Abeler VM, Royne O, Thoresen S, Danielsen HE, Nesland JM, Kristensen GB. Uterine sarcomas in Norway. A histopathological and prognostic survey of a total population from 1970 to 2000 including 419 patients. *Histopathology.* 2009; 54: 355-364.
  35. Kurihara S, Oda Y, Ohishi Y, Iwasa A, Takahira T, Kaneki E, et al. Endometrial stromal sarcomas and related high-grade sarcomas: immunohistochemical and molecular genetic study of 31 cases. *Am J Surg Pathol.* 2008; 32: 1228-1238.
  36. Picerno TM, Wasson MN, Gonzalez Rios AR, Zuber MJ, Taylor NP, et al. Morcellation and the Incidence of Occult Uterine Malignancy: A Dual-Institution Review. *Int J Gynecol Cancer.* 2016; 26: 149-155.
  37. Mowers EL, Skinner B, McLean K, Reynolds RK. Effects of morcellation of uterine smooth muscle tumor of uncertain malignant potential and endometrial stromal sarcoma: case series and recommendations for clinical practice. *J Minim Invasive Gynecol.* 2015; 22: 601-606.
  38. Oduyebo T, Rauh-Hain AJ, Meserve EE, Seidman MA, Hinchcliff E, et al. The value of re-exploration in patients with inadvertently morcellated uterine sarcoma. *Gynecol Oncol.* 2014; 132: 360-365.
  39. Einstein MH, Barakat RR, Chi DS, Sonoda Y, Alektiar KM, et al. Management of uterine malignancy found incidentally after supracervical hysterectomy or uterine morcellation for presumed benign disease. *Int J Gynecol Cancer.* 2008; 18: 1065-1070.

