



Primary Biliary Cholangitis and its Diagnostic Challenges in a resource poor setting

Ijarotimi O^{1*}; Osasona EO¹; Betiku OA²; Adekanle O¹; Ndububa DA¹

¹Department of Medicine, Obafemi Awolowo University, Teaching Hospital, Ile-Ife, Osun State, Nigeria.

²Department of Morbid Anatomy, Obafemi Awolowo University, Teaching Hospital, Ile-Ife, Osun State, Nigeria.

*Corresponding Author(s): Oluwasegun Ijarotimi

Department of Medicine, Obafemi Awolowo University,
Ile-Ife, Osun State, Nigeria.

Tel: +2348038214351; Email: segjarot@hotmail.com

Abstract

Primary Biliary Cholangitis (PBC) is a chronic cholestatic disease of the liver. Due to the permanent cholestasis, fibrosis and cirrhosis eventually occur. It is said to be a rare disease in black Africans. We reported a case of Anti-Mitochondrial Antibody (AMA) negative PBC in a forty-one-year-old woman who fulfilled two out of the three diagnostic criteria. This case was reported because a diagnosis of PBC is very rare in our environment especially, AMA negative PBC which is indeed the first to be reported in our environment. Although, access to newer methods of AMA assay were not possible in the light of the resource-limited environment we practice in.

Received: Apr 01, 2022

Accepted: Apr 29, 2022

Published Online: May 02, 2022

Journal: Annals of Gastroenterology and the Digestive System

Publisher: MedDocs Publishers LLC

Online edition: <http://meddocsonline.org/>

Copyright: © Ijarotimi O (2022). *This Article is distributed under the terms of Creative Commons Attribution 4.0 International License*

Keywords: Primary biliary cholangitis; Anti-Mitochondrial Antibody; Anti-nuclear antibody.

Introduction

Primary biliary cholangitis (PBC) is a chronic cholestatic disease of the liver characterized by persistent and progressive cholestasis leading, eventually, to biliary fibrosis and cirrhosis [1]. It was previously known as primary biliary cirrhosis, but the name change was necessary to reflect the predominantly chronic inflammatory bile duct destructive changes seen until the latter stages when cirrhotic features will now mainly predominate [2]. The etiology is unknown although it has been presumed to be autoimmune in nature due to the presence of specific auto antibodies [3].

The pathophysiologic basis involves a complex interaction between environmental factors, exposure to foreign compounds and molecular mimicry in genetically predisposed individuals. It is an uncommon disease with a prevalence of 1.91–40.2 per 100,000 inhabitants in the developed countries [4] and even less common in Africans and populations of African descent [5]. It is commoner in females than males and occurs mostly between the 4th and 6th decade of life. Higher occurrence in first-degree relatives of patients compared to the general population underlines a strong genetic predisposition [6].



Cite this article: Ijarotimi O, Osasona EO, Betiku OA, Adekanle O, Ndububa DA. Primary Biliary Cholangitis and its Diagnostic Challenges in a resource poor setting. Ann Gastroenterol Dig Syst. 2022; 5(1): 1060.

Chronic fatigue is usually the first and commonest presentation followed by pruritus [7]. These two symptoms could be present for months to years while the liver function progressively deteriorate. Jaundice and features of cirrhosis are usually seen at the end stage of the disease.

The diagnosis of PBC is made when 2 out of 3 of the following criteria are met: Elevated alkaline phosphatase greater or equal to 1.5 times the Upper Limit of Normal [ULN]), elevated serum Anti-Mitochondrial antibody (titers $\geq 1:40$), and histological features consistent with PBC [8].

PBC is seldom seen in black African population, hence the reason for reporting this case.

Case report

A 41-year-old woman who was initially evaluated for obstructive jaundice at the surgical outpatient department. She was referred to the gastroenterology clinic by the surgeons due to non-response to cholestyramine and loratadine she was placed on, after abdominal imaging revealed no feature of surgical jaundice. She presented to the gastroenterology clinic on account of progressive fatigue noticed about 2 years ago, pruritus and excessive darkening of her skin of over a month duration. She also had a right upper abdominal pain, yellowness of the eyes with associated passage of dark brown urine about a week prior to her clinic presentation. There was no history of autoimmune diseases in the patient and first-degree relatives. There was also no history suggestive of chronic decompensated liver disease or liver cirrhosis. Jaundice and Hepatomegaly were the only positive findings on physical examination. The liver had a smooth surface and span of 16cm. There were no other peripheral stigmata of chronic liver disease. Her laboratory investigations showed the liver function assays as follows:

Liver function test	At Presentation at the GIT clinic	Two weeks after presentation	One month after presentation
Total bilirubin	51.3 $\mu\text{mol/l}$ (<17.1)	84 $\mu\text{mol/l}$	77 $\mu\text{mol/l}$
Conjugated bilirubin	35.9 $\mu\text{mol/l}$ (<8.6)	76 $\mu\text{mol/l}$	64 $\mu\text{mol/l}$
ALP	1324 i.u/l (42 – 141)	1210 i.u/l	758 i.u/l
GGT	930 i.u/l (5 – 50)	535 i.u/l	450 i.u/l
AST	71 i.u/l (0 – 40)	52 i.u/l	42 i.u/l
ALT	72 i.u/l (0 – 45)	61 i.u/l	53 i.u/l
Total Protein	73 g/l (60 – 80)	76 g/l	76 g/l
Albumin	38 g/l (35 – 50)	42 g/l	46 g/l
Globulin	35 g/l (18 – 36)	34 g/l	30 g/l

i.u: International unit, μmol : micromole

She was seronegative for Hepatitis B Surface Antigen (HBsAg), antibody to Hepatitis C Virus (Anti-HCV) and Human Immunodeficiency Virus (HIV). The packed cell volume was 33%, total white cell count was 5500/cmm and platelet count was 249,000/cmm. The prothrombin time was 14.1 seconds while the INR was 1. The serum cholesterol levels were elevated, the LDL-cholesterol was 3.61mmol/l (0 – 2.6mmol/l) while HDL-cholesterol was 1.73mmol/l (greater than 1.20mmol/l). Both the abdominal ultrasound scan and computed tomography scan revealed hepatomegaly with no coarsening of the echotexture nor distorted architecture, and no features suggestive of extrahepatic biliary obstruction. Markers of autoimmune liver disease, Anti-Nuclear Antibody (ANA) and Anti Mitochondrial Antibody (AMA) assays were also done, and they came out negative. At this point, based on the above investigations with

no clear diagnosis, liver biopsy had to be done on this patient and the result of the histology showed *an unaltered native liver architecture with preserved vascular relationships. The portal area was expanded by fibrosis and infiltrated by lymphocytes bridging the limiting plates. Many portal areas showed bile duct proliferation and many ducts show damaged epithelial lining cells and disrupted basement membranes in keeping with Ludwig stage III.*

With the elevated level of alkaline phosphatase above two times upper limit of normal on three occasions and the liver histological feature almost diagnostic of PBC, a diagnosis of PBC was made.

She was subsequently placed on Ursodeoxycholic acid at a dose of 15mg/kg but defaulted follow-up visits. She was interacted with through teleconsultation, and she attested to resolution of her symptoms as the main reason for her clinic default, although she claimed to have continued the medication during this period. Biochemical and/or histological improvements, if any, were not verifiable because of the default.

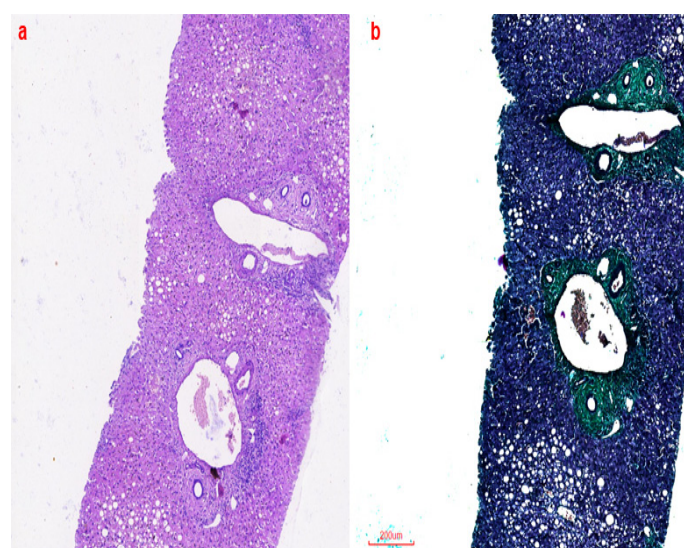


Figure 1: Showing liver histology with features of PBC, (1a); Hematoxylin and Eosin staining, (1b); Masson trichrome staining.

Discussion

Primary biliary cholangitis is an uncommon liver disease especially in Africans [5] and there has been no previous study about the prevalence in Nigeria. Search through Nigerian literature showed only one ever reported case of PBC in south-southern Nigeria by Agbo *et al* [9]. They described a patient that satisfied all the 3 criteria for diagnosing PBC. Even rarer, accounting for only about 5% of patients, are those with AMA negative type of disease [10] such as in our index patient. Therefore, a high index of suspicion is required to make such diagnosis in this environment.

We had a typical female patient in her fifth decade with the classic symptoms of fatigue, pruritus, and hyperpigmentation. Diagnosis of PBC in this case was made based on the clinical features and two of the three laboratory criteria including the histological features of PBC.

Her clinical presentation was like the case described earlier in Nigeria and typical of what is known of the symptomatology of PBC. There was also concordance between her symptoms and the advanced liver histologic features (fibrosis) she had. This is in keeping with previous findings that non-Caucasians

have more severe disease based on clinical and laboratory criteria [11] as was the case in our patient.

Anti-mitochondrial antibody is present in about 80% of PBC patients using the indirect immunofluorescence assay, the rest of the patients are negative and are simply labelled as having autoimmune cholangitis, now known as AMA negative PBC [12]. About 30%-50% of AMA negative PBC tests positive to ANA also using the indirect immunofluorescence assay [13]. Our patient tested negative to both AMA and ANA which made diagnosis a little difficult to arrive at. However, she fulfilled the other two components of the diagnostic criteria. To our knowledge, this is the first case of AMA negative PBC to be reported in Nigeria. The limitation experienced with respect to access to current and more advanced AMA and ANA assay methods meant that the patient could actually be AMA positive and/or ANA positive if the assay was done by some of these newer more sensitive methods. Immunoblotting and enzyme-linked immunosorbent assay for AMA are more specific than indirect immunofluorescence assay. Up to 95% of PBC patients becomes AMA positive when these newer methods are used to complement indirect immunofluorescence assay [10]. PBC specific ANA such as, anti-sp100, anti-gp120, antikelch-like 12, antihexokinase, if done, could have also helped in strengthening diagnosis of PBC in this patient.

In conclusion, primary biliary cholangitis has been reported in all races and ethnicities, it is likely underdiagnosed in our resource-challenged setting as routine autoimmune markers are almost not readily accessible in our practice. A search for an autoimmune process should be considered after excluding the common causes of cholestasis in our environment.

Declaration of Patient Consent

The authors certify that they have obtained all appropriate informed patient consent. In the form, the patient gave her consent for the clinical information and the included image to be reported in the journal. The patient understands that her name and initials will not be published, and due effort will be made to conceal her identity. However, anonymity cannot be guaranteed.

Conflicts of Interest

The authors declare no conflicts of interest.

References

1. Dyson JK, Hirschfield GM, Adams DH, Beuers U, Mann DA, et al. Novel therapeutic targets in primary biliary cirrhosis. *Nature Reviews Gastroenterology & Hepatology*.2015; 12: 147-158.
2. Cheung AC, Montano-Loza A, Swain M, Vincent C, Renner E, et al. Commentary time to make the change from “primary biliary cirrhosis” to “primary biliary cholangitis.” *Can J Gastroenterol Hepatol*.2022: 29.
3. Bowlus CL, Gershwin ME. The diagnosis of primary biliary cirrhosis. *Autoimmunity Reviews*. Elsevier. 2014; 13: 441-444.
4. Boonstra K, Beuers U, Ponsioen CY. Epidemiology of primary sclerosing cholangitis and primary biliary cirrhosis: A systematic review. *Journal of Hepatology*. Elsevier. 2012; 56: 1181-1188.
5. Metcalf J, James O. The geoepidemiology of primary biliary cirrhosis. *Seminars in Liver Disease*. Thieme Medical Publishers.1997; 17: 13-22.
6. Bach N, Schaffner F. Familial primary biliary cirrhosis. *Journal of Hepatology*. Elsevier. 1994; 20: 698-701.
7. Lindor KD, Gershwin ME, Poupon R, Kaplan M, Bergasa N, et al. Primary biliary cirrhosis. *Hepatology*. John Wiley & Sons.2009; 50: 291-308.
8. Lindor KD, Bowlus CL, Boyer J, Levy C, Mayo M. Primary Biliary Cholangitis. *Practice Guidance from the American Association for the Study of Liver Diseases*. *Hepatology*. 2019; 69: 394-419.
9. Agbo II, Ugiagbe RA, Omuemu CE, Eboikpomwen JO, Sefia U, et al. Primary biliary cirrhosis in a 37 year old Nigerian male: A case report. *Nigerian Journal of Gastroenterology and Hepatology*. 2018; 10: 35-8.
10. Oertelt S, Rieger R, Selmi C, Invernizzi P, Ansari AA, et al. A sensitive bead assay for antimitochondrial antibodies: Chipping away at AMA-negative primary biliary cirrhosis. *Hepatology*. John Wiley & Sons, Ltd. 2007; 45: 659-665.
11. Peters MG, di Bisceglie AM, Kowdley KV, Flye NL, Mun, et al. Differences between Caucasian, African American, and Hispanic patients with primary biliary cirrhosis in the United States. *Hepatology*. John Wiley & Sons Ltd. 2007; 46: 769-775.
12. Ozaslan E, Efe C, Gokbulut Ozaslan N. The diagnosis of antimitochondrial antibody-negative primary biliary cholangitis. *Clin Res Hepatol Gastroenterol*. *Clin Res Hepatol Gastroenterol*; 2016; 40: 553-561.
13. Sebode M, Weiler-Normann C, Liwinski T, Schramm C. Autoantibodies in autoimmune liver disease-clinical and diagnostic relevance. *Frontiers in Immunology*. *Frontiers Media SA*. 2018; 9: 609.