



Cytomegalovirus esophagitis in a patient on ocrelizumab therapy: A case report

Ashley A Miller^{1*}; Dani Mathew²; Charisse Huot³

¹Baycare Health System, Turley Family Health Center, 807 N Myrtle Ave Clearwater, FL 33755.

²Baycare Medical Group, 180 Patricia Ave Dunedin, FL 34698.

³University of South Florida-Morton Plant Mease Family Medicine Residency, Dr. Joseph A. Eaddy Family Medicine Research Center, 807 N. Myrtle Avenue Clearwater, FL 33755.

*Corresponding Author(s): Ashley A Miller

PGY1 Pharmacy Resident at Baycare Health System, Turley Family Health Center, 807 N Myrtle Ave Clearwater, FL 33755.

Tel: 727-467-2571, Fax: 727-467-2477;

Email: ashley.miller2@baycare.org

Abstract

Infection is the second most common cause of esophagitis, second only to gastroesophageal reflux, and represents a clinically important disorder. Immunosuppressed patients are at highest risk for infectious esophagitis, with candida, herpes simplex virus, and cytomegalovirus being the most common causative microorganisms. Immunosuppressing medications are a potential risk factor for infectious esophagitis. Here we provide a brief clinical review and present a case of concomitant oropharyngeal candida and cytomegalovirus esophagitis occurring in a patient with multiple sclerosis on ocrelizumab therapy.

Received: Feb 10, 2020

Accepted: Mar 31, 2020

Published Online: Apr 02, 2020

Journal: Annals of Gastroenterology and the Digestive System

Publisher: MedDocs Publishers LLC

Online edition: <http://meddocsonline.org/>

Copyright: © Miller AA (2020). *This Article is distributed under the terms of Creative Commons Attribution 4.0 International License*

Keywords: Cytomegalovirus; Esophagitis; Immunosuppressed; Ocrelizumab; Adverse drug reaction

Background

Cytomegalovirus (CMV) can infect multiple areas of the gastrointestinal tract, most commonly the esophagus and colon [1]. CMV esophagitis is the third leading cause of infectious esophagitis, after Candida and herpes simplex virus [2]. It occurs predominantly in immunocompromised patients (e.g. due to chemotherapy, corticosteroid use, HIV infection) or in the context of host microbiome alterations (e.g. antibiotic use). The diagnosis of CMV esophagitis is made using a combination of clinical history, endoscopic findings, and histologic features. Cytomegalovirus esophageal ulcers are typically either shallow or of intermediate depth with only a minority having deep depth

or heaped up appearance [3]. Overall, symptoms are more gradual when compared to esophagitis caused by HSV. The development of CMV esophagitis is associated with a poor overall prognosis [1].

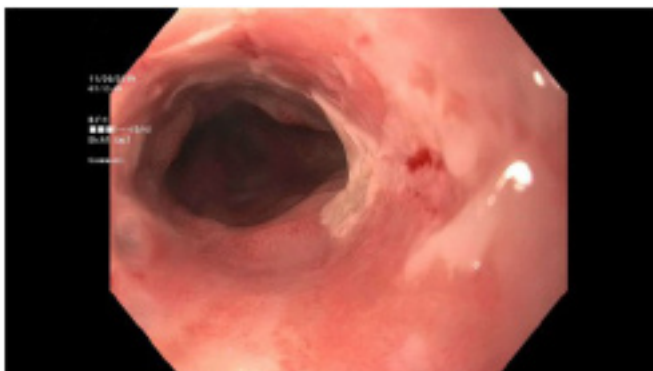
Ocrelizumab (Ocrevus) is a recombinant humanized monoclonal antibody indicated for the treatment of Multiple Sclerosis (MS) to include clinically isolated syndrome, relapsing-remitting disease, and active secondary progressive disease in adults. The exact mechanism by which Ocrevus works in multiple sclerosis is unknown, but is presumed to involve binding to CD20, a cell



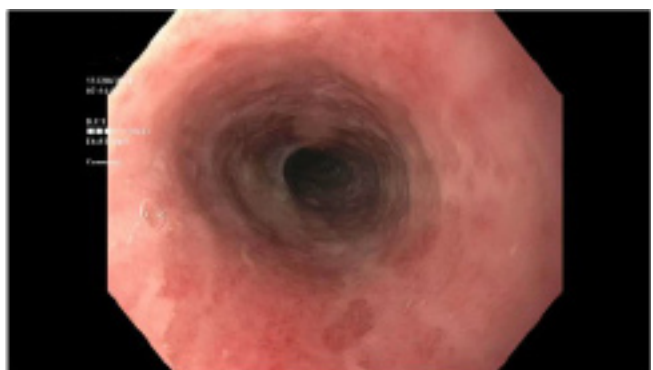surface antigen present on pre-B and mature B lymphocytes. Following cell surface binding to B lymphocytes, Ocrevus results in antibody-dependent cellular cytotoxicity and complement-mediated lysis. Known adverse reactions include an increased risk for malignancy and infection due to the immunosuppressing mechanism [4].

Case report

A 73 year old male with multiple sclerosis received ocrelizumab infusions over 22 months. Pre-infusion biochemical analysis and blood counts were normal and hepatitis B test was negative. He received standard dosing with two 300mg infusions separated by two weeks, followed by 600mg every six months thereafter. After four infusions, the patient presented with weakness, overall functional decline, and leukocytosis. Leukocyte count was 26,000 upon emergency room evaluation. Urinalysis was within normal limits. Chest x-ray did not show any signs of infiltrates or infection. A CT scan of the chest revealed an abnormal esophagus and further GI evaluation was recommended. An upper endoscopy showed severe, acute, esophagitis with necrotic tissue; biopsy identified *Candida* species. The patient was treated with 2 weeks of oral fluconazole. Following completion of fluconazole, the patient complained of continued dysphagia. A repeated EGD revealed worsening esophagitis and the histopathology revealed cytomegalovirus (Figure 1 & 2). Immunohistochemistry performed showed scattered CMV-positive cells, HSV I/II immunostaining was negative, and PAS-D was negative for fungal microorganisms. The patient was treated with one dose of intravenous ganciclovir followed by oral valganciclovir with resolution of symptoms upon completion of 21 day therapy. Ocrevus treatments were discontinued.



1. Lower third of esophagus



2. Middle third of esophagus

Figure 1,2: Endoscopic views of cytomegalovirus esophagitis.

Discussion

Although infectious esophagitis is a common clinical problem, to our knowledge, the present report represents the first well-substantiated case of cytomegalovirus esophagitis secondary to immunomodulation therapy with Ocrevus. Although CMV esophagitis is a disease most commonly associated with patients with AIDS, this case highlights additional risk factors associated with this rare disease. Specifically, patients at high risk include those who take immunosuppressive medications, such as ocrelizumab. Gross endoscopy findings may increase the clinical suspicion for CMV; while candida esophagitis exhibits white or pale yellow mucosal plaque lesions, lesions in CMV esophagitis have a shallow cratered appearance (similar to HSV esophagitis though usually much larger) [3]. This case, in addition to being a rare report of candida and CMV esophagitis within an immunosuppressed patient on a recombinant humanized monoclonal antibody, highlights the essential clinical pearl for providers that candida infection which does not exhibit symptom resolution within weeks of treatment with a systemic antifungal agent, requires further investigation to rule out other co-infections such as CMV or HSV.

Conclusion

This case serves as a reminder that persistent esophageal symptoms (e.g. odynophagia or dysphagia) following first-line antimicrobial therapy for esophagitis, particularly in immunocompromised hosts, merit further investigation with upper endoscopy to reveal underlying causes. It is important to consider and discuss the risks of medications such as ocrelizumab before initiating therapy. Additionally, it demonstrates the importance of early identification of possible complications of immunosuppressant therapies. Lastly, it emphasizes an indication for discontinuation of ocrelizumab use.

References

1. Hoversten P, Kamboj AK, Wu TT, Katzka DA. Risk Factors, Endoscopic Features, and Clinical Outcomes of Cytomegalovirus Esophagitis Based on a 10-year Analysis at a Single Center. *Clinical Gastroenterology Hepatology*. 2019.
2. Zakharia K, Tabibian JH. Infectious esophagitis in the immunosuppressed: Candida and beyond. *J Community Med (Reno)*. 2018; 1.
3. Hoversten P, Kamboj AK, Katzka DA. Infections of the esophagus: an update on risk factors, diagnosis, and management. *Dis Esophagus*. 2018; 31.
4. Ocrevus (Ocrelizumab) package insert. San Francisco, CA: Genentech, Inc. Nov 2019.