



# Removal of a Giant Lipoma of the Oral Cavity: A Case Report and Description of a Protocol of Treatment

**Yuri Slusarenko da Silva<sup>1\*</sup>; Maria da Graça Naclério-Homem<sup>2</sup>**

<sup>1</sup>School of Dentistry, UniFG University Center (Faculty of Guanambi), Bahia/Brazil.

<sup>2</sup>Department of Oral & Maxillofacial Surgery, Traumatology and Prosthesis, Faculty of Dentistry of the University of São Paulo, Brazil.

**\*Corresponding Author(s): Yuri Slusarenko da Silva**

Professor, School of Dentistry, UniFG University Center (Faculty of Guanambi), Bahia/Brazil.

Avenida Pedro Felipe Duarte 4911 São Sebastião – Guanambi/Bahia. 46430-000 Brazil.

Tel: +55-11-95249-6124; Email: yu.slu@hotmail.com

## Abstract

**Introduction:** The lipoma is the most common benign neoplasm of mesenchymal origin in human patients and the oral cavity may be rarely affected. The definitive treatment of this lesion is the surgical excision in one piece.

**Case report:** A 40-year-old healthy woman presented with a large painless swelling in the left lower vestibule, which had slowly increased in size during the last two years and the mass was suspected to be a lipoma. The disease was removed in one piece under local anesthesia, without interurrences. The histological examination revealed a simple lipoma and there was no clinical signs two years after the surgery. The protocol of treatment of the present case report is a safe procedure and a reasonable way to treat patients with giant lipomas of the oral cavity, especially in Public Health Services of developing countries where the resources may be limited.

Received: Sep 10, 2020

Accepted: Oct 08, 2020

Published Online: Oct 13, 2020

Journal: Annals of Dentistry and Oral Health

Publisher: MedDocs Publishers LLC

Online edition: <http://meddocsonline.org/>

Copyright: © Silva YS (2020). *This Article is distributed under the terms of Creative Commons Attribution 4.0 International License*

**Keywords:** Lipoma; Oral Cavity; Oral Surgical Procedures; Maxillofacial Surgery; Benign Neoplasms; pathology.

## Introduction

The lipoma is the most common benign neoplasm of mesenchymal origin in human patients, which is composed mainly of fat tissue and is usually found in the extremities of the body, but the maxillofacial region may be rarely affected [1,2]. The lipoma of the oral cavity is even rarer, accounting for about 1-4% of this tumor [3,4].

Lipoma of the oral cavity presents as a slow-growing painless mass of soft consistency and is usually found in the buccal mucosa, floor of the mouth, tongue or lips [1-4], but other unusual

sites may also be affected [5]. Depending on its histological features, they may be classified as simple lipoma, fibrolipoma, spindle cell lipoma, intramuscular or infiltrating lipoma, angiolipoma, salivary gland lipoma, pleomorphic lipoma, myxoid lipoma, and atypical lipoma [4,6-8].

The definitive treatment of the lipoma of the oral cavity is the surgical excision of the tumor in one piece. The present case report aims to describe the protocol of treatment of a giant lipoma located in the buccal mucosa of the oral cavity.

**Cite this article:** Silva YS, Naclerio-Homem MG. Removal of a Giant Lipoma of the Oral Cavity: A Case Report and Description of a Protocol of Treatment. *Ann Dent Oral Health*. 2020; 3(1): 1022.



**Case report**

A 40-year-old healthy woman presented with a painless swelling in the left lower vestibule, which had slowly increased in size during the last two years. She reported difficulty with eating and speaking.

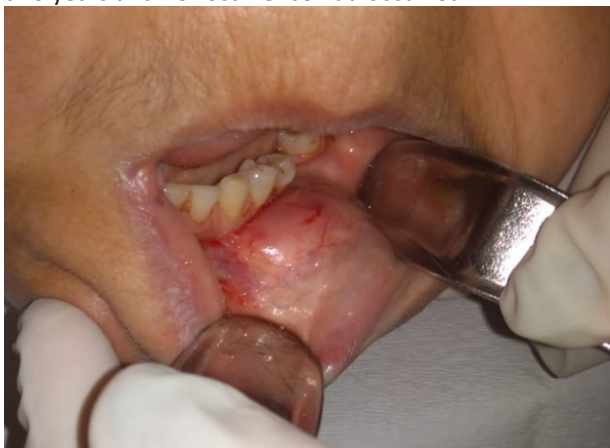On examination, a large swelling was noted in the buccal sulcus at the region of the lateral incisor to the first molar. There were no signs of inflammation or infection (Figure 1). The swelling appeared to be soft at palpation and the overlying mucosa had a normal color. The neighboring teeth did not show any mobility and the panoramic radiograph showed no bony abnormalities nor root resorption. The submandibular lymph nodes were not enlarged. The mass was suspected to be a lipoma.

**Protocol of treatment**

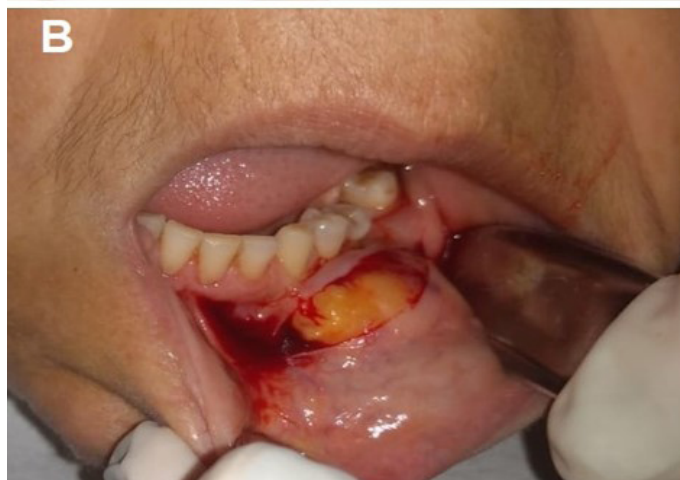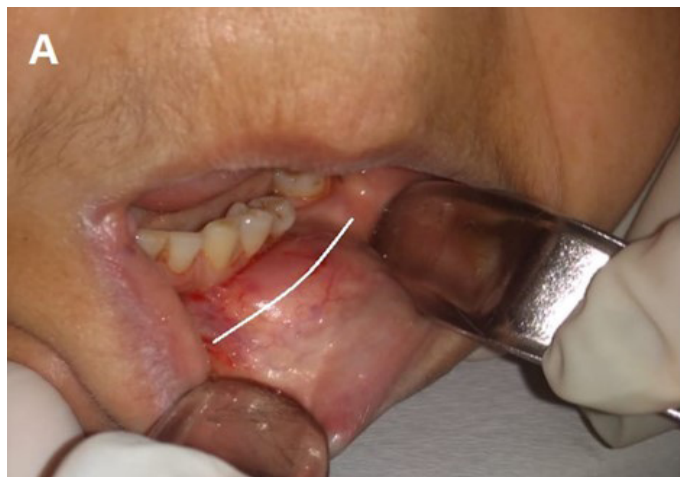The patient was treated in the ambulatory. She received a preoperative dose of 8 mg of dexamethasone one hour before surgery. The inferior alveolar nerve, buccal nerve, and mental nerve of the left side are individually blocked with 1.8 ml of 2% lidocaine with 1:100.000 epinephrine and a single incision is performed on the mucosal plane over the mass and a few millimeters beyond (Figures 2 A and B). The border of the oral mucosa is grasped with an Adson forceps and a blunt dissection is performed around the entire tumor with a Metzenbaum scissor. Care must be taken to prevent the rupture of the tumor capsule with the scissor's tips. The tumor is pulled out with a Kelly forceps and dissected from beneath to be removed in one piece (Figure 3). The oral mucosa is repositioned and closed with a running suture. A Penrose drain may be left in place for 24-72 hours within the tissue to collect blood from the dead space, but it was not done in our patient.

The surgical specimen had an oval shape and a gelatinous consistency, measuring about 35 mm. It was covered with a thin capsule, which showed the yellowish substance of the tumor. The histological examination revealed a well-defined tumor composed of mature adipocytes covered by a thin fibrous capsule. Some clusters of mature adipocytes were surrounded by collagen fibers. There was no invasion of tumor cells tumor beyond the fibrous capsule. The definitive diagnosis was simple lipoma (Figure 4).

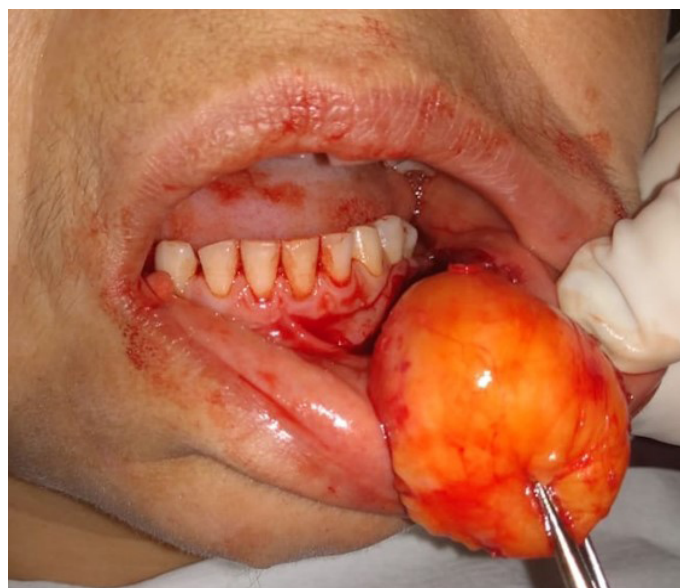
After the surgery, the patient was prescribed with 500 mg of Amoxycillin for seven days, and 600 mg of Ibuprofen and 500 mg of Acetaminophen for 4-5 days. The patient was followed up for two years and no recurrence had occurred.



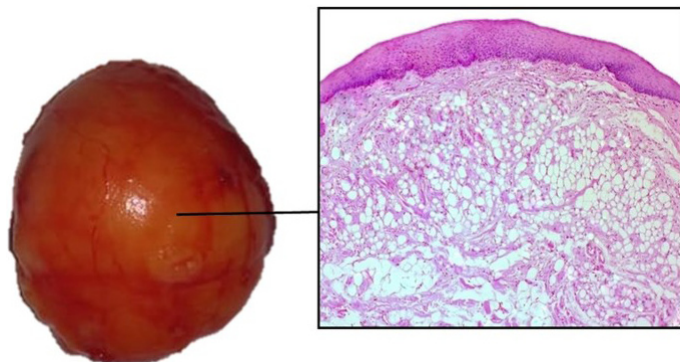
**Figure 1:** Large and painless mass of soft consistency in the left buccal mucosa, suggesting a lipoma. It was possible to delimit the area of the mass with the fingers of the examiner.



**Figure 2:** Surgical technique. (A) Slightly curved incision on the mucosal plane over the mass, and a few millimeters beyond (continuous white line). (B) After the incision, it is possible to see the yellowish substance of the tumor.



**Figure 3:** Tumor grasped with a Kelly hemostatic forceps. From that surgical step, the tumor must be dissected from beneath.



**Figure 4:** Oval surgical specimen with a resistant capsule of smooth and transparent surface, showing the yellowish substance of the tumor. The histological exam revealed several clusters of mature adipocytes covered by thin a fibrous capsule (Hematoxylin and Eosin staining, 100x).

### Discussion

Slow-growing masses involving the oral cavity, like in the present case report, are more likely to be less aggressive lesions. However, masses of rapid growth must raise suspicion of being a malignant tumor. In such cases, the primary surgical excision of the tumor is not recommended without a preoperative histological diagnosis to define what best definitive treatment should be followed [9,10]. Other complementary exams may be needed [10].

The preoperative surgical planning may include a Computed Tomography (CT) scan for soft tissues or a Magnetic resonance imaging (MRI) to define the exact extension of the tumor. A CT scan can be especially helpful in the diagnostic work up of lipoma because fat is the only soft tissue with a density lower than water [11], but the CT was not necessary in the present case report because it was possible to delimit the tumor on palpation, which appeared to be superficial to the mandible.

The patient of this report was treated in the Public Health Service of Brazil and, unfortunately, some imaging exams such as those mentioned above are not easily available or patients have to wait for several months to be submitted to a certain exam. Additionally, the cost of the exam is considerably high in private centers. In this respect, we evaluated only a panoramic radiography to rule out osseous diseases and based our diagnostic hypothesis and treatment plan mainly on the clinical evaluation.

Depending on the location of the lipoma, some vital structures may be damaged and patients must be aware of that. During the removal of the giant lipoma of the present case, some branches of the mental nerve had to be carefully separated from the capsule of the tumor and the patient developed a postoperative paresthesia that spontaneously recovered 3 months after the surgery.

Lipomas may recur if incompletely excised [11]. Such recurrences, however, must be meticulously evaluated because a low-grade liposarcoma may be misdiagnosed as a lipoma [12]. Therefore, we recommend a clinical follow-up of, at least, 5 years a recent CT scan or MRI should be evaluated in each postoperative consultation, if feasible.

Surgical excision of a giant lipoma of the oral cavity is a safe procedure and the treatment presented in the present report is a reasonable protocol to treat patients, especially in Public Health Services of developing countries where the resources may be limited. If lipomas recur one has to consider a low-grade liposarcoma, which is easily misdiagnosed as a simple lipoma [12].

### References

1. Naruse T, Yanamoto S, Yamada S, Rokutanda S, Kawakita A, et al. Lipomas of the oral cavity: clinicopathological and immunohistochemical study of 24 cases and review of the literature. *Indian J. Otolaryngol. Head Neck Surg.* 2015; 67: 67-73.
2. Neville B, Damm DD, Allen C, Chi A. *Oral and Maxillofacial Pathology*. 4th ed. St. Louis, Mo: Saunders/Elsevier, 2016.
3. De Visscher JGAM. Lipomas and fibrolipomas of the oral cavity. *J. Maxillofac Surg.* 1982; 10: 177-181.
4. Fregnami ER, Pires FR, Falzoni R, Lopes MA, Vargas PA. Lipomas of the oral cavity: clinical findings, histological classification and proliferative activity of 46 cases. *Int. J. Oral Maxillofac. Surg.* 2002; 32: 49-53.
5. Gargade CB, Desai, A. Y. Lipoma of Hard Palate: Commonest Tumour at Rarest Site. *Indian J Otolaryngol. Head Neck Surg.* 2019; 71: 27-28.
6. Davis GB, Stoelinga PJW, Tideman H, Bronkhorst F. Angiolipoma of the hard palate. *J Max-Fac Surg.* 1976; 4: 618-621.
7. Kaorey N, Mandale M, Bhavthankar J. Adipocytic tumors of orofacial region: Clinicopathologic appraisal of ten cases with a review of its variants. *J. Oral Maxillofac Pathol.* 2020; 24: S115-S119.
8. Said-Al-Naief N, Zahurullah FR, Sciubba JJ. Oral spindle cell lipoma. *Ann Diagn Pathol* 2001; 5: 207-215.
9. Ishikawa S, Kato Y, Kabasawa T, Yoshioka C, Kitabatake K, et al. A case of myeloid sarcoma of the mandibular gingiva as extramedullary relapse of acute myeloid leukemia. *Oral Maxillofac. Surg.* 2020; 24: 121-126.
10. Slusarenko da Silva Y, Naclério-Homem MG. Myeloid sarcoma on the temporal region before the onset of the acute myeloid leukemia: an extremely rare case report. *Oral Maxillofac Surg.* 2020.
11. Barns L. *Surgical Pathology of the Head and Neck*. 3rd ed. New York: Informa Healthcare, 2009.
12. Wenig BM, Weiss SW, Gnepp DR. Laryngeal and hypopharyngeal liposarcoma. A clinicopathologic study of 10 cases with a comparison to soft-tissue counterparts. *Am J Surg. Pathol.* 1990; 14: 134-141.