



Prognosis in Impacted Incisors Cases: Utility of 3D Imaging

Hicham BENYAHIA^{1*}; Youssouf OUÉDRAOGO²; Saliha CHBICHEB³; Fatima ZAOU⁴

¹Associate Professor in Orthodontic Department, Mohammed V University in Rabat, Morocco

²Ouagadougou University, Yalgado Ouédraogo CHU, Ouagadougou, Burkina Faso

³Professor in Oral Surgery Department, Mohammed V University in Rabat, Morocco

⁴Senior Professor and Head of orthodontic Department, Mohammed V University in Rabat, Morocco

*Corresponding Author(s): Hicham Benyahia

Department of Orthodontics, Dental Consultation and Treatments Center – Faculty of Dentistry, Mohammed V University in Rabat, Morocco.

Email: hicham.benyahia@um5.ac.ma

Abstract

Management of impacted incisors is a serious challenge to the clinician. The etiological and morphological diagnosis is decisive for specifying the prognosis, especially if the incisor discloses crown or root defects, that are caused most of times by early trauma.

Preoperative prescription of 3D imaging is recommended to specify the external morphology and structural defects of the included incisor, which certainly helps establishing an appropriate treatment plan.

A rare case of maxillary impacted incisor with dilacerated crown is reported. Surgical orthodontic traction failed to move the tooth and CBCT revealed later pronounced crown dilacerations, likelihood ankylosis areas with total absence of alveolar bone and periodontal ligament on labial side, leading to the decision of extraction.

Received: Apr 15, 2020

Accepted: May 29, 2020

Published Online: Jun 02, 2020

Journal: Annals of Dentistry and Oral Health

Publisher: MedDocs Publishers LLC

Online edition: <http://meddocsonline.org/>

Copyright: © Benyahia H (2020). *This Article is distributed under the terms of Creative Commons Attribution 4.0 International License*

Keywords: Impacted upper central incisor; Ankylosis; Dilacerations; CBCT

Introduction

Management of an impacted incisor is a challenging situation, with aesthetic and biomechanical issues for traction and placement on the dental arch [1]. However, it's probably more difficult to set an etiological and morphological diagnosis and define the prognosis, especially if the incisor discloses some crown or root defects.

Preoperative prescription of 3D imaging such as cone beam computed tomography (CBCT) or CT Dentascan, is recommended to specify the external morphology and structural defects

of the impacted incisor, which certainly helps establishing an appropriate treatment plan.

Prognosis factors

It is well known that traumatic injuries to primary dentition may interfere with the development of permanent dentition. A blow to deciduous teeth can affect the permanent dentition by slowing, or even completely arresting further development [1-4].



The repercussions of the trauma are dependent on several factors: the respective degree of maturation of the temporary and permanent teeth, the position of these two teeth in relation to one another and the direction of the blow [4-7].

When the trauma occurs very early, while the crown of the permanent incisor is forming, between 1 and 3 years of age, formation of the enamel organ responsible for the edification of the underlying germ's crown can be disrupted. We can observe enamel hypoplasia with surface discoloration or a break-up of the embryonic structures, giving rise to multiple odontomas or, again, a little later during maturation of the permanent germ, deformation of the developing dental tissues, with a defect in the crown of the permanent tooth [4,5].

It should be furthermore noted that at this age because bone is less resistant than the dental tissues, the trauma is easily transferred to the permanent germ [2,3].

Between 2 and 4 years of age, intrusion is the movement most frequently observed in temporary incisors following a trauma. At this stage, the trauma occurs after the crown is complete, the crown may be displaced relative to the root, that may stop its formation, leaving a permanently shortened root. More frequently, root formation continues, while adaptation of the Hertwig sheath to the adjacent structures gives rise to a bend in the root, which can lead to corono-radicular angulation [4-7].

Different shapes of the traumatized impacted permanent incisors have been widely described with a semantic confusion [2-10]. Two terms that appear to be fundamentally different, "dilacerated" of a more histological nature and "crown root angulation" which is a simple physical description. These two conditions, however, meet in the definition most reported by authors:

Dilaceration is characterized by an abrupt deviation of the axial angulation of a tooth; this can occur anywhere along the crown, cemento-enamel junction, root, or apex [11-13].

3D Crown and root defects

A very early trauma, leads to a crown dilacerated tooth which is a rare condition. The crown is lingually oriented relative to the root. Several histological defects are observed as a "calcio-traumatic or distortion line" evident on x rays and severe enamel hypoplasia associated with ankylosis area, not allowing tooth conservation [4,5,14].

The angulated or "sickle-shaped" tooth is related to a later trauma, and displays a normal crown with a characteristic orientation: upwards and forwards, the incisor edge is in contact with the buccal cortex towards the anterior nasal bone. The root follows the shape of the palatal cortex, terminating its growth with apical hook. It is a relatively frequent deformity, as attested by the large number of cases reported, and usually described as generic "dilacerated incisor" [2-10]. The prognosis is largely favorable, for surgical-orthodontic traction, sometimes requiring periodontal and apical surgery [15,16].

Therefore a distinctive classification is necessary, and meanwhile talking recently about "crown dilacerated" and "root dilacerated" incisors is reasonable [16-20].

In this regard, a precise diagnosis of a 3 dimensional structure cannot be made on 2-dimensional conventional x-rays, especially in the buccolingual plane which is an inherent limitation of the radiograph. To overcome these limitations, cone beam

computed tomography (CBCT) or CT scan is recommended to aid in preoperative diagnosis and optimal treatment planning [3,13,14,17].

A case presentation

A 10-year-old boy patient referred to Oral Surgery Department (Consultation and *Dental Treatments Center (CCDT)* related to Mohammed V University in *Rabat, Morocco*). The chief complaint was delayed eruption of the upper permanent central incisor and the temporary incisor was still present. The medical history of the patient revealed good general health. The boy had suffered a traumatic injury to the anterior oral region before 3 years of age.

The stomatologist prescribed a panoramic (Figure 1) which reveals a compound odontoma under the highly impacted incisor. The odontoma appears to be an obvious etiology of the impaction, given that the x ray did not show any obvious defects on the retained incisor. The option of surgical extraction was chosen, to remove this block, predicting spontaneous eruption. The patient was then oriented to orthodontic consultation.

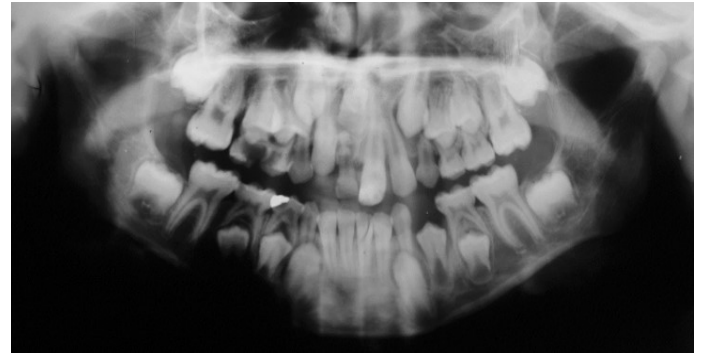


Figure 1: Pretreatment panoramic radiograph revealed compound odontoma under impacted maxillary incisor.

No spontaneous eruption occurred, and the young patient was referred 3 months later for orthodontic management.

The intraoral examination showed the presence of permanent incisors 12, 21 and 22 (Figure 2 a-c). The 21 had slightly abnormal, curved and protruded crown. At the vestibule top, mucosa palpation indicated a bulge in the upper anterior area where the included incisor was located.

The occlusal examination, noted a bilateral Angle class I relationship with a slight alveolar and lip protrusion. The lower tooth arch discrepancy is minor.

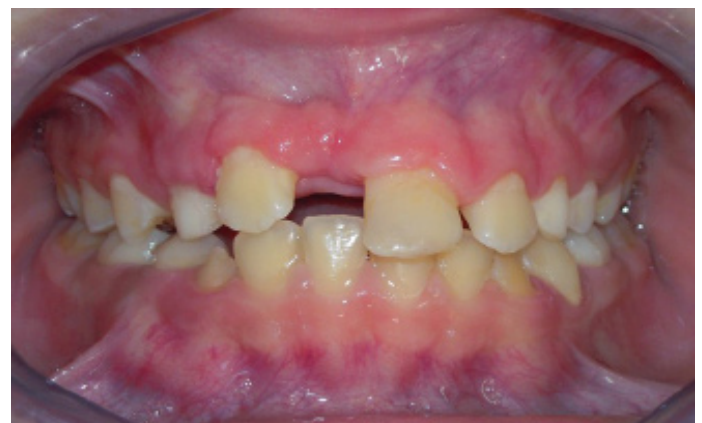

Figure 2a: Pretreatment intraoral frontal photograph showing the noneruption of the maxillary right central incisor

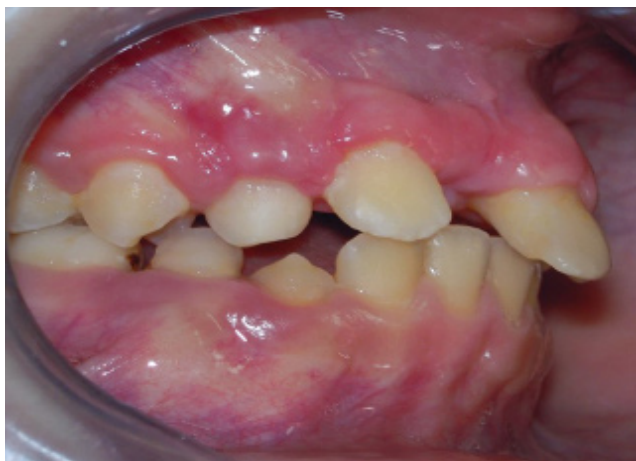

Figure 2b: Pretreatment intraoral right lateral photograph showing class I occlusal relationship

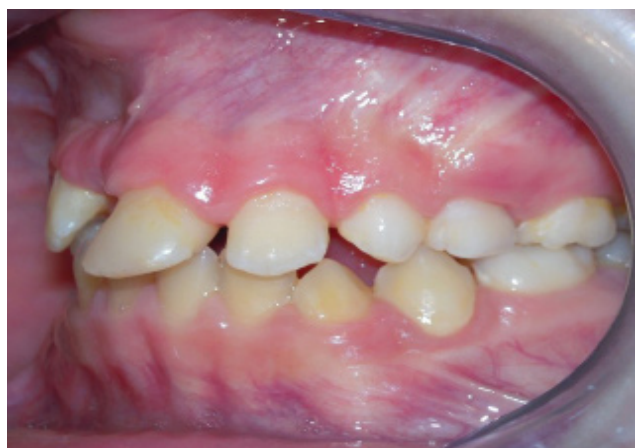

Figure 2c: Pretreatment intraoral left lateral photograph showing class I occlusal relationship

Lateral cephalometric radiograph confirmed clinical finding with hyperdivergent skeletal Class I, and revealed sagittal side of the impacted incisor, with root shortening beside nasal crest (Figure 3).

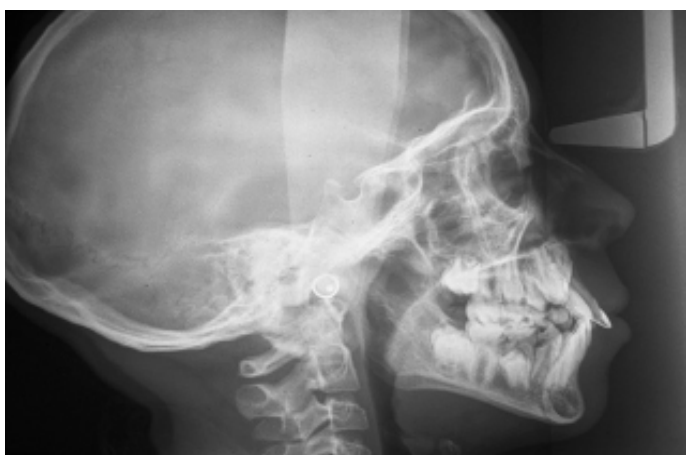

Figure 3: Pretreatment lateral cephalometric radiograph revealed anomalous sagittal position of the impacted incisor.

It was not possible to obtain more information regarding crown and tooth morphology, and at this stage, we have not seen necessary to prescribe other radiographs.

The option of surgical-orthodontic traction of the incisor was chosen and explained to the parents, being also fully aware of the uncertain prognosis. Ankylosis occurs frequently in such

situations.

Treatment objective was at first, to regain slight more space for eruption of the impacted tooth and create anchorage for the orthodontic traction by placing transpalatal arch soldered to upper molars bands. The upper arch was bonded completely, and leveled respectively with NiTi and stainless steel rectangular archwires: .016", .016x.022", and .018x.025", with a NiTi open coil spring between 12 and 21. A period of 4 months was sufficient to create enough space for the upper incisor [1].

Because of the high position of the impacted tooth, a full flap closure method was chosen for the closed eruption technique. A full-thickness flap was raised and after removing minimal alveolar bone, the labial surface of the crown was exposed. A button was directly bonded to the dilacerated incisor and a 0.010-inch wire ligature was twisted from the attachment towards the archwire. An elastomeric module was applied and connected to the archwire.

The force was activated monthly to achieve a physiological direction of tooth eruption [4-6].

After six months of orthodontic traction, we noticed no change in the position of the dilacerated incisor, with accentuation of undesirable effects on the dental arch: flaring and intrusion of incisors. Which is a common sign of ankylosis.

A CBCT was prescribed at this stage due to the absence of tooth displacement (Figure 4 a-g).

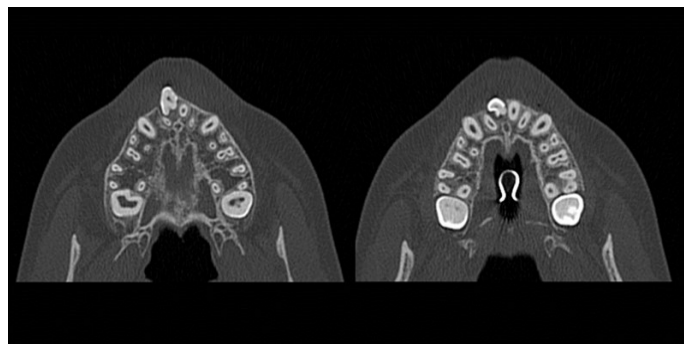


Figure 4a: axial views of the cone beam computed tomography (CBCT), at level of impacted incisor crown revealed severe defects.

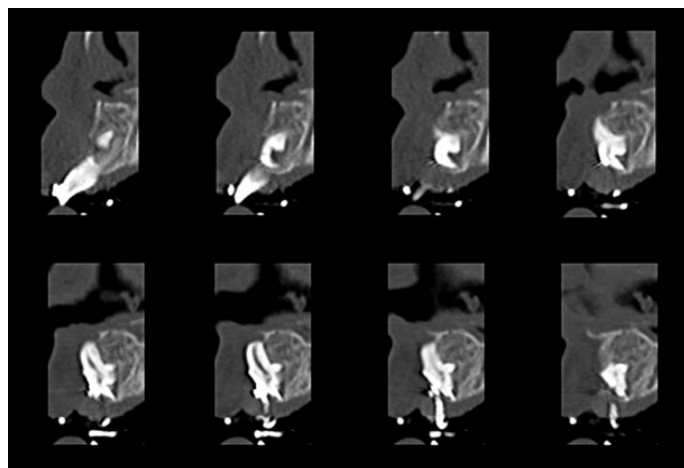


Figure 4b: Set of sagittal cross-sections within impacted incisor on the CBCT, showing crown dilacerations

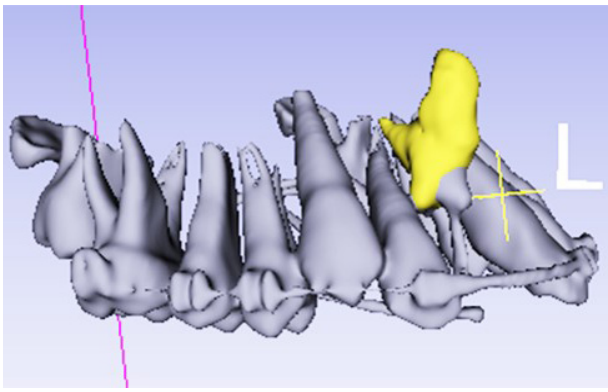


Figure 4c: CBCT based 3D surface rendering after segmentation of the upper arch giving a better visibility of location and anatomy of the impacted incisor.

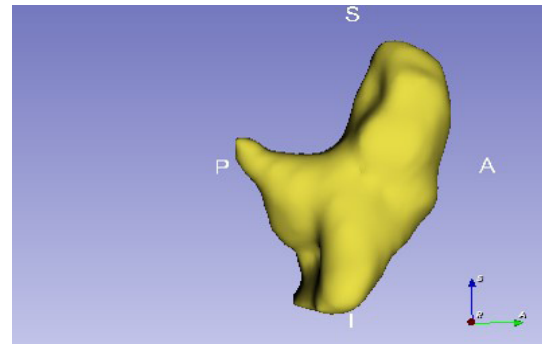


Figure 4g: Right lateral view: CBCT based 3D surface rendering after segmentation of the impacted incisor.

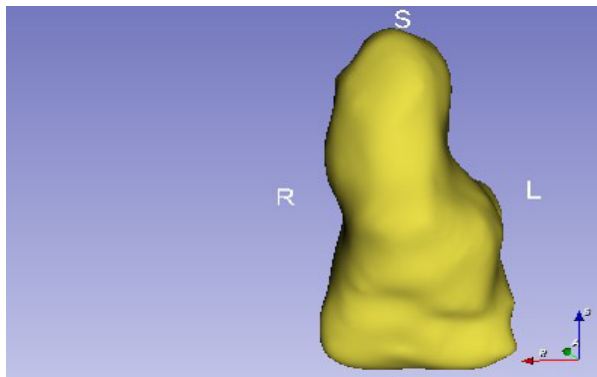


Figure 4d: Front view: CBCT based 3D surface rendering after segmentation of the impacted incisor.

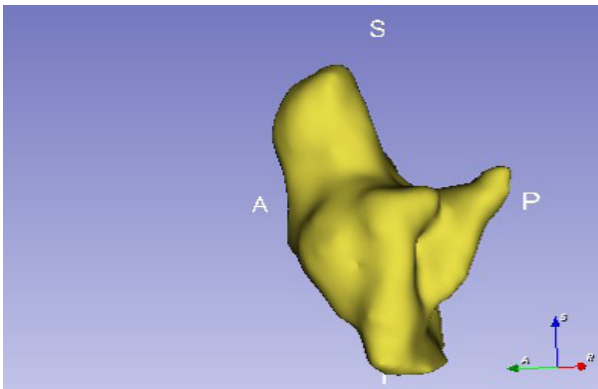


Figure 4e: Left lateral view: CBCT based 3D surface rendering after segmentation of the impacted incisor.

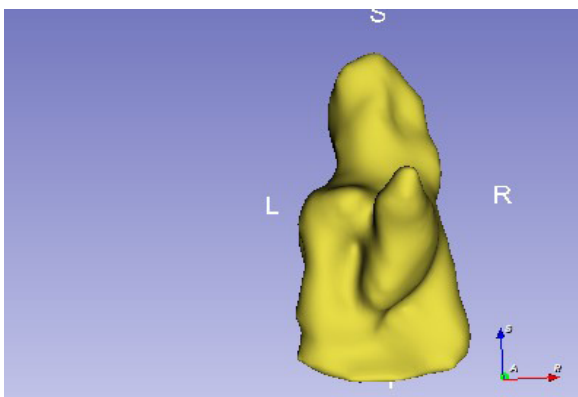


Figure 4f: Palatal view: CBCT based 3D surface rendering after segmentation of the impacted incisor.

The CBCT showed severe crown and root defects, characteristic signs of a dilaceration, with enamel hypoplasia and calcio-traumatic line. Likelihood ankylosis areas are observed with total absence of alveolar bone and periodontal ligament on labial side. Such histological damages are generally too severe to allow tooth conservation.

A non-traumatic extraction was carried to preserve alveolar bone. The extracted tooth revealed serious defects (Figure 5a & b), with enamel nodules and bone to dentin interfaces.

A prosthetic tooth was adapted and attached to the archwire after bonding an orthodontic bracket on the labial face. This temporary solution ensure aesthetic requirement while waiting the completion of orthodontic treatment.

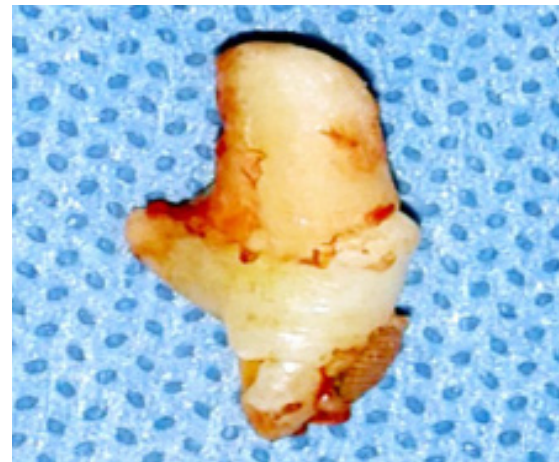


Figure 5a: Right lateral side of the extracted incisor.

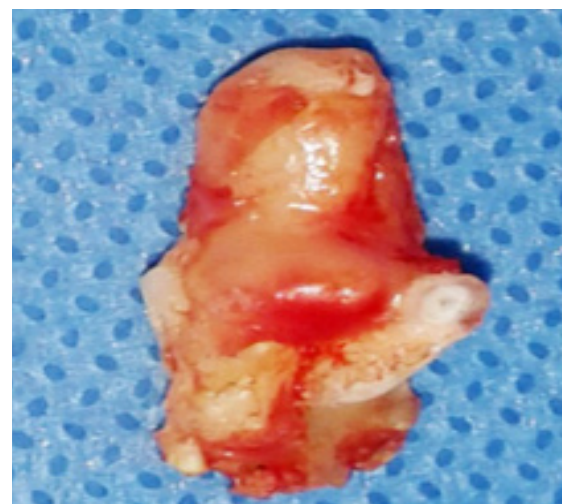


Figure 5b: Palatal side of the extracted incisor.

A bonded Maryland bridge is recommended to replace missed incisor, until the end of the vertical skeletal growth at minimum age of 18. An implant restoration could then be performed.

Discussion

The diagnosis of incisor dilaceration is done on x rays, searching characteristic signs. Conventional orthodontic x rays are quite limited. Therefore, prescription of 3D imaging in preoperative stages, would be highly recommended in case of impacted incisor, which certainly avoids misdiagnosis and helps establishing an appropriate treatment plan [3,13-17].

The present case described a rare situation of maxillary impacted incisor with dilacerated crown. Surgical orthodontic traction of the tooth failed, since the treatment plan is inappropriate, following a preoperative morphological misdiagnosis. a CBCT prescription would have enabled an early diagnosis and a proper therapeutic decision: immediate extraction of the impacted incisor, and maintain of the temporary incisor as long as possible to keep the bone capital up to the placement of an implant.

Ankylosis is the main issue, namely the absence of a translucent line between crown/root and bone. It has to be checked during the diagnostic stage on CT scans [4-6].

Tooth mobility and percussion sound could be assessed during surgical procedure. However, the only decisive diagnosis is the "orthodontic traction test" on the impacted tooth. If traction mechanics trigger no response, the conservative treatment option must be reviewed.

The most commonly mentioned therapeutic solution for crown dilacerated incisors in literature is surgical extraction of the malformed incisor [4,5,14] and substitution with Maryland-bridge, prosthetic/implants devices or transpositioned tooth.

Extraction of the ankylosed impacted tooth leads often to a major bone loss, which can complicate prosthetic rehabilitation.

Anterior auto-transplantation of premolars should be considered as an alternative solution. it represents an inherent potential for bone induction and reestablishment of a normal alveolar process [7,8].

Conclusion

3D imaging such a CBCT is highly recommended to clarify morphological and structural diagnosis and to assess prognosis in impacted incisors cases. The reported case described a rare situation of maxillary impacted incisor with dilacerated crown. Such cases present in most of times, non-viable tooth defects, leading to the extraction.

References

- Chandhoke TK, Agarwal S, Feldman J, Shah RA, Upadhyay M, et al. An efficient biomechanical approach for the management of an impacted maxillary central incisor. *American Journal of Orthodontics and Dentofacial Orthopedics*. 2014; 146: 249-254.
- Crescini A, Doldo T. Dilaceration and angulation in upper incisors consequent to dental injuries in the primary dentition: orthodontic management. *Progress in Orthodontics*. 2002; 3: 29-41.
- Sharma S, Grover S, Srivastava D, Sharma V, Mittal M. Endodontic and esthetic management of a dilacerated maxillary central incisor having two root canals using cone beam computed tomography as a diagnostic aid. *Case Rep Dent*. 2014; 861942: 7.
- Chokron A. Strategies for treating an impacted maxillary central incisor. *Int Orthod*. 2010; 8: 152-76.
- Profitt WR, Fields HW, Sarver DM. The etiology of orthodontic problems chapitre. IN: Profitt WR, Fields HW, Sarver DM. *Contemporary orthodontics*. 4th Edn. Mosby Elsevier, St. Louis. 2007; 135-41.
- Andreasen JO, Flores MT. Injuries to developing teeth. In: Andreasen JO, Andreasen FM, Andreasen L, editors. *Textbook and color atlas of traumatic injuries to the teeth*. Oxford: Blackwell Munksgaard; 2007: 542-576.
- Topouzeli N, Tsaousoglou P, Pisoka V, Zouloumis L. Dilaceration of maxillary central incisor: A literature review. *Dental traumatology*. 2010; 26: 427-433.
- Kuvvetli SS, Seymen F, Gencay K. Management of an unerupted dilacerated maxillary central incisor: a case report. *Dental Traumatology*, 2007; 23: 257-261.
- Farronato G, Maspero C, Farronato D. Orthodontic movement of a dilacerated maxillary incisor in mixed dentition treatment. *Dent Traumatol*. 2009; 25: 451-456.
- Chashu S, Becker T, Becker A. Impacted central incisors: Factors affecting prognosis and treatment duration. *American Journal of Orthodontics and Dentofacial Orthopedics*. 2015; 147: 355-362.
- British Standards Institution. *Glossary of terms relating to dentistry*. London, United Kingdom: British Standards Institution. 1983.
- Campbell CM, DiBiase A, Fleming PS. Concomitant dilaceration, transposition, and intraosseous migration: Report of a patient treated with maxillary canine-central incisor substitution. *American Journal of Orthodontics and Dentofacial Orthopedics*. 2014; 146: 514-521.
- Walia PS, Rohilla AK, Choudhary S, Kaur R. Review of Dilaceration of Maxillary Central Incisor: A Multidisciplinary Challenge. *Int J Clin Pediatr Dent* 2016; 9: 90-98.
- Tozoglu S, Yolcu U, Tozoglu U. Developmental disturbance of maxillary lateral incisor after trauma. *Dental Traumatology*. 2007; 23: 85-86.
- Wei YJ. Esthetic periodontal surgery for impacted dilacerated maxillary central incisors. *American Journal of Orthodontics and Dentofacial Orthopedics*. 2012; 142: 546-551.
- Chang NY, Park JH, Kim SC, Kang KH, Cho JH, et al. Forced eruption of impacted maxillary central incisors with severely dilacerated roots. *Am J Orthod Dentofacial Orthop*. 2016; 150: 692-702.
- Huang YH, Kuo PJ, Lin JJ, Roberts EW. Recovery of an Inverted Maxillary Central Incisor Impaction with a Dilacerated Root. *J Digital Orthod*. 2019; 53: 4-25.
- Plakwicz P, Kapuścińska A, Kukuła K, Czochrowska EM. Pulp Revascularization after Repositioning of Impacted Incisor with a Dilacerated Root and a Detached Apex. *J Endod*. 2015; 11: 1-6.
- Arango E, Plaza SP, Chaves AM, Melsen B. Can forces be applied directly to the root for correction of a palatally displaced central incisor with a dilacerated root? *Am J Orthod Dentofacial Orthop*. 2019; 156: 275-282.
- Tan C, Ekambaram M, Yiu CKY. Prevalence, characteristic features, and complications associated with the occurrence of unerupted permanent incisors. *PLoS ONE*. 2018; 13: e0199501.