



Effect of Temporary Bite Raising with Light Cured Orthodontic Band Cement and Acrylic Bite Plane on the Electromyographic Response of Masticatory Muscles

Rama Raji Sankaranarayanan¹; Aravind Kumar Subramanian^{2*}

¹Resident, Department of Orthodontics, Saveetha Dental College and Hospitals, Saveetha Institute of Medical and Technical Sciences (SIMATS), Chennai-600-077.

²Head of the Department, Department of Orthodontics, Saveetha Dental College and Hospitals, Saveetha Institute of Medical and Technical Sciences (SIMATS), Chennai-600-077.

***Corresponding Author(s): Aravind Kumar Subramanian**

Dental College and Hospitals, Saveetha Institute of Medical and Technical Sciences (SIMATS), Chennai-600-077.

Tel: +91-9841299939;

Email: aravindkumar@saveetha.com

Abstract

Aim: To assess the concomitant effects of temporary bite raising light cured orthodontic band cement versus traditional acrylic bite plane on the masticatory muscles using electromyography in orthodontic patients.

Materials and methods: Bio electromyography signals were recorded in masseter and temporalis of 10 patients requiring orthodontic bite raise before and immediately post bite raise. The sample population was divided randomly into two groups one group with light cured orthodontic bite raise and the other group with temporary acrylic bite plane. Electromyography was recorded at rest and at clench. The electromyography at rest and clench, the voltage and duration for firing were statistically compared using independent t-test among the groups. Wilcoxon signed-rank test based for normality of variables. The significance level was set at 0.05.

Results: At rest, electromyography after bite raise showed a decrease in muscle activity in the superficial masseter with a mean difference of 6.2 μ Vs, whereas no change in temporalis muscle activity which showed a mean difference of 2.9 μ Vs. At clench, the bite plane group showed reduced masseter muscle activity with a difference of 101.4 μ Vs and right temporalis showed a difference of 74.7 μ Vs. Overall, there was an increase in muscle activity in the bite plane group than the light cure bite raise group. However there was no overall change in the muscle activity during clench among the groups.

Received: May 18, 2021

Accepted: Jun 16, 2021

Published Online: Jun 19, 2021

Journal: Annals of Dentistry and Oral Health

Publisher: MedDocs Publishers LLC

Online edition: <http://meddocsonline.org/>

Copyright: © Subramanian AK (2021). *This Article is distributed under the terms of Creative Commons Attribution 4.0 International License*

Keywords: Bite raiser; Electromyography; Mmuscle activity; Orthodontics.

Cite this article: Sankaranarayanan RR, Subramanian AK. Effect of Temporary Bite Raising with Light Cured Orthodontic Band Cement and Acrylic Bite Plane on the Electromyographic Response of Masticatory muscles. Ann Dent Oral Health. 2021; 4(1): 1036.



Conclusion: The results of the current study show that there is an altered neuromuscular behavior during rest among the participants included in the study for bite raise with light cure bite and acrylic bite. These results help us understand the alteration in the muscular activity, objective and subjective symptoms which in turn can direct us for choosing the appropriate bite raise for various clinical scenarios.

Introduction

Temporary bite-raising is commonly used in orthodontic treatment for the purpose of deep bite and crossbite correction [1]. Traditionally, bite raising was achieved using acrylic bite planes extending from premolar until molar. Orthodontists have used bite planes both removable and fixed for disarticulating the occlusion and deprogramming the masticatory muscles [2]. The removable acrylic plate required patient compliance but was easy for the clinician to make necessary adjustments. Whereas, the fixed bite planes caused soft tissue irritation and regular adjustment of the bite plane was also difficult. In 1994, Joe Mayers introduced simply a lingual metal bracket instead of bite planes. Bite planes were widely replaced by these metal turbos and had advantages of oral hygiene as well. Unfortunately, these were not that efficient due to the varied lingual anatomy of incisors. Many materials such as resin turbos, acrylic gels, lingual retainer adhesives, bracket adhesives, band cement have been used as turbos [3]. But commonly used in day to day clinical practice are orthodontic light cure bite raisers. Light cure orthodontic bite raises are used to prevent interbracket hindrance, occlusal interferences, allowing unobstructed protrusive and lateral movement [3,4]. Also, in crossbite situations it allows the inwardly placed teeth to be out of interference and aid in proper alignment [5]. Unlike the acrylic bite plane these have only two point contact which may have an altered jaw muscle activity.

The objective of the study was to assess the difference in effects of muscle activity of masseter and temporalis with posterior acrylic bite plane and orthodontic light cure bite risers pre and post bite block placement at rest and at maximum voluntary clench. The null hypothesis is there is no difference in muscle activity among the two different bite raises.

Materials and methods

The study included a population within the age of 18-25 years consisting of both male and female who reported to the Department of Orthodontics, Saveetha Dental College, India. The sample size of N=10 was calculated using a post hoc test in G power software. The participants were randomly divided into two groups Group 1: Bite raise with acrylic bite plane (Figure 1) Group 2: Orthodontic light cure bite risers (Figure 2). All the participants included in the study required disocclusion and prescribed bite risers for the purpose of deep bite more than 50%, or single or multiple teeth crossbite. Participants with temporomandibular disorders, temporomandibular pain or myofascial pain, not willing to participate in the study were excluded. All the participants were compliant and did not miss any appointment during the experimental period of the study. The study was approved by the Ethical board of Saveetha Dental college and all the participants signed the consent form for the study. The purpose and method of electromyography was explained to all the participants of both the groups.

The electromyography was performed by placing two surface electrodes by palpating masseter and temporalis on either side. The participants were seated upright and relaxed on a chair. The feet of the participants were resting on the floor, hands resting on their lap facing straight and head unsupported. The area of the skin was cleaned with isopropyl alcohol (70%) and abrasive gel was applied on the electrode. Earthing surface electrodes were placed on the nape on the neck, two surface electrodes were placed on the masseter between the anteroposterior and inferosuperior dimensions of the muscle after palpating the masseter, and two on either side of the temporalis 1.5-2 mm lateral to the lateral canthus above the zygomatic arch described by Teenier, Throckmorton and Ellis (1991) [6]. All the electromyography tests were performed by the same examiner, in the same period of the day and according to the procedure. Muscle activity was measured 1) before placement of bite raise 2) immediately after placement bite raise. The light cure orthodontic bite raise was placed in the molar teeth. After etching, rinsing, isolating the light cured orthodontic cement was placed and cured with a light curing light. The occlusion was balanced on either side using articulating paper (8 micron thick) according to the technique described by Anderson, Schulte and Aeppli (1993) [7]. These two parameters physiological rest position was taken since the bite risers encroach the freeway space and secondly maximum voluntary clench as these are the most common movements performed by patients in day to day life.

Patients were made to relax and EMG recordings was made:

- Physiological rest position: The test was to monitor and quantify the electrical activity of superficial masseter and anterior temporalis muscles when at rest.
- Maximum Voluntary Clench (MVC): Participants were to clench their teeth in a centric occluding position in maximum voluntary clench and to hold for 2 seconds.

The area of integral EMG curve (duration x mean voltage, μ Vs), was computed for each muscle. The mean of integral EMG activity for each muscle. The root mean-square value of the EMG signals during the 2 seconds window was calculated and percentage of the EMG activity during MVC in centric occlusion.

Statistical analysis

The power of the study was calculated using G Power software N=10. Intergroup comparison was performed using dependent t-test and intragroup comparison was performed using independent t-test using SPSS software version 17.00 (SPSS Inc., Chicago, IL, USA). The normality of the variables was verified by the Kolmogorov-Smirnov test. The dependent t-test was performed for muscle activity at rest and maximum voluntary clench before and after bite raise. The significance level was set at 0.05. The effect size was calculated for significant comparisons $\alpha=0.05$, $\beta=0.80$.

Results

The EMG recordings for superficial masseter and anterior temporalis muscles during rest are shown in Table 1. There was a significant difference in the muscle activity in temporalis left, right masseter and left masseter. The bite plane group has more muscle activity than the blue bite group at rest with a difference of 0.1 and 0.2 respectively Table 2. Represents the muscle activity of temporalis left and right, masseter left and right during Maximum Voluntary Clench (MVC). However, there was a significant difference in the temporalis left. Overall, there was

an increased muscle activity in the participants belonging to the bite plane group. Figure 3 represents the muscle activity of temporalis at rest and Maximum Voluntary Clench (MVC). Bite plane group shows significant differences during clench in both the temporalis left and right. Figure 4 represents the muscle activity of muscle during rest and Maximum Voluntary Clench (MVC). The participants of the bite plane group had significant differences in the left masseter than the right.

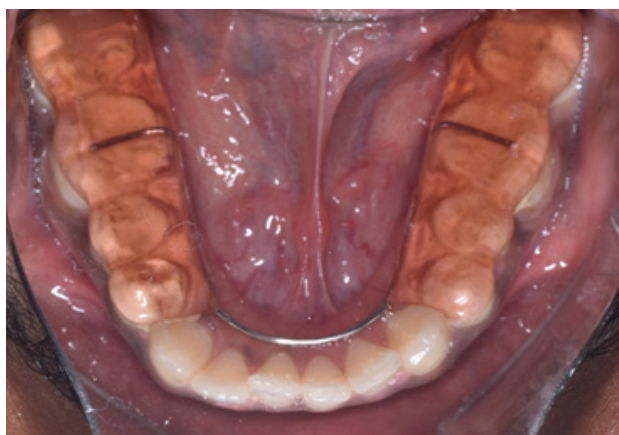

Figure 1: Represents posterior acrylic bite given for disocclusion in cross bite or deep bite correction. Occlusion was balanced using an articulating paper of 8 micron thick.

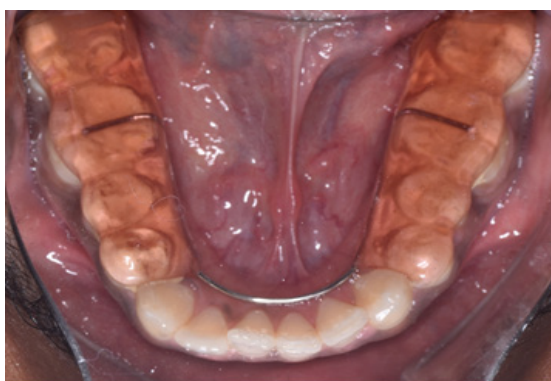

Figure 2: Represents light cure composite for disocclusion in cross bite or deep bite correction. Occlusion was balanced on either side using an articulating paper of 8 micron thick.

Table 1: Integral Electromyography (EMG) activity (μ Vs) during rest after temporary bite-raising.

Masticatory muscle	At Rest		
	Bite Raise	SD+/-Mean	Significance
Temporalis Right	Bite plane	1.21+/-0.5	0.6
	Blue bite	1.1+/-0.4	
Temporalis Left	Bite plane	1.7+/-1.0	0.4
	Blue bite	1.3+/-0.6	
Masseter Right	Bite plane	2.3+/-2.3	0.1
	Blue bite	1.7+/-0.9	
Masseter Left	Bite plane	2.1+/-0.4	0.2
	Blue bite	1.9+/-0.9	

Confidence interval: 95%

*Significant difference ($p < 0.05$, unpaired t-test).

temporalis- R and temporalis-L

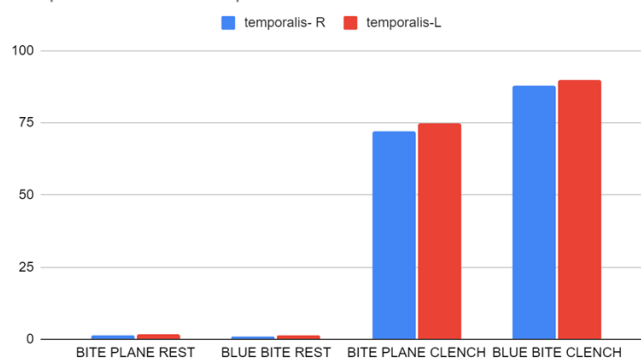


Figure 3: Graph represents electromyography activity during rest and maximum voluntary clench of temporalis right (blue) and temporalis left (red). There is a significant difference in the temporalis right ($p > 0.5$) and left ($p < 0.5$) in both the groups at rest. There is a significant difference in temporalis right ($p > 0.5$) and left ($p < 0.5$) at clench.

Masseter- R and Masseter- L

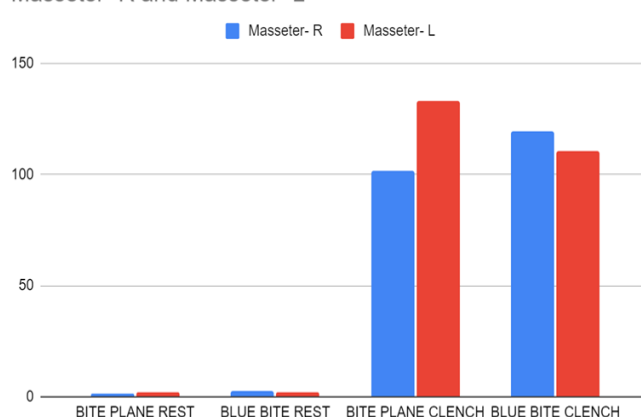


Figure 4: Graph represents electromyography activity during rest and maximum voluntary clench of masseter right (blue) and masseter left (red). There is a significant difference in both the masseter right ($p < 0.1$) and masseter left ($p < 0.2$) at rest. There is no significant difference in both the masseter right ($p > 0.7$) and masseter left ($p > 0.6$) at clench.

Table 2: Integral Electromyography (EMG) activity (μ Vs) during maximum voluntary clench after temporary bite-raising.

Masticatory muscle	At Clench		
	Bite Raise	SD+/-Mean	Significance
Temporalis right	Bite plane	72+/-3.6	0.5
	Blue bite	87+/-6.1	
Temporalis left	Bite plane	74.7+/-31.5	0.4
	Blue bite	89.7+/-60	
Masseter right	Bite plane	101.4+/-76.8	0.7
	Blue bite	119+/-66.9	
Masseter left	Bite plane	133.1+/-49.2	0.6
	Blue bite	110+/-61.6	

Confidence interval: 95%; MVC: maximum voluntary clench

*Significant difference ($p < 0.05$, unpaired t-test).

Discussion

The muscular activity of anterior temporalis and masseter was not significant during clenching. This was in accordance with the study by Koc et al [8]. Their study concludes that the muscular activity decreases when the bite raise is beyond 10mm which is in accordance with our study where the bite raise was below the range. Several studies found that increasing the occlusal vertical dimension above 3 mm by any means affects the muscular activity [8,9]. The EMG activity of the bite plane group decreased significantly. In a study by, finger et al, studies have shown that the jaw-closing muscles will reduce its activity for stabilization hence protecting the other structures [10]. The results in our study were similar to those of Dahlstrom et al, found that masseter and temporalis activity reduced using bite plates due to lower occlusal contacts however the light cure bite raise was lesser comparatively [10-12]. Whereas Wang et al, reported increased muscular activity and bite force during clench which was also similar in light cure bite raise group [13]. But we did not calibrate the bite force among both the groups. Further studies may help us understand the correlation between muscular activity and bite force with temporary bite raise. There is a study by Changsirpun et al, where they have performed subjective and objective evaluation by MPI and FIA score of the patients receiving light cure bite raise and concluded that the masticatory function has reduced in patients tremendously however they have not followed up extensively. In our study, the patients receiving light cure bite raise were finding it difficult to clench whereas the group who received a bite plane felt easier to clench because of the support throughout the posteriors. On the contrary, in the consecutive appointments the light cure raise group accommodated and no longer had difficulty clenching and were able to eat. Unfortunately, the bite plane group of patients also had no difficulty clenching but were not able to eat properly [8,14]. Ferrario et al [10,11], found that the muscle activity at maximum voluntary clench was lower in young adults with less occlusal contacts. This is in accordance with our population the muscular activity was low in the bite plane group. The activity of masseter is more than temporalis post bite raising which is in agreement with the results obtained by Koc et al [8]. Tomanari et al [15], found that lower muscular activity on the chewing side after bite raise was similar in our study that right masseter activity was lower than left. Animal studies [15,16] with bite raising for 2 weeks reduced the masseter muscle spindle sensitivity however there was no difference found after 6 weeks.

Conclusion

- Our results reveal that there is a change in muscle activity at rest after raising the bite in both the masseter with orthodontic light cure bite raise and acrylic bite raise.
- There is no significant difference in the muscular activity in both the groups at clench.
- However, patients feel more comfortable during the clench with the bite plane due to balanced occlusal contact throughout the posteriors.
- However orthodontic light cure bite raise is more advantageous in terms of clinician comfort, patient comfort, chair side time, number of appointments. Moreover, selective extrusion may be difficult with bite plates due to regular trimming may be needed.

- These composite bite raises cannot be used if more than 4 mm raise is needed, hence in such situations acrylic bite planes can be used.

This information may be useful for the orthodontists to carefully choose the type of bite raise which the patient may require in turn may reduce the chair side time, visits and increase the comfort of the patient.

References

1. González CA, Sosa GO. Bilateral posterior telescopic crossbite correction through the use of Goshgarian palatal bar and bite turbos. *Revista Mexicana de Ortodoncia*. 2016; 4: e109–e116.
2. Roy AS, Singh GK, Tandon P, et al. An interim bite raiser. *Int J Orthod Milwaukee*. 2013; 24: 63–64.
3. Kravitz N, Jorgensen G, Frey S, et al. Resin bite turbos. *J Clin Orthod*. 2018; 52: 456–461.
4. Vela-Hernández A, López-García R, García-Sanz V, et al. Nonsurgical treatment of skeletal anterior open bite in adult patients: Posterior build-ups. *Angle Orthod*. 2017; 87: 33–40.
5. Jain U, Bharti C, Chhajed R. A Simplified Method of Correcting Single-Tooth Crossbite. *J Clin Orthod*. 2016; 50: 437–438.
6. Teenier TJ, Throckmorton GS, Ellis E 3rd. Effects of local anesthesia on bite force generation and electromyographic activity. *J Oral Maxillofac Surg*. 1991; 49: 360–365.
7. Anderson GC, Schulte JK, Aeppli DM. Reliability of the evaluation of occlusal contacts in the intercuspal position. *J Prosthet Dent*. 1993; 70: 320–323.
8. Koc D, Dogan A, Bek B, et al. Effects of increasing the jaw opening on the maximum bite force and electromyographic activities of jaw muscles. *Journal of Dental Sciences*. 2012; 7: 14–19.
9. Chandu A, Suvinen TI, Reade PC, et al. The effect of an interocclusal appliance on bite force and masseter electromyography in asymptomatic subjects and patients with temporomandibular pain and dysfunction. *J Oral Rehabil*. 2004; 31: 530–537.
10. Jiménez ID. Dental stability and maximal masticatory muscle activity. *J Oral Rehabil*. 1987; 14: 591–598.
11. Ferrario VF, Serrao G, Dellavia C, et al. Relationship between the number of occlusal contacts and masticatory muscle activity in healthy young adults. *Cranio*. 2002; 20: 91–98.
12. Dahlström L, Haraldson T. Immediate electromyographic response in masseter and temporal muscles to bite plates and stabilization splints. *Scand J Dent Res*. 1989; 97: 533–538.
13. Wang X-R, Zhang Y, Xing N, et al. Stable tooth contacts in intercuspal occlusion makes for utilities of the jaw elevators during maximal voluntary clenching. *J Oral Rehabil*. 2013; 40: 319–328.
14. Changsiripun C, Pativetpinyo D. Masticatory function after bite-raising with light-cured orthodontic band cement in healthy adults. *Angle Orthod*. 2020; 90: 263–268.
15. Tomonari H, Kubota T, Yagi T, et al. Posterior scissors-bite: masticatory jaw movement and muscle activity. *J Oral Rehabil*. 2014; 41: 257–265.
16. Yabushita T, Zeredo JL, Fujita K, et al. Functional adaptability of jaw-muscle spindles after bite-raising. *J Dent Res*. 2006; 85: 849–853.