



# Dermatoglyphics in Potentially Malignant Disorders A Systematic Review of Literature

Garima Gulati<sup>1\*</sup>; Puneeta Vohra<sup>2</sup>; Archana Nagpal<sup>3</sup>

<sup>1</sup>MDS Student, Department of Oral medicine and Radiology, SGT University, Gurugram, India.

<sup>2</sup>Professor, Department of Oral Medicine and Radiology, SGT university, Gurugram, India.

<sup>3</sup>Professor and Head of Department, Department of Oral Medicine and Radiology, SGT university, Gurugram.

**\*Corresponding Author(s): Garima Gulati**

MDS Student, Department of Oral medicine and Radiology, SGT university, Gurugram, India.  
 Email: garimagulati1011@gmail.com

**Abstract**

The term, 'potentially malignant disorders', was recommended to refer to precancer as it conveys that not all disorders described under this term may transform into cancer. Critically evaluating all definitions proposed so far for oral leukoplakia, the Working Group agreed that the term leukoplakia should be used to recognize white plaques of questionable risk having excluded (other) known diseases or disorders that carry no increased risk for cancer'. An outline was proposed for diagnosing oral leukoplakia that will prevent other oral white disorders being misclassified as leukoplakia.

Received: Jul 06, 2021

Accepted: Sep 03, 2021

Published Online: Sep 06, 2021

Journal: Annals of Dentistry and Oral Health

Publisher: MedDocs Publishers LLC

Online edition: <http://meddocsonline.org/>

Copyright: © Gulati G (2021). *This Article is distributed under the terms of Creative Commons Attribution 4.0 International License*

**Keywords:** Dermatoglyphics; Oral squamous cell carcinoma; Oral leukoplakia; Oral submucosa fibrosis; Genetic alterations.

## Introduction

OPMDs have an increased risk of developing into oral cancer. Several varieties are recognized. Some of them are solitary lesions, whereas others, referred to as conditions, are multifocal or widespread within the oral cavity. Leukoplakia is the most common OPMD encountered in clinical practice.

Classification of precancerous lesions and conditions (WHO)

**Table 1:** Depicting precancerous lesions and precancerous conditions by (WHO).

Precancerous lesions	Precancerous Conditions
Leukoplakia	Submucous fibrosis
Erythroplakia	Actinic Keratosis
Palatal lesions in reverse smokers	Lichen planus Discoid lupus erythematosus



**Cite this article:** Gulati G, Vohra P, Nagpal A. Dermatoglyphics in Potentially malignant disorders: a systematic review of literature. *Ann Dent Oral Health*. 2021; 4(1): 1041.

**Oral leukoplakia**

**Definition**

**WHO collaborating centre for oral precancerous lesions in 1978** defined oral leukoplakia as “A white patch or plaque that cannot be characterized clinically or pathologically as any other disease.”[1]

**Axell T et al in 1996** also defined oral leukoplakia as “A predominantly white lesion of oral mucosa that cannot be characterized as any other definable lesion; some leukoplakia will transform in to cancer [2].

**Pindborg et al in 1997** defined leukoplakia as “A predominantly white lesion of the oral mucosa that cannot be characterized as any other definable lesion” [3].

**WHO in 2005** declared “Leukoplakia should be used to recognize white patch of questionable risk having excluded other known diseases or disorders that carry no increased risk for cancer [4].

**Van der Waal I et al** reviewed potentially malignant disorders of the oral and oropharyngeal mucosa; terminology, classification and present concepts of management and gave WHO workshop recommendations such as to abandon the distinction between potentially malignant lesions and potentially malignant conditions and to use the term potentially malignant disorders instead [5].

**Epidemiology**

Prevalence of leukoplakia was reported to be 3.6% and that of preleukoplakia was 6.4%. Idiopathic leukoplakia was reported to be 0.7% and tobacco specific leukoplakia was 2.9%.

**Age and Gender** The onset of lesions usually starts after 30 years, resulting in peak incidence of 50 years. Leukoplakia is seen most frequently in middle aged and older men, with an increasing prevalence with age.

Oral leukoplakia can occur 5 years prior to oral cancer. It has a strong male preponderance. Leukoplakia is a commonly occurring lesion particularly in patients after 40 years of age. The male to female ratio is 2:1. The gender distribution in most studies varies, ranging from a strong male predominance in different parts of India, to almost 1:1 in Western world [6].

**Bánóczy J** made a follow-up study with 670 patients with oral leukoplakia during a 30-year-period showed cancer development in 40 cases. The age distribution revealed the prevalence of leukoplakia in the age-group 51-60 years; that of carcinoma in the age-group of 61-70 years. The sex distribution showed a male-female ratio of 3.2: 1 in the leukoplakia group, and a 1.9: 1 ratio in the carcinoma-group [7].

**Etiology/Causative Factors in Leukoplakia**

**Table 2:** Etiologic factors in leukoplakia.

Local	Systemic
Local irritation Sharp, malposed teeth Ill fitting denture Poor restorations	Heredity
Occlusal disharmony	Hormonal factors
Occlusal habit	Estrogen deficiency
Thermal factors	Nutritional deficiency
Smoking	Syphilis
Irritant foods, chemicals, mouthwashes, etc.	Atrophic glossitis

**Clinical types**

Two main type exists:

1. Homogeneous
2. Non homogeneous

Distinction between these two forms is purely clinical, based on surface color and morphological characteristics like thickness, which also has predilection for prognosis.

**Homogeneous type**

Homogeneous leukoplakia has been defined as a predominantly white lesion of uniform flat, thin appearance that may exhibit shallow cracks and has a smooth, wrinkled or corrugated surface with a constant texture throughout. The risk of malignant transformation is relatively low.

The lesion is predominantly white but can be grayish white. It constitutes for about 84% of the leukoplakia.

**Non homogeneous type**

Ulcerative: Mixed white and red in color but retaining there predominant white character.

Nodular (Speckled): Small polypoid outgrowths, rounded red or white excrescences.

Verrucous: wrinkled or corrugated surface appearance. The term “Erythro leukoplakia” is applied for predominantly red and white lesion that may be irregularly flat, nodular or exophytic. The nodular lesions are characterized by white patches or nodules on a erythematous base.

**Clinical features**

Most commonly involved sites are retro commissural area, buccal mucosa, edentulous alveolar ridge, hard palate, tongue, lips. The gingival, soft palate and floor of mouth are less commonly involved in an Indian population, where as it is not true for Western population. Leukoplakia begins as thin, gray white plaques that may appear somewhat translucent, sometimes fissured or wrinkled and are soft and flat [8].

**Leukoplakia clinical phases**

**Table 3:** Types of leukoplakia and risk of malignant transformation.

Phase	Descriptive terms	Risk of malignant transformation
I	Thin leukoplakia Preleukoplakia Homogeneous leukoplakia	+/-
II	Thick, smooth leukoplakia Fissured leukoplakia Homogeneous leukoplakia	++
III	Granular leukoplakia Verruciform leukoplakia Rough leukoplakia Candidal epithelial hyperplasia Homogeneous leukoplakia	+++
IV	Erythroleukoplakia Speckled leukoplakia Candidal leukoplakia Nonhomogeneous leukoplakia	++++

### Genetic alteration in Oral Leukoplakia

Dermatoglyphics are the dermal ridge configurations on the digits, palms and soles. They are genetically determined and influenced by environmental forces that operate before birth. Not all the people using tobacco suffer from precancerous and cancerous lesions of oral cavity. Genetic predisposition might explain such an individual variability that can be predicted by using various cytogenetic markers. However, these studies are far more costly and complicated. Several studies have shown an association between dermatoglyphics and different types of cancer.

#### Dermatoglyphic studies in oral leukoplakia

**Hakan polat et al** conducted a study in Istanbul university on 2004 in patients with oral cancer to evaluate the dermatoglyphic pattern. 29 patients with oral cancer and 80 healthy individuals as controls were included in the study. Qualitative analysis was done by studying the finger tip pattern like arches, loops and whorls also the palmar pattern studied in hypothenar area, thenar areas I1, I2, I3, I4. Quantitative analysis was done by estimating the a-b ridge count, finger ridge count, and total finger ridge count and at the angle [9].

When whorls were compared controls had increased frequency of whorls (27.3%) when compared to oral leukoplakia patients (58.6%). The p value was  $\leq 0.001$ , which is highly significant. This is in accordance with studies conducted by Hakan Polat et al and Venkatesh et al.

In the study conducted by Hakan Polat et al, the finger print pattern distribution showed 7.2% arches, 57.2% ulnar loops, 2.4% radial loops and 33.1% whorls pattern in oral cancer patients and 3.9% arches, 56.0% ulnar loops, 4.9% radial loops and 35.3% whorls pattern in control group. The frequency of various finger print pattern is compared among the two groups and the result showed increased frequency of arches oral cancer patients. The P value was  $\leq 0.05$  [10].

In the study conducted by Venkatesh et al the finger print pattern distribution showed 6.3% arches, 63% loops and 30% whorls pattern in oral leukoplakia patients, 7% arches, 60.7% loops and 32.3% whorls pattern in OSCC patients and 2% arches, 30% loops and 68% whorls pattern in control group [11].

#### Oral submucous fibrosis (OSMF)

Oral submucous fibrosis (OSMF) precancerous condition and is chronic, resistant disease characterized by juxta-epithelial inflammatory reaction and progressive fibrosis of the submucosal tissues. In 1966, Pindborg defined OSMF as "an insidious chronic disease affecting any part of the oral cavity and sometimes pharynx. It is associated with juxta-epithelial inflammatory reaction followed by fibroelastic changes in the lamina propria layer, along with epithelial atrophy which leads to rigidity of the oral mucosa proceeding to trismus and difficulty in mouth opening." Other terms used to describe this condition are juxta-epithelial fibrosis, idiopathic scleroderma of the mouth, idiopathic palatal fibrosis, submucous fibrosis of the palate and pillars, sclerosing stomatitis, and diffuse OSMF [12].

It occurs at any age but most commonly seen in young and adults between 25 and 35 years (2<sup>nd</sup>–4<sup>th</sup> decade). Onset of this disease is insidious and is often 2–5 years of duration. It is commonly prevalent in Southeast Asia and Indian subcontinent. The prevalence rate of OSMF in India is about 0.2%–0.5%. This increased prevalence is due to increased use and popularity of

commercially prepared areca nut and tobacco product - gutkha, pan masala, flavored supari, etc. The malignant transformation rate of OSMF was found to be 7.6% [11,12].

#### Etiopathogenesis

OSMF was first described by Schwartz in 1952, where it was classified as an idiopathic disorder by the term atrophica idiopathica (tropica) mucosae oris. Since then, many hypotheses are being suggested that OSMF is multifactorial in origin with etiological factors are areca nut, capsaicin in chillies, micronutrient deficiencies of iron, zinc, and essential vitamins. Autoimmune etiological basis of disease with demonstration of various autoantibodies with a strong association with specific Human Leukocyte Antigen (HLA) antigens has also been suggested.

Areca nut (betel nut) chewing is one of the most common causes of OSMF which contains tannins (11%–12%) and alkaloids such as arecoline, arecaidine, guvacine, and guvacoline (0.15%–0.67%). Out of all arecoline is the main agent. Arecaidine is an active metabolite in fibroblast stimulation and proliferation, thereby inducing collagen synthesis. With the addition of slaked lime (Ca [OH] 2) to areca nut, it causes hydrolysis of arecoline to arecaidine making this agent available in the oral environment. Tannin present in areca nut reduces collagen degradation by inhibiting collagenases. OSMF is induced as a combined effect of tannin and arecoline by the mechanism of reducing degradation and increased production of collagen, respectively [13].

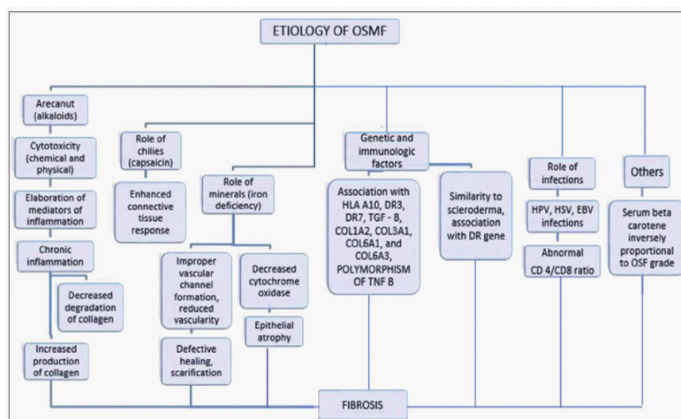
#### Nutritional deficiencies

Deficiency of iron (anemia), Vitamin B complex, minerals, and malnutrition are promoting factors that disturbs the repair process of the inflamed oral mucosa, thus leads to deranged healing and resultant scarring and fibrosis. The resulting atrophic oral mucosa is more susceptible to the effects of chillies, betel nuts, and other irritants.

#### Genetics and immunology

A genetic component is believed to be involvement in OSMF because there are cases reported in medical literature in people without any history of betel nut chewing or chili ingestion. Patients with OSMF have increased frequency of HLA-A10, HLA-B7, and HLA-DR3.

An immunologic phenomenon is thought to play a role in the etiopathogenesis of OSMF. The increase in CD4 cells and cells with HLA-DR in these diseased tissues shows activation of most lymphocytes and increased number of Langerhans cells. These immunocompetent cells and high of CD4:CD8 ratio in OSMF tissues show the activation of cellular immune response, which results in deranged immune regulation and an altered local tissue morphology. These changes may be due to direct stimulation from exogenous antigens such as areca alkaloids or due to changes in tissue antigenicity leading an autoimmune response. The major histocompatibility complex Class I chain-related gene A (MICA), which is expressed by keratinocytes and epithelial cells, interacts with gamma/delta T cells localized in the submucosa. MICA has got a triplet repeat (guanine, thymine, cytosine) polymorphism in the transmembrane domain, which results in five different allelic patterns. The phenotype frequency of allele A6 of MICA is higher in OSMF. Increased levels of pro-inflammatory cytokines and reduced anti-fibrotic interferon gamma (IFN-gamma) also contribute to the pathogenesis of OSMF [14].



**Table 4:** Etiopathogenesis of oral submucous fibrosis.

### Dermatoglyphics as a genetic marker for oral submucous fibrosis

Genetics play an important role in the determination of palmer dermatoglyphics. Oral Submucous Fibrosis (OSMF) in India is high due to excess consumption of areca nut. Hereditary and environmental factors causing OSMF may lead to peculiarities in the dermatoglyphic patterns. One of the key factors in the prevention of disease is to identify risk factors early in life so that tailor-made preventive measures can be implemented depending on the degree of risk for each individual. The medical community has been tirelessly working towards the identification of new risk factors and researching cost effective methods to diagnose them. Based on the fact that a certain genetic markers may prove to be risk factors and their determination may help predict and thereby preventing disease in the future [14].

Since ancient times, the study of fingerprints has fascinated scholars, doctors, and laymen alike. Human fingerprints are detailed, unique, difficult to alter, and durable over the life of an individual, making them suitable as long-term markers of human identity. Fingerprints have a major role to play during any disaster, which helps in identifying people who are incapacitated or deceased. Cummins in 1926 first introduced the term “dermatoglyphics” which refers to the study of the naturally occurring patterns of the surface of the hands and feet of human beings.

Oral Submucous Fibrosis (OSMF) is a potentially malignant disorder with a high rate of malignant transformation. It also shares a unique predisposition of occurrence in the Indian subcontinent due to the excess consumption of betel nut (*Areca catechu*). The total number of cases of OSMF in India is around two million, however not all the people using betel nut (*A. catechu*) suffer from this disease. Thus, there may be a certain genetic predisposition for this disease which can be predicted by using various cytogenetic markers [14].

### Dermatoglyphic studies in OSMF

Very few studies have been conducted to ascertain role of dermatoglyphics and OSMF independently. Gupta and Karjodkar conducted a similar study to assess the role of dermatoglyphics in squamous cell carcinoma and OSMF. In the present study, the percentage of arches in study group was 0.5% as compared to 7.5% in controls with the habit. This finding was similar to that reported by Gupta and Karjodkar in terms of arch pattern – higher percentage was seen in controls (26.7%) as compared to OSMF patients (23.4%). However, the finding related to whorls pattern seen in the present study did not corroborate with that reported by Gupta *et al.* and Tamgire *et al.* as they re-

ported higher percentage of whorl pattern in the control group as compared to the study group. The reverse of this was seen in the present study. This could be attributed to racial differences as anthropologically the races within India have evolved differently and above-mentioned studies were conducted in different region [15].

The field of dermatoglyphics holds promising results for determining the genetic susceptibility of individuals to develop OSMF. Although the present study reveals significant results, the scope for further research remains open as there is a paucity of similar literature for comparisons.

### Oral lichen planus

Oral lichen planus (OLP) is a chronic, autoimmune mucocutaneous disease, occurring most commonly in the middle-aged women. Lichen planus may also occur concurrently or independently in the skin and the genital, anal, esophageal, nasal and laryngeal mucosae. The prevalence of oral lichen planus in general population varies from 1-2%. There is no racial predilection, and the disease appears to be pan racial. Andreasen reported that the average age of occurrence in males and females is 40-49 years and 50-59 years, respectively. However, few cases have been reported in children as young as 6 months.

Clinically the oral lesions have been grouped into reticular, popular, plaque like, atrophic, erosive and bullous forms. OLP usually occurs in a bilaterally symmetrical pattern, commonly involving buccal mucosa, gingivae and dorsum of the tongue. The lesions are usually painless, though pain and burning sensation are associated with erosive and atrophic lesions [16].

Lichen planus lesions usually present as a bilateral keratotic lace-like network of white striae on the buccal mucosa and the lateral margins of the tongue. The reticular type is the most frequent type encountered in clinical practice, and most patients are asymptomatic. The reticular lesions appear as interlaced, raised lines forming a latticework. Sometimes, the striae may have a linear or annular presentation. Reticular OLP can also be found on the mucobuccal fold, gingiva, floor of mouth, labial mucosa, lips, and, rarely, palate. The popular type presents as small, white, raised papules that the clinician must differentiate from Fordyce granules. The plaque type commonly found on the dorsum of the tongue closely resembles leukoplakia; however, keratotic white striae are found at the lesion periphery. Atrophic erosive and ulcerative types may present as erythematous areas or with frank ulceration. Often, keratotic white striae are seen at the margins. When the lesion is ulcerated, patients typically complain of soreness or a burning sensation while eating hot or spicy food.

Atrophic OLP presenting on the gingiva, can be seen as desquamative gingivitis. The bullous type is rare, tends to recur, and is important to be differentiated from pemphigus or mucous membrane pemphigoid.<sup>77</sup> Some patients may exhibit cutaneous lichen planus, and medical history may help identify OLP cases. Other extra oral mucosal sites, such as the genitalia, may also be affected. Genital examination may help to identify persons with the vulvovaginal gingival variant of lichen planus.

Lichen planus is usually diagnosed clinically. Its bilateral distribution and the presence of the classic reticular forms with keratotic white striae are helpful for chairside diagnosis. The differential diagnosis for OLP, when it presents with a reticular/erythematous appearance, includes lichenoid lesions, lichen sclerosus, discoid lupus erythematosus (DLE), when ul-

cerative, chronic ulcerative stomatitis, and, when plaque-like, oral leukoplakia. Biopsy and histopathologic examination are recommended to make a definitive diagnosis. The essential histologic findings are comparable, regardless of the areas involved or the subtype of clinical presentation. Microscopy also aids in identifying the presence of epithelial dysplasia and, on rare occasions, malignancy. Direct immunofluorescence studies do not aid in the diagnosis of lichen planus but could help rule out DLE or mucous membrane pemphigoid [16,17]. OLP may last for several years, with periods of symptom flare-ups and remission. In patients with the ulcerative type of OLP, sclerotic fibrous bands may appear. A systematic review has confirmed malignant transformation of OLP lesions, but there are no specific criteria to assess this risk. The designation and description of the pathology were first presented by the English physician Erasmus Wilson in 1866. He considered this to be the same disease as "lichen ruber," previously described by Hebra and characterized the disease as "an eruption of pimples remarkable for their color, their figure, their structure, their habits of isolated and aggregated development". In 1892, Kaposi reported the first clinical variant of the disease, lichen ruber pemphigoides. In 1895, Wickham noted the characteristic reticulate white lines on the surface of LP papules, today recognized as Wickham striae. Darier is credited with the first formal description of the histopathological changes associated with LP [18].

### Etiology

The etiology of OLP appears to be multifactorial and complicated. Earlier studies have implicated stress, anxiety, depression as the causes for OLP. However, whether stress is the cause or the consequence was left undetermined. Familial cases of OLP have been reported and role of genetic predisposition was considered. Watanabe T *et al.* concluded that Human Leukocyte Antigen (HLA) associated genetic factors play a certain role in the pathogenesis of OLP. Hedberg and associates reported that epithelium involved by OLP was consistently positive for HLA-DR.

Lodi G *et al.* reported that lichen planus is sometimes associated with infections or autoimmune diseases and / or neoplasia, but the association had not been established. Certain systemic diseases like diabetes mellitus, hypertension, ulcerative colitis, myasthenia gravis, lupus erythematosus etc. were considered to be associated with OLP. A more consistent association was found between chronic liver disease and erosive form of OLP. Recent studies indicate an association between Hepatitis C Virus (HCV) and OLP. HCV is a hepatotropic Ribonucleic acid (RNA) virus, which possibly alters the antigenicity of the epidermis, causing an interaction with activated T- cells, or acts through a modulation of the quality of host immune response [19].

Oral lichenoid reactions caused by drugs and dental restorative materials have been considered as variants of OLP. Drugs implicated are non – steroidal anti inflammatory agents, sulfonyl urea's, beta blockers, oral hypoglycemic agents, disperse, pencil amine. Dental restorative materials like amalgam, composite, acrylic, gold have been reported to cause lichenoid reactions. Lichenoid lesions have also been reported in tobacco chewers; however, the causative role of tobacco in the pathogenesis of OLP has not been identified [18,19].

### Pathogenesis

Current literature suggests that OLP is caused by cluster of differentiation 8 (CD-8) cell mediated damage to the basal

keratinocytes leading to apoptosis. The antigen inciting the cytotoxic T cells could be any of the above mentioned factors including stress, chronic liver disease, HCV virus, dental restorative materials and/or drugs. The main event in the pathogenesis appears to be increased production of cytokines leading to the recruitment of Langerhans cells and clonal expansion of cytotoxic cells. Langerhans cells produce increased amounts of interferon -alpha (IFN -  $\alpha$ ), which further activates cytotoxic cell mediated apoptosis, via the keratinocyte caspase cascade. Intercellular adhesion molecules enhance the attraction of cytotoxic T cells. Interferon - $\gamma$  production increases the apoptosis through the up regulation of p53 and matrix metallo proteinase -1 (MMP-1). Non specific mechanisms like mast cell degranulation and MMP -1 activation further aggravate the T cell accumulation, basement membrane disruption by mast cell proteases and keratinocyte apoptosis (triggered by basement membrane disruption). The chronicity of the OLP lesions might be partly explained by the fact that the basement membrane disruption triggers keratinocyte apoptosis and apoptotic keratinocytes are unable to repair the breach in basement membrane [19].

### Oral squamous cell carcinoma

Oral cancer encompasses all cancers developing in the oral cavity and pharynx. Approximately 90% of all oral malignancies are squamous cell carcinomas that originate in the epithelial mucosa lining the oral cavity and its tissues. Oral squamous cell carcinoma (OSCC) is frequently the cancer type referred to with the general term "oral cancer" [20].

**Epidemiology and Etiology** Oral cancer occurs predominantly in adult males than females, aged 50 years and older with a history of tobacco and alcohol use, the primary risk factors for oral cancer. These risk factors account for the high incidence rates found in populations where cultural and social use of tobacco and/or alcohol are common, such as Western Europe, Southeast Asia, and Melanesia.

In many regions, men exhibit greater prevalence than women, with incidence rates of 7.9 per 100,000 males versus 3.3 per 100,000 females, due to higher proportion of smoking and drinking habits in men.

Interestingly, these factors appear to act individually or synergistically, with up to 100 times higher risk in heavy smokers and heavy drinkers. Tobacco in all forms, including cigarettes, cigars, pipe tobacco, or smokeless tobacco such as chewing tobacco, snuff, and betel quid, increases the risk of oral cancer. Betel quid, common in India, Southeast Asia and the South Pacific islands, consists of a betel leaf that is wrapped around a mixture of areca nut and slaked lime with tobacco and sweeteners [20].

In the past decade, there has been an alarming increase in the popularity of cheap, ready-packaged chewing tobacco that is often chocolate or mint candy flavored, among children in India over traditional betel quid. This trend has led to an increase in malignant lesions and potentially malignant disorders of the buccal mucosa in younger Indian populations,

In addition, recent studies have linked high-risk HPVs (human papilloma virus-16 and 18) to oral cancer development in up to 25 % of all OSCC cases. HPV, one of the most common sexually transmitted diseases worldwide, may partially account for the increase in oral cancer among young adults 20-45, particularly those located on the tongue and tonsil.

HPV-associated OSCC may display distinct molecular, clini-

cal, and pathological characteristics along with significantly improved prognosis (59% reduction in risk of death) versus non-HPV OSCC. Additional factors which may play a role in oral carcinogenesis include genetic susceptibility, diet, Epstein-Barr Virus infection and immunosuppression [21].

### Clinical features

OSCC is found most frequently in the lateral tongue, representing approximately 40% of all cases, and the floor of the mouth. The high-risk of malignancy at these sites is attributed to the pooling of saliva containing carcinogens in these areas, as well as the lack of protection afforded by the thin, non-keratinized epithelium present. A large number of squamous cell carcinomas also develop in the lower lip vermilion border due to excessive sun exposure, but typically possess low risk of metastasis. Asian population usually suffer from cancer of the buccal mucosa due to betel quid/tobacco chewing habits; buccal mucosa SCC constitute 40% of OSCC in Indian population. The most common symptom is a non-healing sore or ulcer.

Other potential signs and symptoms include pain, numbness, a persistent lump or thickened area, a persistent red or white patch, dysphagia, sore throat or the sensation of something "caught" in the throat. The clinical appearance of OSCC is variable. It can be exophytic (growing outward) or endophytic (growing inward), and may have an ulcerated surface. OSCCs are characteristically firm on palpation, which can be a helpful diagnostic clue.

The color of OSCC can be white, red or, in many cases, speckled red and white. Advanced metastatic spread of OSCC regularly encompasses multiple oral sites and/or cervical lymph nodes with greater than 50% of all OSCC cases showing regional lymph node involvement at initial diagnosis.

### Genetic alterations in OSCC

In a study by Rosin et al. [65] risk of cancer development from potentially malignant disorders was low in the absence of genetic alterations, increased moderately in the presence of genetic mutations on chromosomes 3p and 9p, and high when 3p and 9p mutations were accompanied by additional loss in one or more chromosomal regions (including 4q, 8p, 11q, 13q and 17p). The continued accumulation in genetic mutations. As a result of exposure to carcinogens, such as tobacco and alcohol, ultimately leads to wide-spread genomic instability associated with advanced cancer progression and metastasis [22].

Current Detection of Oral Cancer and Pre-malignant Lesions Currently, detection of oral cancer and potentially malignant disorders relies upon visual inspection of the oral cavity for mucosal abnormalities in a process known as Conventional Oral Examination (COE). Dental professionals and primary care physicians who see patients regularly are more likely to identify early-stage lesions through yearly cancer related check-ups, as recommended by the American Cancer Society. In a recent systematic review of seven studies evaluating COE as a method for detecting early cancerous lesions, sensitivity ranging from 60% - 97% and specificity ranging from 75% - 99% were reported, which are comparable to rates found in other cancer screening programs.

This suggests that COE may be an adequate screening method to identify oral lesions. Shortcomings of this method include the inability to detect subclinical abnormalities or discriminate between benign lesions and those with a high-risk

of malignancy, which may require the use of adjunctive diagnostic techniques. Further, the effectiveness of COE screening to reduce disease-related mortality remains to be determined. Lymph node status appears to be the most significant prognostic factor for OSCC with survival approximately cut in half when metastases are found in local or regional lymph nodes. In these patients, the number of positive nodes and the presence of extracapsular spread contribute to a negative prognosis.

Other classic clinic pathological features including anatomical site, tumor size, grade, and maximal thickness have been shown to possess limited predictive value for the identification of patients with a high risk of disease relapse and death [23].

### Dermatoglyphic studies in oral cancer

In oral cancer the mean  $\pm$  S.D. was  $117 \pm 46.45$  in males and  $126.95 \pm 34.68$  in females. In control group the mean  $\pm$  S.D. was  $131.47 \pm 34.15$  in males and  $108.53 \pm 42.79$  in females. The results were statistically insignificant. There is no significant difference observed in ab count. In oral cancer the mean  $\pm$  S.D. was  $69.51 \pm 14.03$  in males and  $66.91 \pm 9.64$  in females. In control group the mean  $\pm$  S.D. was  $76.07 \pm 11.89$  in males and  $74.07 \pm 7.28$  in females. The results were statistically insignificant. There is significant difference observed in atd angle. In oral cancer the mean  $\pm$  S.D. was  $87.5 \pm 25.42$  in males and  $85.18 \pm 10.02$  in females. In control group the mean  $\pm$  S.D. was  $97.79 \pm 22.82$  in males and  $104.5 \pm 20.87$  in females. The p value was  $< 0.01$  in females which is statistically highly significant [24].

Venkatesh et al conducted a study in KLE institute, Belgaum on 2009 in patients with oral leukoplakia and oral squamous cell carcinoma. 30 patients with oral leukoplakia, 30 patients with OSCC and 30 controls with habits but no oral lesions were included in the study. Qualitative analysis was done by studying the fingertip pattern like arches, loops and whorls also the palmar pattern studied in hypothenar area, thenar areas I1, I2, I3, I4. Quantitative analysis was done by estimating the a-b ridge count, finger ridge count, total finger ridge count and atd angle. The study results of finger print pattern distribution showed 6.3% arches, 63% loops and 30% whorls pattern in oral leukoplakia patients, 7% arches, 60.7% loops and 32.3% whorls pattern in OSCC patients and 2% arches, 30% loops and 68% whorls pattern in control group [25].

The frequency of various finger print pattern is compared among the three groups and the result showed increased frequency of arches and loops in oral leukoplakia and OSCC patients whereas in control group there is an increased frequency of whorls. The  $\chi^2$  was 109.493 and the P value was 0.000. The distribution of pattern in hypothenar area among the three groups was statistically insignificant. In oral leukoplakia, 80% in right hand and 90% in left hand had pattern. In OSCC, 76.67% in right hand and 73.3% in left hand had pattern. In control group, 80% in right hand and 83.3% in left hand had pattern. The  $\chi^2$  value was 1.986 and the P value was 0.370. The distribution of pattern in thenar area I1 among the three groups was statistically insignificant. In oral leukoplakia, 86.67% in right hand and 76.67% in left hand had pattern. In OSCC, 90% in right hand and 80% in left hand had pattern. In control group, 83.3% in right hand and 73.3% in left hand had pattern. The  $\chi^2$  value was 0.891 and the P value was 0.64. The distribution of pattern in I2, I3 and I4 area showed increased frequency of loops in control group as compared to oral leukoplakia and OSCC patients. In oral leukoplakia, 33.33 in right hand and 21.11% in left hand had pattern. In OSCC, 18.88% in right hand and 21.11% in left

hand had pattern. In control group, 34.44% in right hand and 35.5% in left hand had pattern. The  $X^2$  value was 13.109 and the P value was 0.011.

There is no significant difference observed in TFRC. In oral leukoplakia, the mean value was 148.1 and the standard deviation was 42.58. In OSCC, the mean value was 168.13% and the standard deviation was 43.56. In control group, the mean value was 168.43 and the standard deviation was 40.67. Frequency was 1.866 and the P value was 0.061. There was no significant difference observed in ab count. In oral leukoplakia, the mean value was 38.77 in right hand and 38.87 in left hand. In OSCC, the mean value is 38.57 in right hand and 40.17 in left hand.

In control group, the mean value in right hand was 40.67 and 41.47 in left hand. The P value was 0.339 for right hand and 0.309 for left hand. There was no significant difference observed in atd angle. In oral leukoplakia, the mean value was 40.33 in right hand and 39.93 in left hand. In OSCC, the mean value is 39.93 in right hand and 38.50 in left hand. In control group, the mean value in right hand was 40.93 and 39.96 in left hand. The P value was 0.609 for right hand and 0.206 for left hand [26].

#### **Comparison of dermatoglyphic patterns in oral leukoplakia, OSCC and oral submucous fibrosis patients**

It is the study of the patterns of print found on plantar and palm surfaces of hand and toes. Fingerprints are unique to each other. They form by the 24<sup>th</sup> week of intrauterine life. Several genes interlink with environmental factors to form these unique patterns of an individual. In the case of chromosomal or genetic alterations, fingerprints show abnormal ridge patterns. Recently, many investigators have focused their attention on finding an association of morphological and genetic characters with several

pathological conditions. Developmental instability is reflected and reliably measured by fluctuating asymmetry. Fluctuating asymmetry is an indicator of genetic and environmental stress. This asymmetry is seen by assessing various ridge patterns on plantar surfaces of the hands. Thus, dermatoglyphics is a simple, noninvasive, and inexpensive method of connecting genetics to pathologies.

Ramani et al. observed the genetic component for various fingertip patterns. Once formed, they are age and environment stable, becoming a reliable indicator, of genetic damage. With this information in mind, the present study was done to compare and evaluate the fingerprint patterns in subjects having oral leukoplakia and OSMF [27]. In India, there is a high prevalence of tobacco users. This issue has led to increased cases of oral leukoplakia and oral submucous fibrosis. Although these lesions are reversible, if undiagnosed there is a chance that these lesions might convert into malignancies. A range of genetic, molecular and chromosomal alternations, that they share, characterizes oral potentially malignant lesions and malignant lesions as well which develop from them. One simple way to study these lesions is through the means of

dermatoglyphics.

Awasthy D et al. conducted a study comparing dermatoglyphics with OSMF and oral leukoplakia and healthy subjects without any habit or lesion and subjects with habits but no lesion. They reported that the loop pattern is commonly found in all the groups but there was a mild rise in the frequency of occurrence of loops in pathologic conditions, i.e., OSMF and leukoplakia. In this study, loop patterns were also the most commonly found patterns. However, their frequency changes from healthy subjects to oral leukoplakia and OSMF. More loop patterns are found in healthy subjects, than oral leukoplakia and OSMF [28].

Munishwar and co-workers reported that the loop pattern was more in a healthy group than in patients of OSMF and gutka chewers. They found that there was an increase in the loop pattern in OSMF patients (43.60%) and the control group (57.60%). The present study shows that there is an increase in loop patterns in healthy subjects (61.0%), but decreases in subjects having OSMF(57.0%) [29].

Jatti D et al. conducted a study comparing dermatoglyphics with potentially malignant diseases and Oral squamous cell carcinoma. They found that in an arch pattern is commonly found in potentially malignant diseases. The present study shows decreased in the frequency of arch pattern in leukoplakia but increased in frequency in OSMF subjects as compared to healthy subjects [30].

A study conducted by Tamgire Dw et al. the comparison was done between subjects having habits but no lesions and subjects having OSMF. They found that a decline in patterns of whorls OSMF was seen than in gutka chewers. The present study shows that in comparison with healthy subjects, there is an increased frequency of whorled patterns in oral leukoplakia and OSMF subjects. However, there is a decrease in the frequency of whorled patterns in OSMF as compared to oral leukoplakia [31].

Gupta and Karjodkar studied the correlation of dermatoglyphics with OSMF and Oral Squamous cell carcinoma subjects. They reported an increased percentage of loops and arch patterns in the OSMF group but a decrease in the frequency of whorled patterns. The present study shows that there is a decrease in the percentage of loop patterns in OSMF patients than in healthy patients while an increase in the frequency of whorled patterns. The results of the present study are similar to the ones obtained by Satish Kumar et al. They examined the correlation subjects without any habit or lesion and subjects having OSMF. They reported increased whorl patterns among OSMF subjects when compared to healthy subjects. Another study conducted by Venkatesh et al. On dermatoglyphics in patients with oral leukoplakia and OSCC showed an increase in the frequency of arch pattern in oral leukoplakia subjects as compared to healthy subjects, while there was a decrease in the occurrence of a whorled pattern as compared to healthy subjects [32].

**Table 5:** Depicting Dermatoglyphic characteristics and Review of Literature.

S.NO	Name Of Author	Disease/Opmd's	Year	Dermatoglyphic Characteristics
1	Baljir et al	Cleft Lip/Palate	1986	Increase in the Ulnar loop & Arch patterns
2	Elluru Venkatesh	OSCC,OL	2006	Loops were at higher in the Interdigital area in OL Whorls seen more frequently in OSCC
3	Ambilka Gupta	OSCC,OSF	2013	OSCC Shows increase in frequency of arch & Ulnar loops on finger tips, decrease in frequency of whorls patterns on fingertips OSF Shows increase in frequency of arch & Ulnar loops pattern , decrease in frequency of whorls pattern on fingertips ,Also decrease in ATD angle on right hand
4	C.Anitha et al	Early Childhood Caries	2014	Shows increased frequency of Ulnar loops in carrier free children & increased Whorls in children having early childhood caries
5	Jatti.D et al	OSMF,OL,OSCC	2014	It was observed that arch pattern was predominate with decrease in whorls pattern Increase in mean total finger ridge count
6	Kumar.S et al	OSMF	2014	Decrease of tented arches , ulnar & radial loops Increase in simple whorls in OSMF
7	Ganvir SM et al	OSCC,OSMF	2014	Increase in whorls type of fingerprint Patterns in OSCC & OSMF
8	David MP et al	OSCC	2015	Increased No of loops & mean no of total ridge count were found Increased arches were seen predominantly
9	N. Laxman et al	OSMF,OL	2016	Loops were found to be predominant finger ridges patterns
10	Shanker et al	Cancerous Patient , Precancerous Patient	2016	Cancerous patient increase in Ulnar loops on finger tips Pre-Cancerous patient ; High in left little finger & Right finger
11	Shruthi Chandrashekar et al	Orofacial Diseases	2017	Higher frequency of creases , Bilateral , Radial Loops on digits 4&5 Ulnar loops seen in patient with Down's Syndrome
12	Devashree Awasthy	OSMF, OL	2018	Increase in loop pattern in patient of OSMF
13	Shetty SS et al	Dental Caries	2018	Loop pattern were associated with high DMFT Score Individuals with arch pattern were found to be caries free
14	Gitanjali Darna et al	OSMF , OL , OLP	2018	Whorls pattern is more predominant with increase in arch pattern in OL & OLP

## References

- Doss DM, Nirmal M, Veeravarmal RS, Venkatesh A. Evaluating the expression of GLUT-1 in oral leukoplakia. *Journal of Oral and Maxillofacial Pathology: JOMFP*. 2020 May; 24: 308.
- Mello FW, Miguel AF, Dutra KL, Porporatti AL, Warnakulasuriya S, et al. Prevalence of oral potentially malignant disorders: a systematic review and meta-analysis. *Journal of Oral Pathology & Medicine*. 2018; 47: 633-640.
- Tak J, Gupta N, Bali R. Oral submucous fibrosis: A review article on etio pathogenesis. *Kathmandu University Medical Journal*. 2014; 12: 153-156.
- Angadi PV, Krishnapillai R. Evaluation of PTEN immune expression in oral submucous fibrosis: role in pathogenesis and malignant transformation. *Head and neck pathology*. 2012; 6: 314-321.
- Samudrawar R, Mazhar H, Wasekar R, Tamgadge P, Tiwari RV, et al. Evaluation of Digital Palmar Dermatoglyphics in Oral Submucous Fibrosis and Leukoplakia: A Prospective Comparative Clinical Study. *Journal of Maxillofacial and Oral Surgery*. 2020; 1: 1-8.
- Munishwar PD, Thiyam B, Veerabhadrapa RS, Singh D, Tyagi K, et al. Qualitative analysis of dermatoglyphics in oral submucous fibrosis. *Journal of Indian Academy of Oral Medicine and Radiology*. 2015; 27: 207.
- Gupta A, Karjodkar FR. Role of dermatoglyphics as an indicator of precancerous and cancerous lesions of the oral cavity. *Contemporary clinical dentistry*. 2013; 4: 448.
- Mollaoglu N. Oral lichen planus: A review. *British Journal of oral and maxillofacial surgery*. 2000; 38: 370-377.
- Chiang CP, Chang JY, Wang YP, Wu YH, Lu SY, et al. Oral lichen planus—differential diagnoses, serum autoantibodies, hematitic deficiencies, and management. *Journal of the Formosan Medical Association*. 2018; 117: 756-765.
- Thongprasom K, Carrozzo M, Furness S, Lodi G. Interventions for treating oral lichen planus. *Cochrane database of systematic reviews*. 2011.
- Markopoulos AK. Current aspects on oral squamous cell carcinoma. *The open dentistry journal*. 2012; 6: 126.
- Massano J, Regateiro FS, Januário G, Ferreira A. Oral squamous cell carcinoma: review of prognostic and predictive factors. *Oral surgery, oral medicine, oral pathology, oral radiology, and endodontology*. 2006; 102: 67-76.
- Feller L, Lemmer J. Oral squamous cell carcinoma: epidemiology, clinical presentation and treatment.



14. Wangpermtam P, Sanguansin S, Petmitr S, Punyarit P, Weerapradist W. Genetic alteration in oral squamous cell carcinoma detected by arbitrarily primed polymerase chain reaction.
15. Rivera C, Venegas B. Histological and molecular aspects of oral squamous cell carcinoma. *Oncology letters*. 2014; 8: 7-11.
16. Feller L, Lemmer J. Oral squamous cell carcinoma: epidemiology, clinical presentation and treatment.
17. Sutton DN, Brown JS, Rogers SN, Vaughan ED, Woolgar JA. The prognostic implications of the surgical margin in oral squamous cell carcinoma. *International journal of oral and maxillofacial surgery*. 2003; 32: 30-34.
18. Ishida K, Tomita H, Nakashima T, Hirata A, Tanaka T, et al. Current mouse models of oral squamous cell carcinoma: genetic and chemically induced models. *Oral oncology*. 2017; 73: 16-20.
19. Ganvir SM, Gajbhiye NY. Detection of genetic predisposition in oral squamous cell carcinoma (OSCC) and oral submucous fibrosis patients by qualitative analysis of finger and palm-print patterns: A dermatoglyphic study. *Clinical Cancer Investigation Journal*. 2014; 3: 377.
20. Ganvir SM, Gajbhiye NY. Detection of genetic predisposition in oral squamous cell carcinoma (OSCC) and oral submucous fibrosis patients by qualitative analysis of finger and palm-print patterns: A dermatoglyphic study. *Clinical Cancer Investigation Journal*. 2014; 3: 377.
21. Vijayaraghavan A, Aswath N. Qualitative and quantitative analysis of palmar dermatoglyphics among smokeless tobacco users. *Indian Journal of Dental Research*. 2015; 26: 483.
22. Chandrasekaran S, Chellammal R, Ganapathy DM. Dermatoglyphics: A tool in dentistry. *Journal of Advanced Pharmacy Education & Research*. 2017; 7.
23. Munishwar PD, Thiyam B, Veerabhadrappe RS, Singh D, Tyagi K, et al. Qualitative analysis of dermatoglyphics in oral submucous fibrosis. *Journal of Indian Academy of Oral Medicine and Radiology*. 2015; 27: 207.
24. Koch WM, Choti MA, Civelek AC, Eisele DW, Saunders JR. Gamma probe-directed biopsy of the sentinel node in oral squamous cell carcinoma. *Archives of Otolaryngology-Head & Neck Surgery*. 1998; 124: 455-459.
25. Zhong LP, Zhang CP, Ren GX, Guo W, William Jr WN, et al. Randomized phase III trial of induction chemotherapy with docetaxel, cisplatin, and fluorouracil followed by surgery versus up-front surgery in locally advanced resectable oral squamous cell carcinoma. *Journal of clinical oncology*. 2013; 31: 744.
26. Jatti D, Kantraj YD, Nagaraju R. Role of dermatoglyphics in malignant and potentially malignant disorders of the oral cavity: A cross-sectional study. *Journal of Indian Academy of Oral Medicine and Radiology*. 2014; 26: 379.
27. Singh D. Dermatoglyphic pattern as a genetic marker and alteration in serum lipid profile as a screening tool in premalignant lesions and conditions and oral cancer: A Review Article.
28. Singh D. Dermatoglyphic pattern as a genetic marker and alteration in serum lipid profile as a screening tool in premalignant lesions and conditions and oral cancer: A Review Article.
29. Tang EL, Wei SH. Recording and measuring malocclusion: a review of the literature. *American Journal of Orthodontics and Dentofacial Orthopedics*. 1993; 103: 344-351.
30. Sidhu MS, Kharbanda OP, Sidhu SS. Cephalometric analysis of changes produced by a modified Herbst appliance in the treatment of Class II division 1 malocclusion. *British journal of orthodontics*. 1995; 22: 1-2.
31. Sidhu MS, Kharbanda OP, Sidhu SS. Cephalometric analysis of changes produced by a modified Herbst appliance in the treatment of Class II division 1 malocclusion. *British journal of orthodontics*. 1995; 22: 1-2.
32. Jindal G, Pandey RK, Gupta S, Sandhu M. A comparative evaluation of dermatoglyphics in different classes of malocclusion. *The Saudi Dental Journal*. 2015; 27: 88-92.