



A PIOSCC Case Report and Literature Review. The New WHO Classification

Michele Maglione¹; Rossana Bussani²; Nicolò Camurri Piloni^{2*}; Alvisè Camurri Piloni²; Giancarlo Tirelli⁴

¹Associate Professor, University Clinical Department of Medical, Surgical, and Health Sciences, University of Trieste, Trieste, Italy.

²Unit of Oral Surgery, School of Dental Sciences, University of Trieste, Trieste, Italy.

³Institute of Pathological Anatomy and Histology, Ospedale Riuniti and University of Trieste, Trieste, Italy.

⁴ENT Clinic, Head and Neck Department, Azienda Sanitaria Universitaria Giuliano Isontina, Trieste, Italy.

*Corresponding Author(s): Nicolò Camurri Piloni

Unit of Oral Surgery, School of Dental Sciences,
University of Trieste, Trieste, Italy.
Email: nicolo.camurripiloni@gmail.com

Abstract

Cyst-like lesions in the mandible rarely develop into malignancies, and the reported incidence is between 0.3 and 2%. The present study describes a rare case of primary intraosseous squamous cell carcinoma of the mandible arising from an odontogenic cyst. A 80-year-old male was referred to Trieste University Maggiore Hospital (Trieste, Italy), with acute pain in the left retromolar area. An initial examination revealed extra oral swelling without paresthesia of the IAN. Following an intraoral examination, the oral mucosa was edematous, percussion pain was experienced on the lower left second molar. Panoramic radiography revealed a retained lower left wisdom tooth and an irregular radiolucent area between the lower left second molar and the mandibular angle with clear margins. Computed tomography revealed diffuse bone resorption and an extensive loss of cortical bone on the lingual side. A biopsy was performed during the surgery to remove the second lower left molar and the wisdom tooth, the pathological diagnosis was of a squamous cell carcinoma arising from the epithelial lining of the odontogenic cyst. MRI with contrast agent was also performed. shortly after the patient has been proposed a complete respective surgery of the mass including the infiltrated areas and then a reconstructive part to restore the function and aesthetic.

Received: Jan 18, 2021

Accepted: Feb 09, 2021

Published Online: Feb 12, 2021

Journal: Annals of Dentistry and Oral Health

Publisher: MedDocs Publishers LLC

Online edition: <http://meddocsonline.org/>

Copyright: © Piloni NC (2021). *This Article is distributed under the terms of Creative Commons Attribution 4.0 International License*

Introduction

Primary Intraosseous Squamous Cell Carcinoma (PIOSCC) is a rare carcinoma arising, without any connection to the oral mucosa, from the odontogenic epithelium; the etiology is associated with the malignant degeneration of embryological remains, such as Malassez's epithelial rest. The factors responsible for the malignant transformation of the cystic lining remains

unclear; most common factor should be chronic inflammation and predisposing genetic cofactors. In 2017, the WHO defined PIOSCC like a central jaw carcinoma that cannot be categorized as any other type of carcinoma. It is assumed to arise from odontogenic epithelium. Some cases arise in odontogenic cysts or other benign precursors [1].



Cite this article: Maglione M, Bussani R, Piloni NC, Piloni AC, Tirelli G. A PIOSCC Case Report and Literature Review. The New WHO Classification. *Ann Dent Oral Health*. 2021; 4(1): 1029.

PIOC is rare. The incidence is low and approximately 200 cases are reported in literature [2].

The etiology seems to be related to the malignant degeneration of embryological remains. In this line, epithelial rests of Malassez, dental lamina and epithelium of the dental follicle represent potential suspects [3].

PIOC is more frequent in the posterior body and ramus of the mandible than in the maxilla, Maxillary lesions are usually in the anterior segment. Determining origin is important for diagnosis. Carcinoma arising in the oral mucosa and infiltrating the mandible, an antral primary, and metastatic carcinoma must be excluded, and ulceration to the oral cavity is normally considered to preclude definitive diagnosis. PIOC in the mandible usually arises above the inferior dental canal, whereas metastases usually have their epicenter below it. Cases arising in cysts are more common in the mandible.

Waldron and Mustoe proposed a different classification that has been widely accepted; however, certain more recently described types of odontogenic epithelial malignancies are not included. It is often difficult to definitively diagnose PIOSCC as the lesions need to be distinguished from alveolar carcinoma that could invade the bone from the overlying soft tissues or from tumors that have metastasized to the jaw from a distant site and from primary tumors of maxillary sinus origin. PIOSCC occurs between 1.3 and 90 years, with a mean age of 60.2 years; the incidence is much higher in males than females. Approximately only 200 cases have been reported to date. The most frequent area is molar-ramus region of the mandible and the most common clinical symptoms are swelling, pain/toothache and lesion growth; these symptoms are usually followed by trismus and hypoesthesia of mandibular nerve. Although the diagnostic criteria of PIOSCC remains still unclear, the following criteria have been suggested:

- 1) The tumor must be a histopathologically-based squamous cell carcinoma without the involvement of any other odontogenic cysts or metastatic tumor cells;
- 2) It must exhibit intact mucosa;
- 3) No other distant primary tumor must be present at the time of diagnosis, with at least a six-month absence of malignancy during the follow-up period.

In the current study, a case of PIOC arising from an odontogenic cyst is presented and the issues concerning the differential diagnosis and management are discussed. The patient provided written informed consent.

Case report

A 80-year-old male patient was referred to Trieste University, Maggiore Hospital (Trieste, Italy) with acute pain in the left retromolar area; there was no history of tobacco use, however the patient's medical history was significant for diabetes, hypertension and chronic kidney failure.

He arrived at the hospital, sent by his private dentist, due to acute pain in the retromolar area.

At the time of the visit, a previous parotid tumor of Warthin was reported in the patient's medical record.

Physical examination revealed first a left extraoral swelling without signs of paresthesia in the III branch of the ipsilateral V Cranial Nerve. Exploration of the oral cavity revealed dema-

tous oral mucosa in left retromolar region associated with pain evoked by percussion of element 3.7. The two-dimensional radiographic examination has the presence of impacted third molar associated with a radiolucent formation located between elements 3.7 and 3.8 characterized by predominantly defined margins.

A radiological investigation was subsequently requested three-dimensional by means of volumetric CT from which it was possible to appreciate an associated diffuse bone resorption to a considerable loss of both lingual and vestibular cortical walls. Subsequently, the extraction of elements 3.7 and 3.8 was planned and performed and at the same time a biopsy of the lesion was performed. The histological report revealed squamous cell carcinoma primary intraosseous developed from the lining epithelium of an odontogenic cyst. MRI with contrast medium was performed immediately after surgery which revealed a primitive neof ormation localized in the proximal third of the left mandibular branch, lytic expansive, infiltrating the distal end of the masseter muscle, the medial pterygoid muscle and marginally also the distal mandibular insertion of the ipsilateral mylohyoid muscle. There were also multiple lymph node swellings at levels I-II (a-b). The patient underwent segmental mandibulectomy associated with complete latero-cervical emptying followed by plastic reconstruction by means of a fibula and radial flap. During the surgical procedure it was not possible to use the fibula flap, due to removal, during the operation, also of the mandibular condyle.

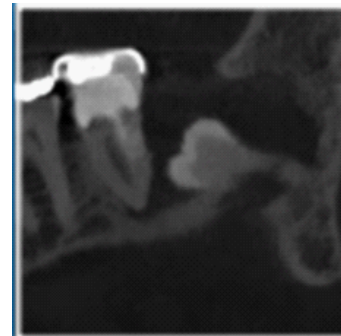

Figure 1: Element 3.7 with bone resorption. Considerable loss of both lingual and vestibular cortical walls.

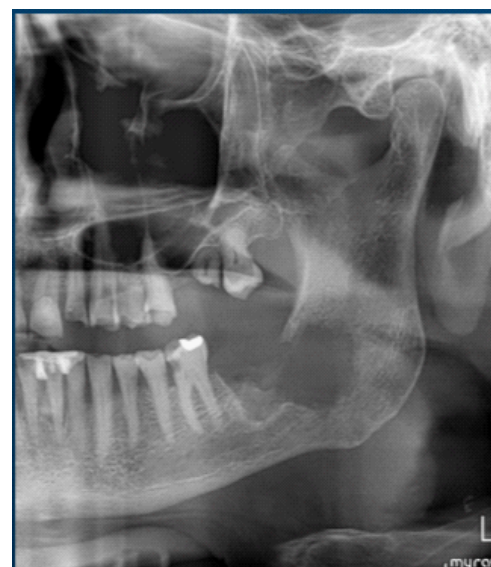

Figure 2: OPT after surgery.

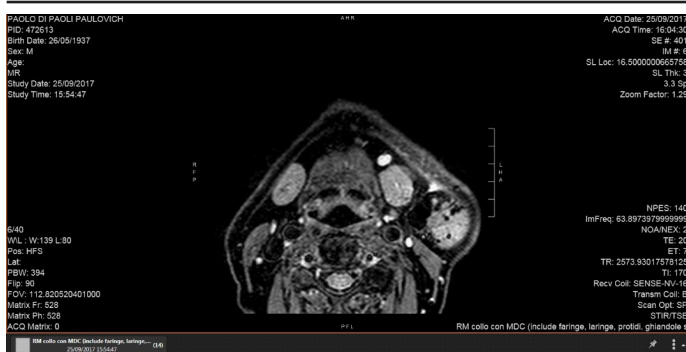

Figure 3: MRI with contrast. Revealed a primitive neoformation localized in the proximal third of the left mandibular branch, lytic expansive, infiltrating the distal end of the masseter muscle, the medial pterygoid muscle and marginally also the distal mandibular insertion of the ipsilateral mylohyoid muscle.

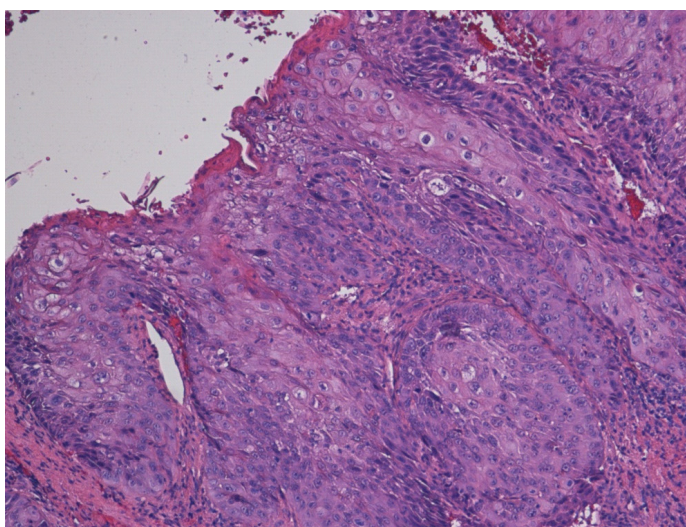


Figure 4: Histological report: Showing squamous cell carcinoma in a fibrous stroma.

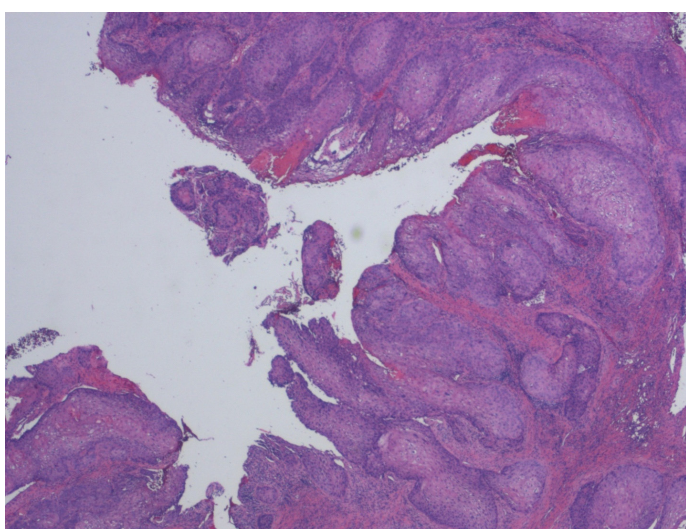


Figure 5: Histological report: Verrucous dysplasia in an odontogenic cyst. The features are primarily architectural, with limited or no cytological atypia.

Discussion

PIOC is rare [1]. As of 2011, only 116 cases arising in cysts had been reported [4]. As of 2001, 35 cases with no precursor lesion had been reported. The stringent diagnostic criteria for confident diagnosis of odontogenic origin are difficult to assess with certainty, and a precursor benign lesion can be confidently excluded or confirmed in only a minority of cases. All types of PIOC (whether developing in cysts or not) show a male predilection, with a male-to-female ratio of almost 2:1 (reflecting the prevalence of cysts) and a mean patient age diagnosis of 55-60 years. Although the age range is broad, and cases have been reported in children.

Most lesions are asymptomatic incidental radiographic findings. More advanced lesions cause non-specific signs and symptoms suggesting malignancy: slow-growing swelling of the jaw, pain, ulceration, loosening of the teeth, non-healing extraction sockets, pathological fracture, and nerve signs. Radiographically, the tumors produce a poorly defined, non-corticated radiolucency. Approximately 40% of patients have metastasis on presentation [3].

Radicular/residual cysts are the most common precursors, followed by dentigerous cysts and odontogenic keratocysts, reflecting their relative prevalence [5]. When the tumor is detected early, the radiological features appear benign and the carcinoma is an incidental histological finding on enucleation. More frequently, there is subtle loss of cortication or tooth resorption. Advanced lesions develop fully malignant appearances. The only evidence of the benign precursor cyst may be in previous radiographs [6].

Almost all lesions are squamous in type and composed of islands or small nests of neoplastic squamous epithelium, with pick-cell differentiation and without prominent keratinization. Many appear cytologically bland, and most are considered moderately differentiated. Necrosis is unusual. Some show limited peripheral palisading or a plexiform pattern that suggests their odontogenic origin. An insufficient number of cases have been reported to determine outcome, but prognosis is generally poor and is best predicted by histological grade. Radical resection has been the primary treatment modality, with neck dissection for metastasis or reconstruction. Multimodality treatment provides added benefit and has been reported to provide a 3-year survival rate of 40%. As many as 60% of lesions recur locally [1]; none series, patients with local recurrence all died of the disease. Distant metastasis is infrequent and is usually to lung. As of 2001, the 5-year survival rate of reported cases was 52% [6]. Cases arising in cysts often appear to be better differentiated and have more prolonged course, but the 5-year survival rate of reported cases is slightly lower, at 40%. When cysts are found to harbor incidental dysplasia or carcinoma in situ after enucleation, conservative close follow-up is appropriate.

According to Shear's study in 1969, the 5-year survival was 30-40% [6,7].

References

1. El-Naggar AK, Chan JKC, Grandis JR, Takata T, Slootweg PJ. WHO Classification of Head and Neck Tumors. WHO. 2017.
2. González García R, Sastre Pérez J, Nam Cha SH, Muñoz Guerra MF, Rodríguez Campo FJ, et al. Primary intraosseous carcinomas of the jaws arising within an odontogenic cyst, ameloblastoma, and de novo: Report of new cases with reconstruction considerations. Oral Surg Oral Med Oral Pathol Oral Radiol Endod. 2017.

3. Eversole LR. Malignant epithelial odontogenic tumors. *Semin Diagn Pathol*. 1999.
4. Lipa Bodner, Esther Manor, Mervyn Shear, Isaac van der Waal. Primary intraosseous squamous cell carcinoma arising in an odontogenic cyst: A clinicopathologic analysis of 116 reported cases. *Journal of oral pathology and medicine*. 2011.
5. Acikgoz A, Uzun-Bulut E, Ozden B, Gunduz K. Prevalence and distribution of odontogenic and nonodontogenic cysts in a Turkish Population. *Med Oral Patol Oral Circ Bucal*. 2012.
6. Wenguang X, Hao S, Xiaofeng Q, Zhiyong W, Yufeng W, et al. Prognostic Factors of Primary Intraosseous Squamous Cell Carcinoma (PIOSCC): A retrospective Review. *Plos One*. 2016.
7. Acharya S, Tayaar AS, Hallkeri K, Adirajaiah S, Gopalkrishnan K. Squamous cell carcinoma emerging in an ortho keratinized odontogenic cyst: A case report and brief review. *Journal of Oral and Maxillofacial Surgery Medicine and Pathology*. 2014.
8. Kikuchi K, Ide F, Takizawa S, Suzuki S, Sakashita H, et al. Initial-Stage Primary Intraosseous Squamous Cell Carcinoma Derived from Odontogenic Keratocyst with Unusual Keratoameloblastomatous Change of the Maxilla: A Case Report and Literature Discussion. *Case Reports in Otolaryngology*. 2018.