



# Pneumopericardium: A Case Report

**Ibrahima Sory Sylla<sup>1,2\*</sup>; Mamadou Aliou Baldé<sup>1,2</sup>; Sana Samoura<sup>2,3</sup>; Souleymane Diakité<sup>2</sup>; Bah Mamadou Bassirou<sup>1,2</sup>; Alpha Koné<sup>2,3</sup>; Ibrahima Sory Barry<sup>1,2</sup>; Maraimé Béavogui<sup>1,2</sup>; Djibril Sylla<sup>2,4</sup>; Elhadj Yaya Baldé<sup>1,2</sup>; Mamadi Condé<sup>1</sup>; Mamadou Dadhi Baldé<sup>1,2</sup>**

<sup>1</sup>Department of Cardiology Ignace Deen National Hospital, Conakry, Guinea.

<sup>2</sup>Faculty of Health Sciences and Techniques, Gamal Abdel Nasser University of Conakry, Guinea.

<sup>3</sup>Department of Cardiology Sino-Guinean Hospital, Guinea.

<sup>4</sup>Department of Internal Medicine CHU Donka, Guinea.

**\*Corresponding Author(s): Ibrahima Sory Sylla**

Gamal Abdel Nasser University of Conakry, Guinea.

Email: ibsosyl@gmail.com

## Abstract

Pneumopericardium is a rare but not exceptional condition. It represents the presence of air in the pericardial space. We report a case of pneumopericardium in a 21-year-old girl secondary to a road traffic accident.

Received: Dec 10, 2022

Accepted: Jan 02, 2023

Published Online: Jan 04, 2023

Journal: Annals of Cardiology Case Reports

Publisher: MedDocs Publishers LLC

Online edition: <http://meddocsonline.org/>

Copyright: © Sylla IS (2023). *This Article is distributed under the terms of Creative Commons Attribution 4.0 International License*

**Keywords:** Pneumopericardium; Trauma.

## Introduction

Pneumopericardium is defined as the presence of air within the pericardial space. Usually, it is a complication of blunt or penetrating chest trauma, but rare iatrogenic and spontaneous cases have been reported [1]. We report the case of a 21-year-old girl admitted to the emergency department for road traffic injury with a favourable outcome.

## Clinical case

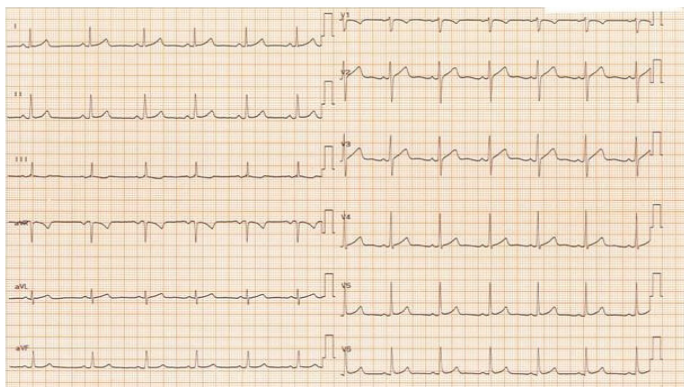
The patient was a 21-year-old girl with no previous history, admitted to the emergency room for trauma without loss of consciousness from the road after driving off the road at about 80km/h in a rollover. The patient was conscious, GCS 15/15, and hemodynamically stable on examination.

There was a rip wound on the right hand that could not be saturated and some leg abrasions: but no cervical or lumbar spine pain. The cardiopulmonary examination is without anomalies.

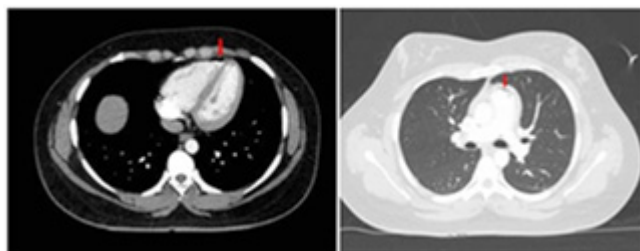
The Electrocardiogram (ECG) showed a regular sinus rhythm at 80 beats/min, an average PR interval, and no specific repolarization disorder (**Figure 1**). The chest X-ray was normal. The body scan showed a few anterior pericardial air bubbles with no fluid effusion (**Figure 2-3**); otherwise, an unremarkable examination. The Transthoracic Echocardiography (TTE) and the biological work-up were routine. The diagnosis of pneumopericardium was made. The patient was monitored for 48 hours without complications.



**Cite this article:** Sylla IS, Balde MA, Samoura S, Diakite S, Bassirou BM, et al. Pneumopericardium: A Case Report. *Ann Cardiol Case Rep.* 2023; 2(1): 1002.



**Figure 1:** Regular sinus rhythm at 80 beats/min, average PR interval, no specific repolarization disorder.



**Figure 2:** CT image showing the presence of some anterior pericardial air bubbles (red arrows).

### Discussion

Pneumopericardium is a rare but not exceptional condition. In 1910, Wenkebach first described the radiological findings of pneumopericardium; in 1967, Cimmino described the diagnostic features of pneumopericardium [2]. It is a pathology that can occur in the context of trauma, as in our case. However, other etiologies have been reported in the literature. Toledo et al. [3] classified the aetiology of pneumopericardium into four categories: iatrogenic, pericarditis, fistula formation between the pericardium and an adjacent air-containing organ, and trauma, as in our case. In addition, Cummings et al. [4] have reported that positive pressure ventilation is also a cause of pneumopericardium. Its management can vary from simple monitoring with therapeutic abstention, as in our patient's case, to surgical treatment by pericardial drainage.

### Conclusion

Pneumopericardium is a reality despite its rarity in our practice. However, in the face of any trauma, it should be considered, and a complete work-up should be performed.

### Note on consent

The patient's consent was obtained.

### Conflicts of interest

The authors have declared no conflicts of interest.

### Authors' contributions

All authors contributed to the development of this case, and we have their full approval for the publication of this article.

### References

1. Jinhyuck Lee, Bo Seung Kang, Changsun Kim, Hyuk Joong Cho. Tension Pneumopericardium after Pericardiocentesis. *J Korean Med Sci.* 2016; 31: 470-472.
2. Cimmino CV. Some radio-diagnostic notes on pneumomediastinum, pneumothorax, and pneumopericardium. *Va Med Mon.* 1967; 94: 205-212.
3. Toledo TM, Moore WL Jr, Nash DA, North RL. Spontaneous pneumopericardium in acute asthma: case report and review of the literature. *Chest.* 1972; 62: 118-120.
4. Cummings RG, Wesley RL, Adams DH, Lowe JE. Pneumopericardium resulting in cardiac tamponade. *Ann Thorac Surg.* 1984; 37: 511-518.