



# Intravascular Lithotripsy Success and Complications, A Real World Comparison Between Tertiary and General Hospital Setting

**Nancy Wassef<sup>1\*</sup>; David Sarkar<sup>2</sup>; Girish Viswanathan<sup>2</sup>; Prashanth Raju<sup>3</sup>; Ian Cox<sup>2</sup>; Venkatesan Suresh<sup>2</sup>; Mohsin Farooq<sup>3</sup>; Kai Hogrefe<sup>3</sup>; Sivasankar Sangaraju<sup>2</sup>; Salahaddin Ubaid<sup>1</sup>; Sandeep Basavarajiah<sup>4</sup>**

<sup>1</sup>Gloucestershire Hospitals Foundation Trust. Cheltenham General Hospital, Stanford Road, Cheltenham, Gloucestershire, UK. GL53 7AN and Gloucester Royal Hospital, Great Western Road, Gloucester, UK. GL1 3NN.

<sup>2</sup>University Hospitals of Plymouth NHS Trust. Derriford Hospital, Derriford Road, Plymouth, Devon, PL6 8DH.

<sup>3</sup>Kettering General Hospital. Kettering, Northamptonshire, UK. NN16 8UZ.

<sup>4</sup>Heart of England NHS Foundations Trust. Good Hope Hospital, Sutton Coldfield, Birmingham, UK. B75 7R.

## \*Corresponding Author(s): Nancy Wassef

Consultant Cardiologist, Gloucestershire Hospitals Foundation Trust. Cheltenham General Hospital Stanford Road, Cheltenham, Gloucestershire, UK.  
Tel: 07427490643; Email: nancy.wassef@gmail.com

## Abstract

**Introduction:** The use of Intravascular Lithotripsy (IVL) has expanded rapidly in heavily calcified coronary lesions. This is due to a modest learning curve and wide availability in Europe and United Kingdom.

**Objective:** In this study, we report real-world IVL experience in high-volume centres with comparison between a tertiary centre and a general hospital in United Kingdom, in terms of safety, efficacy and complications.

**Methods:** A retrospective analysis of all consecutive patients undergoing IVL for calcified coronary complex disease between November 2018-February 2021, in a tertiary centre and a general hospital in United Kingdom. The primary safety outcome was major adverse cardiac event (MACE) at 30 days, defined by cardiac death, myocardial infarction (MI) and target-vessel revascularization (TVR). Secondary efficacy outcome is angiographic success which was defined by post-procedural target-vessel stenosis <50% or stent expansion of at least 80%-90% if intracoronary imaging modality was used. In addition, if any adjuvant calcium modifying therapy were used and procedure adverse events or complications were collected.

**Results:** A total of 55 patients were treated with intravascular lithotripsy during the study period. The mean age was 71-73, with male preponderance. More left main disease and non-ST elevation acute coronary syndrome presentation were noted in the tertiary centre with 46% versus 37%.

Received: Feb 15, 2023

Accepted: Mar 24, 2023

Published Online: Mar 30, 2023

Journal: Annals of Cardiology and Vascular Medicine

Publisher: MedDocs Publishers LLC

Online edition: <http://meddocsonline.org/>

Copyright: © Wassef N (2023). *This Article is distributed under the terms of Creative Commons Attribution 4.0 International License*

**Keywords:** Intravascular lithotripsy; Calcified complex coronary disease; Percutaneous coronary interventions.

**Cite this article:** Wassef N, Sarkar D, Viswanathan G, Raju P, Cox I, et al. Intravascular Lithotripsy Success and Complications, A Real World Comparison Between Tertiary and General Hospital Setting. *Ann Cardiol Vasc Med.* 2023; 6(1): 1070.



MACE rate at 30 days was 0% in the tertiary centre and 3.7% in the general hospital due to MI in one patient with in-stent thrombosis and TVR. Procedural success was 96% in the tertiary centre and 100% in the general hospital. The IVL was used in two patients with under-expansion of acutely deployed stents in the tertiary centre, with satisfactory final expansion achieved, followed by drug eluting balloon.

In the tertiary centre four patients had ruptured IVL balloon, but there was sufficient lesion preparation which enabled successful stenting and expansion. One patient had coronary dissection and another patient had type 5 distal coronary perforation that required no interventions.

**Conclusion:** The use of IVL in real world showed a high success rate of 96%-100% in any hospital setting with a low MACE rate and complications. IVL was used off label in acutely under-expanded stents with good expansion achieved. Balloon rupture occurred, but the calcified lesions were adequately prepared to deploy stents. IVL was a safe and effective tool to modify calcified lesions for successful angioplasty in tertiary and district general hospitals with no significant difference between both settings.

## Introduction

Percutaneous coronary angioplasty advanced technology provided older patients a feasible long-term revascularisation outcome. However, with aging population the complexity of procedures heightens to negotiate the vasculature calcium burden. Coronary calcification is a frequent cause for failure of angioplasty [1]. Coronary artery calcification (CAC) is reported in about 10% of coronary angiograms with moderate-to-severe calcifications [2].

Several modalities have been used to overcome complex calcified coronary disease. These include noncompliant balloon, cutting balloons, scoring balloons and high-pressure twin layer non-compliant balloons. The rotational atherectomy was used for debulking and modification of the coronary calcifications for many years but had variable outcomes and complications relative to experience. Furthermore, the orbital coronary atherectomy was not widely accessible in Europe.

On the contrary, intravascular lithotripsy has been recently adopted for the management of heavily calcified coronary lesions. The catheter delivers localised pulsatile sonic pressure waves to modify the calcium. In several studies, it demonstrated effective and feasible outcomes [3,4].

## Objective

In this study, we report real world IVL experience in high-volume centres with comparison between a tertiary centre and a general hospital in United Kingdom, in terms of safety, efficacy and complications.

## Methods

A retrospective analysis of all consecutive patients undergoing IVL for calcified coronary complex disease between November 2018-February 2021, in high-volume tertiary centre and a high-volume general hospital in United Kingdom. The primary safety outcome was Major Adverse Cardiac Event (MACE) at 30 days, defined by cardiac death, Myocardial Infarction (MI) and Target-Vessel Revascularization (TVR).

Secondary efficacy outcome included angiographic success defined by post-procedural target-vessel stenosis <50% or stent expansion of at least 80% if intracoronary imaging modality was used. In addition, if other adjuvant calcium modifying therapy were used and procedure adverse events and complications were documented.

## Statistics

The results are presented as mean± standard deviation (SD) for continuous variables or numbers and percentages for categorical variables. The clinical endpoints are reported as percentages.

## Results

A total of 55 patients underwent IVL during the study period. The mean age was 71-73, with male preponderance. More left main disease was noted in the tertiary centre with 10.7% versus 3.7%, and non-ST elevation Acute Coronary Syndrome (ACS) presentation was noted in the former with 46% versus 37% with more patients having IVL in acute ST elevation setting in the general hospital patients (**Table 1**).

Severe calcification by angiography or by imaging was identified with calcium arc of more than 180 to 360 degrees and depth and length more than 5 mm, dependant on the imaging modality whether IVUS versus OCT, all patients had moderate to severe calcifications. Imaging was used more in tertiary centre in 32% versus 14.8% with mostly IVUS assessment and OCT used in one third of patients who had intravascular imaging modality.

Adjuvant therapy with noncompliant (NC) balloon, cutting, scoring and high-pressure balloons and Rotablation with 1.5 and 1.2 burr (**Table 2**). Rotational atherectomy and lithotripsy (Rotatripsy) was used in six patients in tertiary centre versus 2 patients. All patients had initial Rotablation that was not sufficient to modify and crack the calcium arc for which IVL was effective, except for one patient from each centre where rotablation was used post IVL using a 1.25 burr with prosperous results and angioplasty. One patient from the tertiary centre had OPN high pressure balloon after IVL with success.

MACE rate at thirty days was 0% in the tertiary centre and 3.7% in the district hospital due to myocardial infarction in one patient with acute in-stent thrombosis and TVR. No cardiac death was observed in all patients.

Procedural success was 96% in the tertiary centre and 100% in the general hospital, with one failed procedure in the tertiary centre due to inadequate guide catheter support and was not related to IVL (**Table 3**).

The IVL was used in two patients with under-expansion of acutely deployed stents in the tertiary centre, with satisfactory final expansion achieved with IVL, followed by drug eluting balloon. This was off label use of IVL balloon, which was successful.

In the tertiary centre four patients had ruptured IVL balloon, but there was sufficient lesion preparation that enabled successful stenting and expansion without other additional modalities for lesion preparation. One of these patients had balloon rupture at recommended pressure inflation and resulted in coronary dissection National Heart, Lung, and Blood Institute (NHLBI) type 1 which was successfully stented (**Figure 1**). It was noted that the balloon inflation was more than recommended pressures in one of these patients reaching 8 atmospheres rather

er than maximum recommended pressure of 6 atmospheres. There were no ruptured IVL balloons in the general hospital.

One patient had type 5 distal wire minor perforation with no pericardial effusion and was managed conservatively in the tertiary centre in contrary to the general hospital with no perforation observed.

**Table 1:** Demographics and presentation.

	Tertiary Hospital (28)	General Hospital (27)
Age	71	73.5
Male Gender	19 (67%)	23 (85%)
Diabetes Mellitus	10 (35%)	11 (40%)
Hypertension	17 (62%)	26 (96%)
Dialysis patients	0	0
Stable angina	12 (42%)	17 (63%)
Non-ST elevation acute coronary syndrome	13 (46%)	10 (37%)
ST elevation myocardial infarction	2(7%)	4(15%)
Preserved left ventricular function EF ≥55%	16(57%)	12(44%)
Left main stem disease	3(10.7%)	1(3.7%)
Left anterior descending artery	13(46%)	17(63%)
Left circumflex artery	6(21%)	6(22%)
Right coronary artery	9(32%)	4(15%)
Chronic total occlusion	1(3.5%)	1(3.7)
In stent restenosis	6(21%)	6(22%)

**Table 2:** Adjuvant therapy and procedure details.

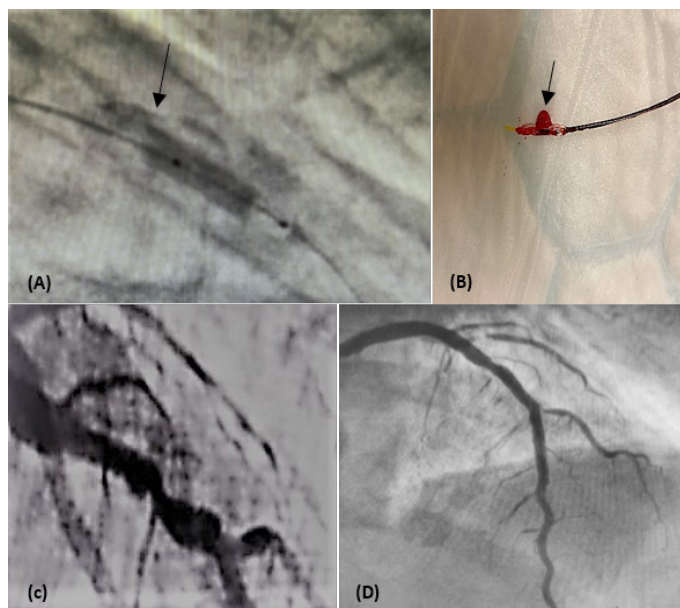
	Tertiary Hospital (28)	General Hospital (27)
Semi-compliant balloon	28 (100%)	14( 51%)
Noncompliant balloon	0	25(92.5%)
Scoring balloon	0	1(3.7%)
High Pressure OPN balloon	2(7.1%)	1(3.7%)
Cutting balloon	6(21%)	0
Rotablation	6(21%)	2 (7.4%)
Burr size	1.5	1.2
Guideliner support	17(62%)	12(44%)
IVL balloon mean size/mm	3.1±0.3	3.75 ± 0.5
IVL mean pulses delivered	50 ±30	40 ± 29
Imaging by IVUS or OCT	9 (32%)	4 (14.8%)
Radial access	21 (75%)	24 (88%)
Dose mean area product (DAP)/ Gy-cm(2)	55.7±46	30.9 ± 173
Conrast mean volume /ml	200±112	85 ± 92

**Discussion**

Coronary Artery Calcifications (CAC) impact percutaneous coronary interventions adversely with higher rate of complications and failure. The insufficient expansion and unpropitious patient outcomes raise the complexity of these procedures and reduce the success rate. The use of intravascular lithotripsy has been shown to have a high success rate of more than 90% in previous trials in CAC [3,4].

**Table 3:** MACE rate and adverse outcome.

	Tertiary Hospital (28)	General Hospital (27)
30 days MACE	0	1(3.7%)
Cardiac Death	0	0
Non cardiac Death	0	0
Myocardial infarction	0	1(3.7%)
TVR	0	1(3.7%)
Stroke	0	0
IVL Balloon Rupture	4 (14.2%)	0
Perforation	1 (3.5%)	0
Dissection	1 (3.5 %)	0
Vascular complications	0	0
Failure of procedure	1 (3.5%)	0



**Figure 1:** Ruptured IVL balloon. A and B: IVL balloon rupture arrow and after retrieval of balloon. C: calcified tight lesion before procedure. D: Final result after successful stent deployment.

Recent few real-world studies confirmed the safely and efficacy of IVL to facilitate angioplasty success in CAC [5,6]. The use of IVL has been quickly adopted by many centres with different settings and surgical coverage. We report the first comparison of the setting of using lithotripsy in a high-volume tertiary centre to a high-volume general hospital, whether this affects the intravascular lithotripsy success rate in coronary vessels or major adverse events or complications.

In our study, we assessed the success rate of IVL which proved to be 96-100% with no significant difference in any of the hospital settings with one failure attributed to poor guide catheter support and not related to lithotripsy. This real-world analysis is in concordance with the previously published success rates seen in the Disrupt trials with more than 90% success in high-risk population with calcified disease [3].

The major adverse events rate at thirty days was assessed to evaluate IVL safety by the Disrupt trials and initial real-world study by Wong et al. and was proved to be very low [7], this was confirmed by recent real-world analysis with low major adverse events rate in term of death, myocardial infarction, and target vessel revascularisation [5,6]. In our study, the thirty days MACE

rate was 3.7% in the general hospital setting due to acute in-stent thrombosis myocardial infarction and revascularisation in one patient. There was no cardiac death or stroke. There was one patient with a minor distal wire perforation with a hydrophilic wire that was conservatively managed, with no pericardial effusion in the tertiary centre.

In our study, four patients had intravascular lithotripsy balloon ruptured in the tertiary centre, but this did not preclude adequate lesion preparation and stenting. This has been previously reported Lee et al. with type E NHLBI dissection<sup>8</sup>, we had one case with type 1 NHLBI dissection that was successfully stented with no difficulty.

The use of intravascular imaging was used in one third of the tertiary centre patients and even less in the general hospital, due to high operators' speculations to deliver an IVUS or an OCT catheter through these calcified lesions. This is in contrary to a recent large real-world analysis where intravascular imaging was used in 85% [6].

Since the IVL was adopted for use in United Kingdom, the use of rotablation became infrequent. In our study, in selected patients the use Rotatripsy proved to be effective, with most patients having initial failure of rotablation to modify the calcium, nevertheless the lithotripsy balloon delivery was facilitated by rotablation. In the event of failed IVL delivery the 1.2 burr was efficient in modifying the lesions and proceeding further to successful stenting and expansion.

The adoption of intravascular lithotripsy allowed a feasible, safe, and effective management of calcified coronary arteries. The use of IVL is similar in all settings, in terms of safety and efficacy in with excellent outcomes in a high-risk population.

#### Funding

The authors declare no specific funding for this work.

#### Study limitations

Our study to our knowledge is the first study to compare the intravascular lithotripsy in different hospital settings and surgical coverage backup in high risk patients. Nevertheless, it is a retrospective comparative study. The intravascular imaging was underutilized, but this reflects real-world analysis.

#### Conclusion

The use of IVL in real world demonstrated a high success rate of 96%-100% in any hospital setting with a low MACE rate and complications. IVL was used off label in acutely under-expanded stents with good expansion achieved. Balloon rupture occurred, but the calcified lesions were adequately prepared to deploy stents. IVL was a safe and effective tool to modify calcified lesions for successful angioplasty in tertiary and district general hospitals with no significant difference between both settings.

#### Declaration of competing interest

The authors declare there are no competing interests.

#### References

1. Sharma SK, Bolduan RW, Patel MR, Martinsen BJ, Azemi T, et al. Impact of calcification on percutaneous coronary intervention: MACE-Trial 1-year results. *Catheter Cardiovasc Interv.* 2019; 94: 187-194.
2. Copeland-Halperin RS, Baber U, Aquino M, Rajamanickam A, Roy S, et al. Prevalence, correlates, and impact of coronary calcification on adverse events following PCI with newer-generation des: findings from a large multiethnic registry. *Catheter Cardiovasc Interv.* 2018; 91: 1-8.
3. Hill JM, Kereiakes DJ, Shlofmitz RA, Klein AJ, Riley RF, Price MJ, et al. Intravascular Lithotripsy for Treatment of Severely Calcified Coronary Artery Disease. *J Am Coll Cardiol.* 2020; 76: 2635-2646.
4. Kereiakes DJ, Hill JM, Ben-Yehuda O, Maehara A, Alexander B, et al. Evaluation of safety and efficacy of coronary intravascular lithotripsy for treatment of severely calcified coronary stenoses: Design and rationale for the Disrupt CAD III trial. *Am Heart J.* 2020; 225: 10-18.
5. Wiens EJ, Sklar JC, Wei YH, Aleem Q, Minhas K. Real-world outcomes in treatment of highly calcified coronary lesions with intravascular shockwave lithotripsy. *Indian Heart J.* 2021; 73: 653-655.
6. Basavarajaiah S, Ielasi A, Raja W, Naneishvili T, Testa L, et al. Long-term outcomes following intravascular lithotripsy (IVL) for calcified coronary lesions: A Real-World Multicenter European Study. *Catheter Cardiovasc Interv.* 2022.
7. Wong B, El-Jack S, Newcombe R, Glenie T, Armstrong G, Khan A. Shockwave Intravascular Lithotripsy for Calcified Coronary Lesions: First Real-World Experience. *J Invasive Cardiol.* 2019; 31: 46-48.
8. Lee TJ, Wan Rahimi WFB, Low MY, Nurruddin AA. Type E coronary artery dissection caused by intravascular lithotripsy balloon rupture; vessel anatomy and characteristics in a lithoplasty complication case as detailed by optical coherence tomography: a case report. *Eur Heart J Case Rep.* 2021; 5: ytab432.