



Radiation-Induced Organizing Pneumonia after Hypofractionated Whole Breast Radiotherapy for Breast Cancer

Eleni Kohilakis^{1*}; Michael Pennock²; Justin Tang^{1,2}; Jana Fox^{1,2}

¹Albert Einstein College of Medicine, Bronx, New York.

²Department of Radiation Oncology, Montefiore Medical Center, Bronx, New York.

*Corresponding Author(s): Eleni Kohilakis

Albert Einstein College of Medicine, Bronx, New York.
Tel: 914-806-3560; Email: eleni.kohilakis@einsteinmed.edu

Received: Mar 12, 2024

Accepted: Mar 29, 2024

Published Online: April 05, 2024

Journal: Annals of Breast Cancer

Publisher: MedDocs Publishers LLC

Online edition: <http://meddocsonline.org/>

Copyright: © Kohilakis E (2024). This Article is distributed under the terms of Creative Commons Attribution 4.0 International License

Keywords: Radiation-induced organizing pneumonia; Radiation toxicity.

Abstract

Purpose: Radiation-Induced Organizing Pneumonia (RIOP) is a rare complication observed after breast irradiation with few reported cases in the literature.

Patient: We present the case of a premenopausal 40-year-old female who presented with ER+/PR+/HER2- invasive ductal carcinoma in the right axillary tail. She underwent right lumpectomy and sentinel lymph node biopsy, which showed multifocal invasive carcinoma with mixed lobular and ductal features and a positive inferior margin. Her final pathologic stage was T1N0M0.

Result: The patient presented with a febrile illness with cough approximately three months following receipt of Radiation Therapy (RT). Her symptoms improved with a short course of steroids. Seven months after completing RT, CT showed likely RIOP, without any evidence of Radiation Pneumonitis (RP). The patient had no relapse of symptoms and required no further steroid administration. Repeat CT ten months after RT showed resolution of previous imaging findings.

Conclusions: RIOP is an uncommon side effect of RT. Here we present the case of a 40-year-old breast cancer patient who developed RIOP three months after RT without any evidence of RP. This case highlights the importance of considering RIOP as a complication after RT as well as the need for further research into genetic predisposition, risk factors, planning techniques, optimal management, and biological correlates related to RIOP.

two weeks with radiographic lung infiltrates outside of the radiation field and no evidence of another cause [3].

Risk factors typically include age (over 50 years old) [4], lung volume within the radiation field [5], concurrent anti-estrogen therapy [6], and tobacco smoking [1]. Some studies have found tamoxifen to be a risk factor for lung fibrosis [7], while it was found that the incidence of lung fibrosis was similar for patients receiving concurrent versus sequential aromatase inhibitors such as anastrozole [8].

Introduction

Radiation-Induced Organizing Pneumonia (RIOP) is a type of secondary organizing pneumonia that may be observed after breast irradiation. The prevalence of RIOP is about 0.8% to 2.9% in patients treated with radiation therapy to the breast [1]. RIOP usually occurs within 12 months of Radiation Therapy (RT) and presents as general or respiratory symptoms, such as cough, fever, shortness of breath, or fatigue [2], lasting for greater than



Cite this article: Kohilakis E, Pennock M, Tang J, Fox J. Radiation-Induced Organizing Pneumonia after Hypofractionated Whole Breast Radiotherapy for Breast Cancer. *Ann Breast Cancer*. 2024; 7(1): 1028.

The pathophysiology of RIOP includes three key stages. The injury stage involves death of pneumocytes, the proliferating phase consists of fibroblasts and inflammatory cells which infiltrate the alveolar interstitium and form fibroinflammatory buds, and in the mature phase fibrotic buds occupy the lumens of bronchioles, alveolar ducts, and per bronchiolar alveoli [9].

The pharmacologic management of RIOP most commonly involves corticosteroids, with patients experiencing symptom relief within one month of steroid administration [3]. In individuals with a poor response to steroids or an atypical disease course, bronchoscopy or video-assisted biopsy can be used in diagnosis. Management is symptom-oriented, so patients who do not require steroids may opt to avoid them, as once steroid therapy is initiated it may be difficult to terminate due to relapses [10,11].

Case and Clinical History: We present the case of a 40-year-old premenopausal female who originally presented with a self-palpated right breast mass towards the axillary tail. She had an extensive family history of breast cancer in her maternal grandmother, paternal aunt, and paternal grandmother. She never smoked, is a marathon runner, and has two children. Diagnostic mammography and ultrasound in June 2022 showed a suspicious irregular hypoechoic 0.5 x 0.6 x 0.9 cm mass in the right axillary tail with adjacent hypervascularity and no suspicious lymph nodes, BIRADS Category 4C.

On physical exam, cardiovascular, pulmonary, and neurological systems were within normal limits. Breast exam showed normal breast symmetry, no nipple discharge or retraction, and no dimpling, with a 1 cm palpable mass in the right axillary tail and no palpable masses within the left breast. No palpable lymphadenopathy was present.

A core biopsy of the right axillary tail mass showed well differentiated Invasive Ductal Carcinoma (IDC), Nottingham score 5/9, estrogen receptor positive (95%), progesterone receptor positive (75%), HER2 negative (IHC1+). The patient underwent right lumpectomy and sentinel lymph node biopsy in July 2022 which showed invasive carcinoma with mixed lobular and ductal features, multifocal (at least 5), largest 1 cm, moderately differentiated (Nottingham score 6 or 7/9), with negative sentinel nodes (0/3 lymph nodes) and a positive inferior margin which showed Lobular Carcinoma in Situ (LCIS). The final pathologic staging was Stage IA pT1N0M0, right-sided breast IDLC, Grade 2, ER+/PR+. The patient was then referred to radiation oncology as she was high-risk as per her age and positive inferior margins. Anastrozole was recommended for 5 years, along with ovarian suppression with goserelin.

Radiation Plan: The patient was treated with hypofractionated whole breast radiotherapy with a boost to the lumpectomy cavity, with the right lung receiving an appropriate volumetric dose which met safety constraints (Figure 1). She received 42.4 Gy in 16 daily fractions with a 10 Gy lumpectomy cavity boost to the right breast in the supine position using Three-Dimension Conformal Radiotherapy (3D-CRT). The supine position was used as the patient did not have a pendulous breast, and thus prone positioning was not necessary. Treatment was well-tolerated, with the only immediate toxicity being a grade 1 dermatitis of the right breast skin.

Post-Treatment Presentation: In January 2023, about three months after completing radiation therapy, the patient presented with a febrile illness with cough. She was treated with

a course of levofloxacin with no improvement. No bronchoalveolar lavage was done at this time. She was then prescribed a nine-day course of prednisone which improved symptoms. Chest X-ray in February 2023 showed right lower lobe dense infiltrates. She was then referred to a pulmonologist. Post-treatment CT scans, shown in Figure 2a and 2b with superimposed radiation therapy plan, were obtained. The first CT (Figure 2a), taken in April 2023 showed a right lower lobe ground glass and consolidative opacity. Pulmonary functioning testing conducted in April 2023 showed a restrictive pattern with normal diffusing capacity. The second CT (Figure 2b), taken in May 2023, showed a new opacity in the superior right lower lobe with resolution of the basilar right lower lobe opacity, as well as migratory parenchymal opacities that were favored to represent RIOP.

After the patient received steroids, she continued to improve with only occasional cough and mild dyspnea with exertion. Patient denied any fever, chills, or joint pain. As per the migratory nature of the dense consolidation, a diagnosis of Organizing Pneumonia (OP) possibly secondary to radiation was favored, with additional subpleural changes that seemed to correlate with radiation changes [12]. Pulmonology discussed bronchoscopy with biopsy to prove diagnosis of OP, empiric treatment for OP with steroids and Bactrim, or watchful waiting with another CT scan. Because the patient remained mostly asymptomatic and due to hesitation for “long term” steroid use, the joint decision was made to follow the patient with serial CT scans, with treatment or bronchoscopy reserved only in the case of relapsing symptoms. Repeat CT (Figure 2c) in August 2023 showed resolution of the right lower lobe opacities. The patient was therefore told she did not need further imaging. Shortly after she ran a marathon.

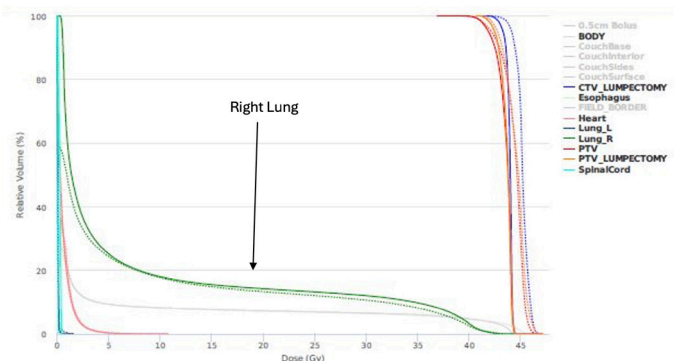


Figure 1a: Dose Volume Histogram.

Metric Values		
PTV (BreastPTV):		
V95% Rx1 (> 95.00 %) Per Protocol	99.67 %	417.88 cc
V90% Rx1 (> 90.00 %) Variation Acceptable	100.00 %	419.26 cc
D0.03cc (< 115.00 % Rx1) Per Protocol	104.85 % Rx1	44.46 Gy
D0.03cc (< 120.00 % Rx1) Variation Acceptable		
PTV_LUMPECTOMY (LumpectomyPTV):		
V95% Rx2 (> 95.00 %) Per Protocol	100.00 %	74.93 cc
V90% Rx2 (> 90.00 %) Variation Acceptable		
V110% Rx2 (< 5.00 %) Per Protocol	0.00 %	0.00 cc
V110% Rx2 (< 10.00 %) Variation Acceptable		
D0.03cc (< 115.00 % Rx2) Per Protocol	108.56 % Rx2	10.86 Gy
D0.03cc (< 120.00 % Rx2) Variation Acceptable		
Lung_R (Ipsilateral Lung):		
V20Gy (< 15.00 %) Per Protocol	14.36 %	180.34 cc
V20Gy (< 20.00 %) Variation Acceptable		
V10Gy (< 35.00 %) Per Protocol	18.36 %	230.53 cc
V10Gy (< 40.00 %) Variation Acceptable		
V5Gy (< 50.00 %) Per Protocol	26.00 %	326.49 cc
V5Gy (< 55.00 %) Variation Acceptable		
Lung_L (Contralateral Lung):		
V5Gy (< 10.00 %) Per Protocol	0.00 %	0.00 cc
V5Gy (< 15.00 %) Variation Acceptable		

Figure 1b: Summary Statistics (Planning Target Volume, Lungs).

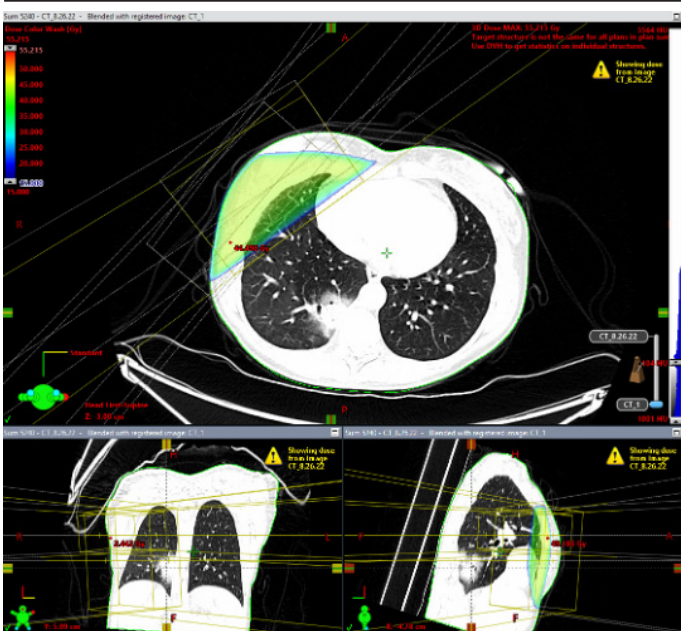

Figure 2a: CT chest with contrast, 6 months post-RT: “Right lower lobe ground-glass and consolidative opacity, likely reflects pneumonia.”

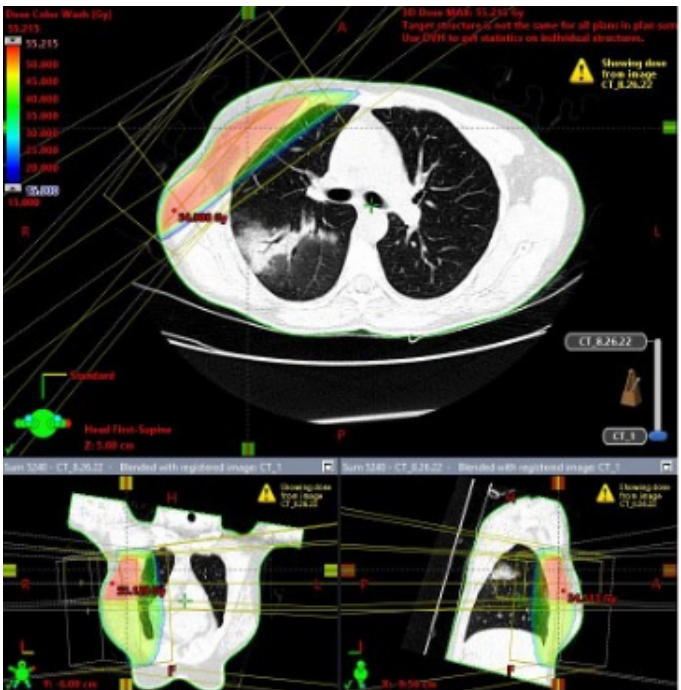


Figure 2b: CT chest without contrast, 7 months post-RT: “New opacity in the superior right lower lobe with interval resolution of basilar right lower lobe opacity. In this patient with history of radiation therapy and lack of aspiration risk factors, migratory parenchymal opacities are favored to represent radiation induced organizing pneumonia.”

Discussion

The differential diagnosis of RIOP may include infection, eosinophilic pneumonia, diffuse interstitial pneumonitis, radiation pneumonitis, tumor recurrence, or secondary malignancy. Bacterial pneumonia may resemble organizing pneumonia on radiographic examination, however in cases of RIOP, bronchoalveolar lavage (BAL) would be expected to show negative cultures, increased lymphocytes, mast cells, CD3 cells, and CD8 cells, with a decrease in CD4 cells and CD4/CD8 ratio [13]. Eosinophilic pneumonia would present similarly with a steroid-responsive migratory lung infiltrate, however the patient would be more

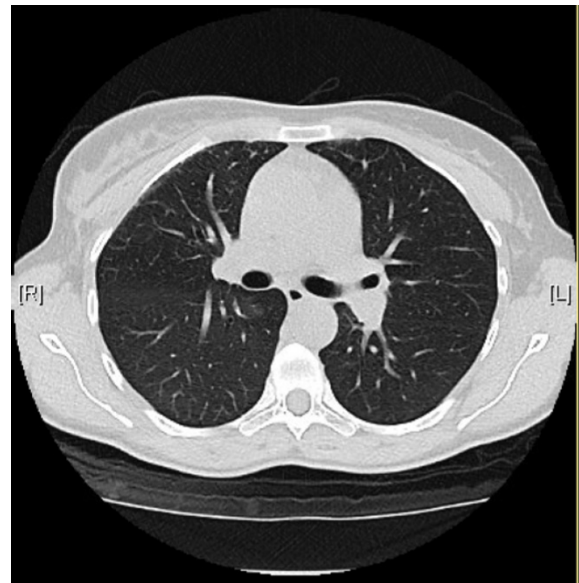


Figure 2c: CT chest without contrast: “Right lower lobe opacities seen on prior exam have resolved and may have represented pneumonia or noninfectious inflammation.”

	RP	RIOP
History of RT	X	X
Symptoms		
Cough	X	X
Fever	X	X
Dyspnea	X	X
Chest CT for work-up	X	X
Lung infiltrate inside RT field	X	
Lung infiltrate outside RT field		X
Can relapse after steroids		X

Figure 3: Comparison of RP versus RIOP (RP: Radiation Pneumonitis; RIOP: radiation-induced organizing pneumonia; RT: Radiation Therapy; CT: computed tomography).

likely to have a history of asthma, eosinophilia, and BAL showing eosinophils.

In a patient with a history of radiation exposure of the lung, RIOP and Radiation Pneumonitis (RP) can be mistaken for each other. However, several notable differences exist between the two entities (Figure 3). RP occurs due to a distinctly different process and is seen within the radiation field, while RIOP appears as migratory opacities outside of the radiation field [14]. RP occurs as the irradiated lung becomes fibrotic over time and can result in permanent scarring and pulmonary impairment. RIOP is an inflammatory process without fibrosis that does not correspond to the RT field. RP can be predicted by the volume of lung receiving 20 Gy or greater [15], while RIOP has no well-established dose-volume relationship. Acute RP occurs four to twelve weeks after RT, while subacute RP develops after three to six months secondary to fibrosis [16]. In contrast, RIOP occurs several months after completion of RT, with cases in the literature reporting diagnosis around six months after RT, but additional cases being reported between twelve to twenty four months after [3,17].

Radiologic findings commonly develop following the onset of clinical symptoms [18]. In RIOP, alveolar opacities are found on chest imaging with frequent involvement contralateral to the irradiated breast. A range of CT findings has been encountered in patients with organizing pneumonia, such as bilateral nodular areas of consolidation with associated ground glass changes, localized ground glass opacity, and bilateral irregular areas of

consolidation [19]. A 2013 study looked at 428 patients who underwent RT for breast cancer, and of the five patients that were diagnosed with RIOP, all OP lesions developed near - but not connected to - sites of concurrent RP [17], unlike the patient that we discuss in this case. They all developed migratory lesions to other parts of the lung as well. RIOP may be classified into four patterns using CT scans: Type A, peripheral area in the radiation field and a continuous opacity; type B, peripheral area in the radiation field and continuous alveolar infiltration in the middle lung; type C, peripheral area in the radiation field and an isolated consolidation on the back side of the radiation field; type D, consolidation or ground-glass attenuation in the contralateral side [20].

Very few cases of RIOP are documented in the literature. Shionoya et al report the case of a 69-year-old woman who was initially diagnosed with RP following carbon-ion RT for lung cancer when she developed fever and dyspnea 4 months later and an infiltrate was seen in the treatment field. She received prednisolone which improved symptoms, but relapsed each time the dose was tapered, with findings of consolidations in remote areas of the lung. She underwent BAL which revealed an elevated ratio of lymphocytes and no evidence of microbial infection and subsequently was diagnosed with RIOP based on her clinical course and examination results. She was maintained on a 6-month course of prednisolone and ultimately improved [21]. Ochiai examined 78 patients who underwent Stereotactic Body Radiotherapy (SBRT) for lung cancer, of whom 5 (6.4%) developed RIOP. Two patients received corticosteroids with clinical improvement, with one patient relapsing requiring re-administration, while three patients with minor symptoms did not receive corticosteroids and experienced full recovery [22]. A case series reported by Kawakami et al describes RIOP in nine patients, three of whom received steroid therapy and all developed recurrence, as well as six who received symptomatic treatment for their fever and cough without any recurrence [23]. Liu et al report the case of a 71-year-old female who developed radiation recall dermatitis and RIOP after RT and during chemotherapy for breast cancer, suggesting a shared inflammatory etiology [24].

There is ample room for research into genetic predisposition, risk factors, underlying pathophysiology, biological correlates, planning techniques, and optimal management of RIOP. Future research would require multi-institutional cohorts to achieve greater power in exploring potential predictors of RIOP such as concurrent endocrine therapy or if the patient received chemotherapy prior to RT. Tissue samples or growing organoids from patients with RIOP could be utilized for molecular studies to determine specific mutations or gene expressions.

A transgenic mouse model has been developed, overexpressing CCL2, which generates organizing pneumonia-like changes morphologically comparable to human patients. This model, using the human CC chemokine ligand 2 under control of the surfactant C promoter in type II alveolar epithelial cells, has been shown to have a similar inflammatory profile to human OP and can be used to further study OP pathogenesis [25]. Because some studies suggest RIOP can occur adjacent to areas of RP [17], it would be valuable to examine the interaction between RT and the immune system to create RIOP. As chances of RP increase with the increasing volume of lung receiving 20Gy or greater with conventional fractionation, perhaps the adjacent lung volume in the adjacent dose fall-off region can sometimes become immunogenic, promoting an initial focus of RIOP ad-

acent to RP. It would also be interesting to evaluate advanced lung sparing techniques such as Deep Inspiration Breath-Hold (DIBH) and proton therapy which may prove to be beneficial in reducing the incidence of RIOP.

Conclusion

RIOP is an uncommon side effect of RT. Here we present the case of a 40-year-old breast cancer patient with who developed RIOP three months after RT without any evidence of RP. This case highlights the importance of considering RIOP as a complication after RT as well as the need for further research into genetic predisposition, risk factors, planning techniques, and biological correlates related to RIOP.

Conflict of Interest: None.

Funding: None.

References

1. Epler GR, Kelly EM. Systematic review of postradiotherapy bronchiolitis obliterans organizing pneumonia in women with breast cancer. *Oncologist*. 2014; 19(12): 1216-26. doi:10.1634/theoncologist.2014-0041.
2. Cherian SV, Patel D, Machnicki S, et al. Algorithmic Approach to the Diagnosis of Organizing Pneumonia: A Correlation of Clinical, Radiologic, and Pathologic Features. *Chest*. 2022; 162(1): 156-178. doi:10.1016/j.chest.2021.12.659.
3. Otani K, Seo Y, Ogawa K. Radiation-Induced Organizing Pneumonia: A Characteristic Disease that Requires Symptom-Oriented Management. *Int J Mol Sci*. 2017; 18(2). doi:10.3390/ijms18020281.
4. Murofushi KN, Oguchi M, Goshio M, Kozuka T, Sakurai H. Radiation-induced Bronchiolitis Obliterans Organizing Pneumonia (BOOP) syndrome in breast cancer patients is associated with age. *Radiat Oncol*. 2015; 10: 103. doi:10.1186/s13014-015-0393-9.
5. Kubo A, Osaki K, Kawanaka T, Furutani S, Ikushima H, et al. Risk factors for radiation pneumonitis caused by whole breast irradiation following breast-conserving surgery. *J Med Invest*. 2009; 56(3-4): 99-110. doi:10.2152/jmi.56.99.
6. Katayama N, Sato S, Katsui K, et al. Analysis of factors associated with radiation-induced bronchiolitis obliterans organizing pneumonia syndrome after breast-conserving therapy. *Int J Radiat Oncol Biol Phys*. 2009; 73(4): 1049-54. doi:10.1016/j.ijrobp.2008.05.050.
7. Huang EY, Wang CJ, Chen HC, et al. Multivariate analysis of pulmonary fibrosis after electron beam irradiation for postmastectomy chest wall and regional lymphatics: Evidence for non-dosimetric factors. *Radiother Oncol*. 2000; 57(1): 91-6. doi:10.1016/s0167-8140(00)00211-5.
8. Azria D, Belkacemi Y, Romieu G, et al. Concurrent or sequential adjuvant letrozole and radiotherapy after conservative surgery for early-stage breast cancer (CO-HO-RT): A phase 2 randomised trial. *Lancet Oncol*. 2010; 11(3): 258-65. doi:10.1016/s1473-2045(10)70013-9.
9. Robertson BJ, Hansell DM. Organizing pneumonia: A kaleidoscope of concepts and morphologies. *Eur Radiol*. 2011; 21(11): 2244-54. doi:10.1007/s00330-011-2191-6.
10. Crestani B, Valeyre D, Roden S, Wallaert B, Dalphin JC, et al. Bronchiolitis obliterans organizing pneumonia syndrome primed by radiation therapy to the breast. The Groupe d'Etudes et de Recherche sur les Maladies Orphelines Pulmonaires (GERM"O" P). *Am J Respir Crit Care Med*. 1998; 158(6): 1929-35. doi:10.1164/

- ajrccm.158.6.9711036.
11. Otani K, Nishiyama K, Ito Y, Kawaguchi Y, Inaji H. Steroid treatment increases the recurrence of radiation-induced organizing pneumonia after breast-conserving therapy. *Cancer Med*. 2014; 3(4): 947-53. doi:10.1002/cam4.255.
 12. Davis SD, Yankelevitz DF, Henschke CI. Radiation effects on the lung: Clinical features, pathology, and imaging findings. *AJR Am J Roentgenol*. 1992; 159(6): 1157-64. doi:10.2214/ajr.159.6.1442375.
 13. Majori M, Poletti V, Curti A, Corradi M, Falcone F, et al. Bronchoalveolar lavage in bronchiolitis obliterans organizing pneumonia primed by radiation therapy to the breast. *Journal of Allergy and Clinical Immunology*. 2000; 105(2): 239-244. doi:https://doi.org/10.1016/S0091-6749(00)90071-X.
 14. Benveniste MF, Gomez D, Carter BW, et al. Recognizing Radiation Therapy-related Complications in the Chest. *Radiographics*. 2019; 39(2): 344-366. doi:10.1148/rg.2019180061.
 15. Ryckman JM, Baine M, Carmicheal J, et al. Correlation of dosimetric factors with the development of symptomatic radiation pneumonitis in stereotactic body radiotherapy. *Radiat Oncol*. 2020; 15(1): 33. doi:10.1186/s13014-020-1479-6.
 16. Bloom JR, Samstein RM. 31-Chest and thorax: Symptoms and toxicities. In: Vapiwala N, Jones JA, Dharmarajan KV, eds. *Palliative Radiation Oncology*. Elsevier. 2024: 359-366.
 17. Oie Y, Saito Y, Kato M, et al. Relationship between radiation pneumonitis and organizing pneumonia after radiotherapy for breast cancer. *Radiat Oncol*. 2013; 8: 56. doi:10.1186/1748-717x-8-56.
 18. Libshitz HI, Southard ME. Complications of radiation therapy: The thorax. *Semin Roentgenol*. 1974; 9(1): 41-9. doi:10.1016/0037-198x(74)90008-x.
 19. Beardsley B, Rassl D. Fibrosing organising pneumonia. *J Clin Pathol*. 2013; 66(10): 875-81. doi:10.1136/jclin-path-2012-201342.
 20. Ogo E, Komaki R, Fujimoto K, et al. A Survey of Radiation-Induced Bronchiolitis Obliterans Organizing Pneumonia Syndrome After Breast-Conserving Therapy in Japan. *International Journal of Radiation Oncology*Biophysics*. 2008; 71(1): 123-131. doi:https://doi.org/10.1016/j.ijrobp.2007.09.003.
 21. Shionoya Y, Katsumata M, Kasai H, et al. Radiation-induced organizing pneumonia caused by carbon-ion radiotherapy for lung cancer. *Radiol Case Rep*. 2024; 19(2): 567-571. doi:10.1016/j.radcr.2023.11.012.
 22. Ochiai S, Nomoto Y, Yamashita Y, et al. Radiation-induced organizing pneumonia after stereotactic body radiotherapy for lung tumor. *J Radiat Res*. 2015; 56(6): 904-11. doi:10.1093/jrr/rrv049.
 23. Kawakami H, Miyabayashi T, Tsubata C, Ota K, Ishida T, et al. Spontaneous resolution of thoracic radiation therapy-induced organizing pneumonia: A case series. *Respir Med Case Rep*. 2019; 26: 180-184. doi:10.1016/j.rmcr.2019.01.009.