



Benign stromal tumor: Breast images

Maha Abdel Hadi¹; Weddad Bagatada²; Hassan Al Ahmadi³

¹Department of Surgery, Imam Abdulrahman Bin Faisal University, Saudi Arabia

²Department of Radiology, Imam Abdulrahman Bin Faisal University, Saudi Arabia

³Department of Pathology, Imam Abdulrahman Bin Faisal University, Saudi Arabia

***Corresponding Author(s): Maha Abdel Hadi**

Breast Division, Department of Surgery, Imam
Abdulrahman Bin Faisal University Dammam, Saudi
Arabia
Email: mhadi@uod.edu.sa

Received: Oct 25, 2018

Accepted: Feb 11, 2019

Published Online: Feb 15, 2019

Journal: Annals of Breast Cancer

Publisher: MedDocs Publishers LLC

Online edition: <http://meddocsonline.org/>

Copyright: © Hadi MA (2019). *This Article is distributed under the terms of Creative Commons Attribution 4.0 International License*

Clinical Image Description

A 70 years old female of suburban descent presented to the breast specialty clinic with 10 years history of a left enlarging painless breast mass not associated with local or systemic symptoms. There were no associated comorbidities or family history of breast cancer. Systemic examination was unremarkable. Local breast examination revealed obvious breast asymmetry with a large 10 × 11-centimeter smooth, non-tender, mobile mass occupying the retro-areolar and central regions of the left breast. The overlying skin was stretched over the lesion with tortuous dilated superficial veins. No palpable axillary lymphadenopathy (Figure 1).

Breast images suggested the benign nature of the lesion based on the breast ultrasound which showed an out of range solid breast lesion with intact capsule, Contrast Mammography

(Figure 2) demonstrating the well circumscribed nature of the mass and further confirmation by MRI that depicted the abundant peripheral blood supply (Figure 3).

Core biopsy was reported as spindle cells infiltrating the fibrous tissue in both linear and curvy-linear fashion. Nor mitosis or necrosis were identified.

Patient underwent Complete surgical excision with ease leaving grossly normal compressed breast tissue in the cavity. The striking intraoperative findings was a well capsulated soft tissue mass with large tortuous blood supply running along the peripheral surface of the lesion (Figure 4).

Immuno-histological staining was reported as ER +ve, PR+ve, Her2 -ve with Ki67 5%. The presence of desmin and CD34 sug-



gested the final diagnosis of the rare Mammary Myofibroblastoma (Figure 5ab).

Recurrence is unlikely following wide local excision with clear resection margins.

Acknowledgment

Special appreciation to Dr. WeddadBagatada and Dr. Hassan AlAhmadi for contributing in radiology and pathology materials.

Images

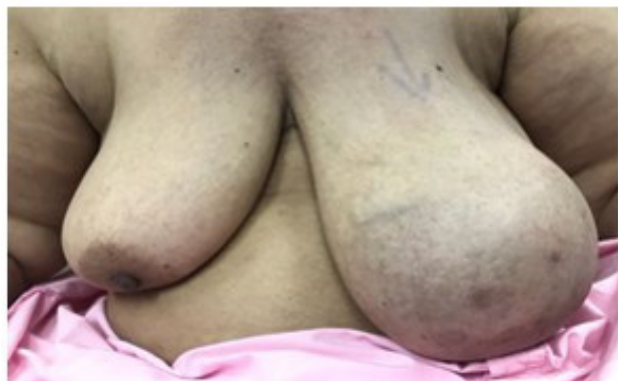

Figure 1: Showed obvious asymmetry between the two breasts with no evidence of skin or nipple changes.

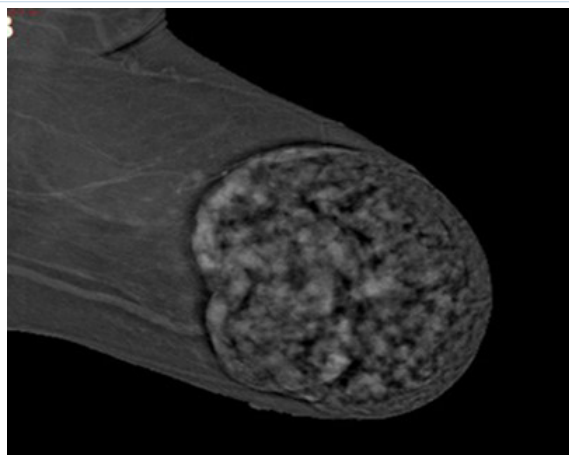


Figure 2: Contrast enhancing left mammogram, demonstrating the well circumscribed breast lesion with thicked capsule.

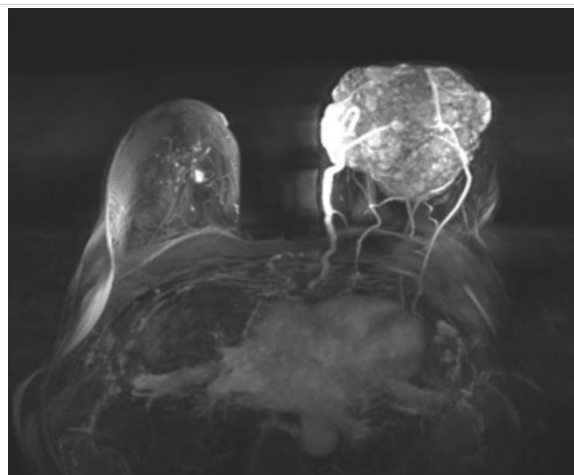


Figure 3: MRI showing a large well-defined lobulated progressively enhancing mass with non-enhancing septa is occupying anterior and mid breast with dilated peripheral feeding blood ves-sels.

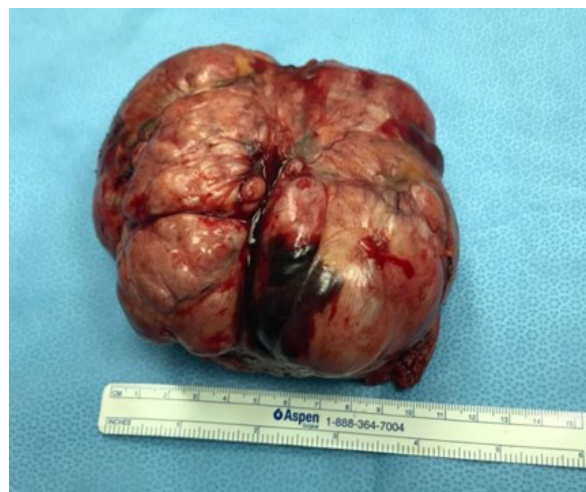

Figure 4: shows the excised well circumscribed capsulated and lobulated fibro- fatty mass.

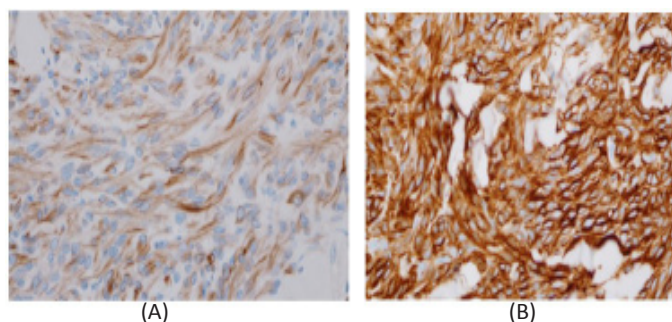


Figure 5: Immunohistochemical profile of the neoplastic cells demonstrating a) Desmin & b) CD34.