



# Novel Ink - Stained Reflectance Confocal Microscopy Guided Pigmented Skin Lesion Biopsy Technique: Reducing Pathology Sample Bias Through Improved Precision

Joanna Ludzik<sup>1,2\*</sup>; Claudia Lee<sup>2,3</sup>; Alexander Witkowski<sup>2</sup>; Jonathon Hetts<sup>2</sup>; Sancy Leachman<sup>2</sup>

<sup>1</sup>Department of Telemedicine and Bioinformatics, Jagiellonian University Medical College, Krakow, Poland.

<sup>2</sup>Department of Dermatology, Oregon Health and Sciences University, Portland, Oregon, USA.

<sup>3</sup>School of Medicine, University of California Riverside, Riverside, California, USA.

**\*Corresponding Author(s): Joanna Ludzik**

Department of Telemedicine and Bioinformatics,  
Jagiellonian University Medical College, 3181 SW Sam  
Jackson Park Rd, 97239, Portland, USA.  
Email: ludzik@ohsu.edu

Received: Jan 22, 2022

Accepted: Feb 15, 2022

Published Online: Feb, 18, 2022

Journal: Annals of Biotechnology

Publisher: MedDocs Publishers LLC

Online edition: <http://meddocsonline.org/>

Copyright: © Ludzik J (2022). *This Article is distributed under the terms of Creative Commons Attribution 4.0 International License*

**Keywords:** Reflectance confocal microscopy; RCM; RCM-guided biopsy; Confocal microscopy.

## Introduction

With skin cancer incidence rate steadily increasing each year, melanoma continues to pose a significant public health problem globally. It is well-known that early detection and prevention of melanoma remains the most important intervention for reducing morbidity and mortality, therefore it is imperative to promote innovation that will advance our ability to diagnose melanoma early. Because prognosis and treatment are dependent on the depth of dermal involvement, definitive diagnosis

of melanoma can only be made through histopathologic assessment [1]. Thus, appropriate sampling of tissue is critical for the accurate evaluation of melanoma.

Current guidelines recommend that when complete excision of a suspicious pigmented lesion is not appropriate, a punch biopsy be taken from the darkest or most elevated area of the lesion [2-4]. This sampling protocol is based on literature suggesting that the darkest and thickest part of a melanoma represents the most fully developed portion that involves the dermis



**Cite this article:** Ludzik J, Lee C, Witkowski A, Hetts J, Leachman S. "Novel Ink-Stained Reflectance Confocal Microscopy Guided Pigmented Skin Lesion Biopsy Technique: Reducing Pathology Sample Bias Through Improved Precision". *Ann Biotechnol.* 2022; 5(1): 1023.

and this protocol is widely adopted in clinical practice [5]. Other recommendations include sampling areas containing specific features, such as small dark dots, that have known associations with melanoma [6]. However, when applying this method to lesions that demonstrate great histological heterogeneity, such as in Lentigo Maligna (LM), sampling error remains a significant barrier to accurate diagnosis. In a study comparing the histopathologic findings of suspicious pigmented lesions, Somach et al. followed these guidelines for all biopsies and the results demonstrated a staggering 40% sampling error [7]. In addition, there have been many other studies that report similar findings of significant sampling error while following recommended guidelines [8-12], therefore developing new methods to minimize sampling bias is necessary for improving diagnostic accuracy.

Recently, many innovative skin cancer detection technologies have been developed to increase diagnostic accuracy, including Reflectance Confocal Microscopy (RCM). RCM is an advanced non-invasive imaging modality that utilizes a diode laser to obtain a live cytologic view of cellular structures in each layers of the skin [13]. The valuable utility of RCM in the early detection of melanoma, especially in clinically equivocal lesions, is well documented in existing literature. Furthermore, RCM can incorporate digital dermoscopy images, which allows experts to correlate suspicious findings on RCM to a specific area of the lesion [13]. By identifying and isolating the area of concern, RCM may be a useful tool to guide biopsies and optimize the selection of pathology slide preparation. To the best of our knowledge, there is only one reported technique that utilized RCM to guide biopsy. In a case of LM, Robinson et al. incorporated a previously described technique that utilizes adhesive tape to clearly delineate the area of interest. By creating a 3 mm window for visualization in the tape, the lesion is evaluated through the window by handheld RCM (Vivascope 3000; Caliber ID), constantly repositioning the tape until concerning RCM features are identified and then a punch biopsy is performed through the perforation [14]. Although Robinson et al. were able to successfully demonstrate how this technique can be used to minimize sampling error; there are many limitations of this method that may inhibit its widespread adoption including time for complete assessment, restricted for use with handheld RCM only, and inability to guide excisional biopsies. We propose an alternative method of RCM-guided biopsy that may be an effective solution to these issues.

### **Ink stained RCM-guided biopsy**

We would like to introduce a novel ink-stained RCM-guided biopsy technique that aims to minimize biopsy-sampling error and increase the likeliness of obtaining an accurate diagnostic histopathologic assessment. In our proposed method, a pigmented lesion that is suspicious or equivocal on dermoscopic evaluation is further evaluated with either traditional RCM (Vivascope 1500; Caliber Imaging and Diagnostics, Inc.) or handheld RCM (Vivascope 3000; Caliber Imaging and Diagnostics, Inc.) to determine need for biopsy. Evaluation of the lesion with RCM is conducted as part of a standard assessment, where the decision to use traditional or handheld RCM can be based on applicability and tailored to each individual case.

When using traditional RCM, a digital dermoscopic image of the lesion is taken with the attached scope (VivaCam; Caliber Imaging and Diagnostics, Inc.) prior to scanning to generate a dermoscopic overview for navigation during confocal examination. The dermatoscopic overview and the confocal image cor-

relate precisely, thus if concerning features are noted on RCM, the exact area of the lesion that contains the suspicious findings is highlighted in the dermoscopic image as seen in Figure 1a. After identifying the area of the lesion that correlates with the highlighted dermoscopic image, and always ensuring matching orientation, a small drop of surgical ink is applied with a dip applicator (prior to biopsy) to serve as a landmark for pathologists (Figure 1b). After waiting 15 seconds, a safe non-caustic fixative solution made with acetic acid (Figure 2b) is sprayed on the lesion and must be left for another 15 seconds. Any excess ink is removed using gauze. Once the lesion is stained and fixed, it can be removed appropriately, usually as an excisional biopsy, however this technique allows for multiple types of biopsies to be performed as normal. The surgical ink used is a sterile dye (Margin Marker ink; Vector Surgical) traditionally used to optimize intraoperative tissue orientation and margin marking [15]. The ink securely adheres to tissue and brightly stains the area for easy recognition by pathologists, therefore aiding in localization during histopathological assessment.

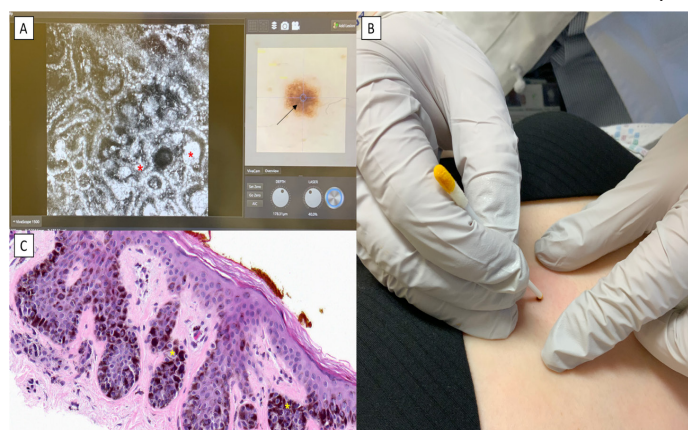
If a lesion covers a large surface area or is located in an area, challenging to evaluate with traditional RCM, such as the face, our proposed ink-stained guided biopsy technique can be applied to handheld RCM. Utilizing this method, the lesion is evaluated with the handheld RCM as per usual protocol, scanning the entire lesion until an area of interest or concern is identified. Prior to evaluation with RCM, the provider should ensure that the surgical ink kit is prepped and accessible for immediate staining. Once the area of concern is identified on RCM, the examiner must take note of the placement of where the handheld scope is on the lesion, and then carefully remove the scope followed by immediate application and fixation of the surgical ink as described above. The field of vision for handheld RCM scope is limited to 1 x 1 mm<sup>2</sup> [16] and represents the area that demarcates concerning features of malignancy, allowing for biopsies to be targeted within millimeters of RCM-identified suspicious features.

### **Discussion**

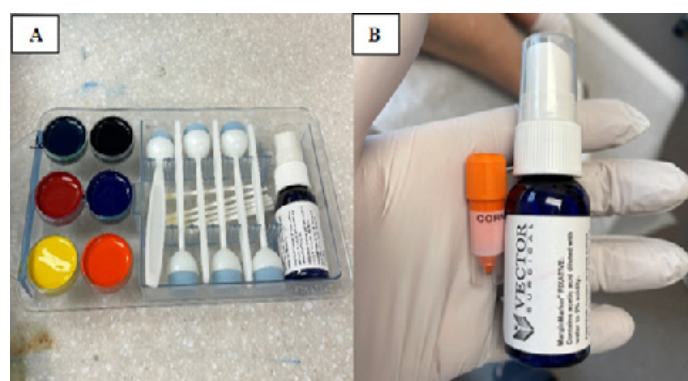
Histopathological assessment of biopsied samples remains the gold standard for definitive diagnosis of melanoma and is a widely accepted and trusted practice by the dermatology community. Current guidelines recommend a full-thickness excisional biopsy, in which the sample extends into the subcutaneous fat beneath the tumor, as the diagnostic procedure for pigmented lesions suspicious for melanoma [8]. This provides the pathologist with the maximum opportunity to diagnose a malignant melanoma in a given biopsy sample and accurately assess the Breslow depth, a vital prognostic factor used for staging and management of the patient. Although guidelines strongly encourage excisional biopsy whenever applicable, partial biopsies such as incisional, punch, or shave biopsies may be appropriate in selected clinical circumstances. These include evaluation of large facial or acral lesions, lesion diameter >2 cm, concern about cosmesis or tissue laxity, or when the suspicion of melanoma is low [17-18]. However, partial biopsies of pigmented lesions should be exercised with caution as many studies report significantly higher rates of misdiagnosis with punch or shave biopsies through sampling bias, inability to assess overall architecture, and induction of pseudo-melanoma [19-20]. Despite these findings, numerous articles still report increasing practice of partial biopsies amongst providers and is responsible for over 50% of false-negative melanoma misdiagnosis [19-22]. Therefore, it is imperative that advancements

geared towards improving lesion localization and minimizing sampling error continue to be explored.

The application of RCM in aiding the diagnosis of various skin malignancies is well established in literature; however, techniques demonstrating its utility in guiding biopsies are just beginning to emerge. To the best of our knowledge, only one technique has been previously described by Robinson et al. in which the authors incorporated previously described tape techniques to map and direct biopsy [14]. Using this method, the authors were able to demonstrate the applicability of handheld RCM in navigating large, traditionally challenging lesions for biopsy optimization; however, this technique has several limitations that restrict its clinical utility. For example, the technique described by Robinson et al. requires constant repositioning of the adhesive tape and handheld RCM over the entire lesion until the area of concern can be identified. This can become very time-consuming, especially when evaluating large lesions, which negates the benefit of using handheld RCM. Often, when evaluating large or anatomically complicated lesions, handheld RCM is preferred for its ability to conduct efficient and rapid en-face evaluation [23]. In addition, this technique can only be used with handheld RCM, which comes with its own unique



**Figure 1:** (A) Traditional reflectance confocal microscopy (Vivascope 1500; Caliber Imaging and Diagnostics, Inc.) showing heterogenous nests of melanocytes (red asterisks) in the dermal epidermal junction corresponding to the atypical globules seen around 3 o'clock on the dermoscopic image (black arrow). (B) Careful application of sterile surgical ink (Vector Surgical) to the corresponding area of the mole that is concerning on confocal microscopy. (C) H&E staining (20x) demonstrating small melanocytic nests (yellow asterisks) that are distinctly stained by the surgical dye and single melanocytes along the basal layer.



**Figure 2:** (A) Vector Surgical Margin Marker ink kit showing sterile dye with dip applicators. (B) Vector Surgical Margin Marker Fixative spray containing acetic acid used to adhere the dye to the specimen.

challenges including requiring necessary expertise and training that limit its widespread adoption. Furthermore, because this method relies on a small 3-mm perforation in the adhesive tape to delineate the area of interest for sampling, this technique is only suitable for punch biopsies.

Our proposed novel ink-stained RCM-guided biopsy technique is an alternative solution for optimizing lesion localization that is time-sensitive, inexpensive, and versatile. With this technique, RCM evaluation of suspicious lesions may be conducted per usual protocol, making it less time-consuming and arduous compared to previously reported techniques. In addition, this procedure is applicable for both traditional and handheld RCM use which enables more widespread utility of this method. Lastly, unlike the previously described tape technique that is limited to punch biopsies, our method can be applied to lesions requiring excisional biopsies, which remains the current recommendation for sampling pigmented lesions suspicious for melanoma. We have successfully utilized this technique on 7 cases of RCM-identified suspicious pigmented and non-pigmented lesions, all of which have been found to be concordant with histopathologic assessment. It is important to note that this technique, while simple to follow, relies heavily on the precision of ink placement on the lesion, and special attention should be made during this step. This highlights how the use of the described reflectance confocal microscopy guided biopsy technique can be used to improve localization for biopsies for challenging cases and increase diagnostic accuracy in an efficient and time-sensitive manner that may have more widespread appeal compared to previously described techniques.

#### Funding Source

This was funded with resources from the Skin Imaging and Technology Center in the Department of Dermatology at Oregon Health and Sciences University.

#### Statement of consent

The patient participating in the image acquisition signed the consent form.

#### References

1. Jaimes N, Marghoob AA. An update on risk factors, prognosis and management of melanoma patients. *G Ital Dermatol Venereol.* 2012; 147: 1-19.
2. Pavri SN, Clune J, Ariyan S, Narayan D. Malignant Melanoma: Beyond the Basics. *Plast Reconstr Surg.* 2016; 138: 330e-340e.
3. Balch CM, Houghton A, Milton G, et al. Biopsy of Melanoma in Cutaneous Melanoma: Clinical Management and Treatment Results Worldwide. 2nd ed. Philadelphia, Pa: JB Lippincott Co. 1991: 264-268.
4. Roses DF. Principles of biopsy of lesions suspected of being malignant melanomas. In: Harris MN, Roses DF, Ackerman AB, eds. *Diagnosis and Management of Cutaneous Malignant Melanoma.* Philadelphia, Pa: WB Saunders Co. 1983: 105-112.
5. Kasprzak JM, Xu YG. Diagnosis and management of lentigo maligna: A review. *Drugs Context.* 2015; 4: 212281.
6. Bolognia JL, Lin A, Shapiro PE. The significance of eccentric foci of hyperpigmentation ('small dark dots') within melanocytic nevi. *Analysis of 59 cases. Arch Dermatol.* 1994; 130: 1013-1017.
7. Somach SC, Taira JW, Pitha JV, Everett MA. Pigmented lesions in actinically damaged skin: histopathologic comparison of biopsy and excisional specimens. *Arch Dermatol.* 1996; 132: 1297-1302.

8. Tadiparthi S, Panchani S, Iqbal A. Biopsy for malignant melanoma--are we following the guidelines? *Ann R Coll Surg Engl*. 2008; 90: 322-325.
9. Montgomery BD, Sadler GM. Punch biopsy of pigmented lesions is potentially hazardous. *Can Fam Physician*. 2009; 55: 24.
10. Ng PC, Barzilai DA, Ismail SA, Averitte RL Jr, Gilliam AC. Evaluating invasive cutaneous melanoma: is the initial biopsy representative of the final depth? *J Am Acad Dermatol*. 2003; 48: 420-424.
11. Saco M, Thigpen J. A retrospective comparison between preoperative and postoperative Breslow depth in primary cutaneous melanoma: how preoperative shave biopsies affect surgical management. *J Drugs Dermatol*. 2014; 13: 531-536.
12. Stevens G, Cocherell CJ. Avoiding sampling error in the biopsy of pigmented lesions. *Arch Dermatol*. 1996; 132: 1380-1382.
13. Dorrell DN, Strowd LC. Skin Cancer Detection Technology. *Dermatol Clin*. 2019; 37: 527-536.
14. Robinson M, Soyer HP, Salkeld A. A case of recurrent lentigo maligna diagnosed with precise reflectance confocal microscopy-guided biopsy technique. *JAAD Case Rep*. 2020; 6: 394-396.
15. Altman AM, Nguyen DD, Johnson B, Marmor S, Klein ME, et al. Intraoperative inking is superior to suture marking for specimen orientation in breast cancer. *Breast J*. 2020; 26: 661-667.
16. Franceschini Chiara, Flavia Persechino, Marco Ardigò. "In Vivo Reflectance Confocal Microscopy in General Dermatology: How to Choose the Right Indication." *Dermatology practical & conceptual*. 2020; 10: e2020032.
17. Ho VC, Milton GW, Sober AJ. Biopsy of melanoma. In: Balch C, editor. *Cutaneous Melanoma*. 2nd edition. Philadelphia, Pa, USA: JB Lippincott. 1992: 264-268.
18. Australian Cancer Network Melanoma Guidelines Revision Working Party. *Clinical Practice Guidelines for the Management of Melanoma in Australia and New Zealand*. Wellington, New Zealand: The Cancer Council Australia, Australian Cancer Network. Biopsy. 2008; 35-39.
19. Dymock R, Menz J. Recurrent melanocytic naevi following partial removal (pseudomelanoma). *Australas J Dermatol*. 1986; 27: 67- 69.
20. Ng JC, Swain S, Dowling JP, Wolfe R, Simpson P, et al. The Impact of Partial Biopsy on Histopathologic Diagnosis of Cutaneous Melanoma: Experience of an Australian Tertiary Referral Service. *Arch Dermatol*. 2010; 146: 234-239.
21. Salopek TG, Slade J, Marghoob AA, Rigel DS, Kopf AW, et al. Management of cutaneous malignant melanoma by dermatologists of the American Academy of Dermatology. I. Survey of biopsy practices of pigmented lesions suspected as melanoma. *J Am Acad Dermatol*. 1995; 33: 441-450.
22. Hieken TJ, Hernández-Irizarry R, Boll JM, Jones Coleman JE. Accuracy of diagnostic biopsy for cutaneous melanoma: implications for surgical oncologists. *Int J Surg Oncol*. 2013; 2013: 196493.
23. Marino ML, Rogers T, Sierra Gil H, Rajadhyaksha M, Cordova MA, et al. Improving lesion localization when imaging with handheld reflectance confocal microscope. *Skin Res Technol*. 2016; 22: 519-520.