



# Management of Atypical Upper Airway Obstruction in a Child with Embryonal Rhabdomyosarcoma - Airway Challenge in COVID-19 Pandemic!

**Parin Lalwani\***; Renu Sinha; Kelika Prakash; Abhishek Singh

Department of Anaesthesiology, Pain Medicine and Critical Care, AIIMS, New Delhi, India.

## \*Corresponding Author(s): Parin Lalwani

Department of Anaesthesiology Pain Medicine  
Critical Care, AIIMS, E12 Ansari Nagar West campus  
AIIMS, New Delhi, India  
Tel: 09650533388, Fax: 01126588641;  
Email: drparinlalwani@gmail.com

## Abstract

Children with anatomical and physiological peculiarities in airway often pose challenges to the anaesthesiologist. This predicament is further increased if presentation of upper airway obstruction is atypical especially in this covid pandemic. It requires careful clinical evaluation of the degree of airway obstruction and good communication with surgeons and entire team for the successful outcome. We discuss airway management of a two years old child with nasopharyngeal rhabdomyosarcoma posted for emergency tracheostomy.

Received: Oct 29, 2020

Accepted: Nov 20, 2020

Published Online: Nov 24, 2020

Journal: Annals of Anesthesia and Pain Medicine

Publisher: MedDocs Publishers LLC

Online edition: <http://meddocsonline.org/>

Copyright: © Lalwani P (2020). *This Article is distributed under the terms of Creative Commons Attribution 4.0 International License*

**Keywords:** Embryonal Rhabdomyosarcoma; Airway; COVID-19.

## Introduction

Several anatomical and physiological variations make pediatric airway prone to obstruction. Upper airway obstruction can rapidly progress from partial to complete obstruction leading to fatal outcomes in children [1].

During the ongoing coronavirus disease (COVID-19) pandemic, wearing an N95 mask and face shield is mandatory for personal protection at the time of airway management. However, this may lead to compromised vision due to fogging. Further challenges to the anesthesiologists multifold in case of emergency airway management in a child with stridor and unusual airway obstruction.

## Case description

With N95 face mask and face shield and after confirming negative COVID-19 by real-time reverse-transcriptase-polymerase chain reaction (*rRT-PCR*) test, we examined a case of 2 year old child with a history of nasopharyngeal mass and stridor posted for emergency tracheostomy and biopsy of the mass.

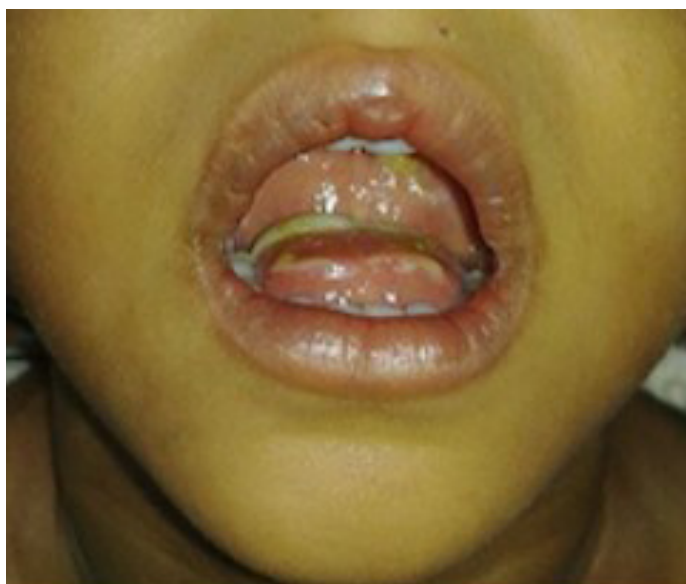Child weight was 12 kg and presented to pediatric emergency with complaints of difficulty in breathing along with stridor and dysphagia for 2 months. Child also had history of nasal discharge and voice change for one month. Difficulty in breathing was gradual in onset and was worsening for last 2 months. Initially, the child used to snore while he was asleep in supine



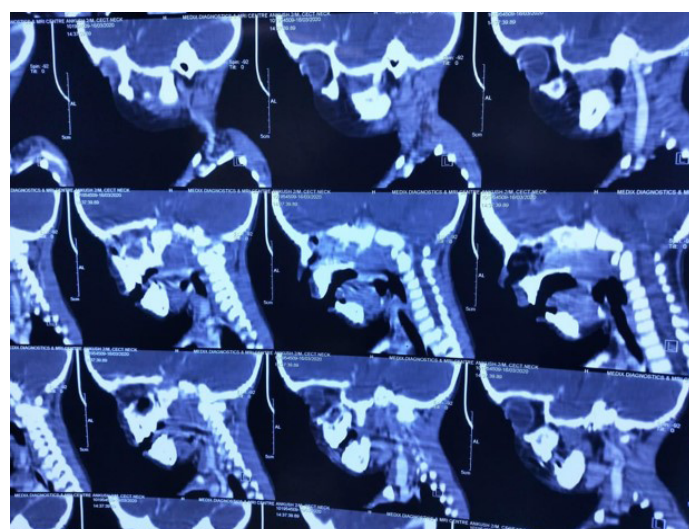
**Cite this article:** Lalwani P, Sinha R, Prakash K, Singh A. Management of Atypical Upper Airway Obstruction in A Child with Embryonal Rhabdomyosarcoma -Airway Challenge in COVID-19 Pandemic!. Ann Anesth Pain Med. 2020; 3(1): 1015.

position but later on, he was not able to sleep in supine position due to dyspnea. The dyspnoea had suddenly increased for last few hours. The child had dysphagia for solids which progressed substantially, and for last 3-4 days he had difficulty in taking liquids also.

On examination, child was tachypneic (respiratory rate 35 breaths/min) with 98% saturation on oxygen by facemask @5L/min in sitting position. Further clinical examination revealed running nose, nasal flaring, chest retractions, use of accessory muscles of respiration, and bilateral wheeze along with mild inspiratory stridor. Airway examination revealed bulging soft palate abutting tongue, the posterior pharyngeal wall could not be seen (Figure1). Discussion with ENT surgeon revealed mass was not present inside the oral cavity, it was arising from nasopharynx and was not fragile as examined through tongue depressor and anterior rhinoscopy. Computed Tomographic (CT) scan suggested homogenous soft tissue lesion in the region of posterior pharynx and adenoid measuring 830×34×30 mm obliterating nasopharynx, extending to posterior nares and concha more on the right side and causing bulge of the pharyngeal wall and soft palate (Figure 2).



**Table 1:** Soft Palate Abutting the Tongue.



**Table 2:** CECT of Head and Neck (Sagittal Section).

The child was scheduled for emergency tracheostomy and biopsy of the mass. Informed parental consent was taken.

The child was shifted in sitting position in the operating room with oxygen supplementation @ 5l/min. Standard ASA monitors ECG and pulse oximetry and noninvasive blood pressure cuff were attached and a difficult airway cart (oral airways, different types of laryngoscope, video laryngoscope, and different sizes of endotracheal tubes, stylet and tracheostomy set) was kept ready. The surgeon was ready for emergency tracheostomy. A 24 gauge IV cannula was secured and intravenous glycopyrrolate 0.12 mg and hydrocortisone 25 mg was administered.

Anesthesia was induced with the help of pediatric circle system with attached end tidal carbon dioxide (EtCO<sub>2</sub>) while the child was in a semi-sitting position with the support of a pillow with gradually increasing sevoflurane concentration from (4-8%) and 100% oxygen. With increasing depth of anesthesia as suggested by loss of jaw tone, difficulty in ventilation was observed due to airway obstruction. Preoperatively ENT surgeon could visualize posterior pharyngeal wall with tongue depressor, guided us to insert oropharyngeal airway to facilitate spontaneous respiration with intermittent CPAP provided by closing APL valve to 10 cm of H<sub>2</sub>O and positive pressure ventilation. After attaining an adequate depth of anesthesia as suggested by inspiratory minimum alveolar concentration of sevoflurane of 2.2, check laryngoscopy was done with C- Mac<sup>®</sup> video laryngoscope (Karl Storz, Tuttlingen, Germany) Mackintosh blade #1 and Cormack lehane grade 2a was visible.

Intravenous succinylcholine 25 mg was administered and bag-mask ventilation was resumed. Trachea was intubated with a size 4.5 mm ID uncuffed endotracheal tube and anesthesia was maintained with 50% oxygen + 50% air, and 2% sevoflurane. Pressure-controlled ventilation with inspiratory pressure of 20 cm of H<sub>2</sub>O I: E ratio of 1:2, PEEP of 3 was used. Intravenous fentanyl 25 mcg and atracurium 6 mg was administered. Child positioned for tracheostomy by placing shoulder roll and neck extension, and no further difficulty in ventilation was observed. Surgery started and tracheostomy was uneventful. Thereafter biopsy of the nasopharyngeal mass was performed and hemostasis was achieved. Child was shifted to pediatric ICU for gradual weaning to room air which was successfully done over a period of 2 days. Biopsy reported embryonal rhabdomyosarcoma and the child was referred to oncology for chemotherapy.

## Discussion

Rhabdomyosarcoma is the third most common childhood solid tumor after neuroblastoma and Wilms tumor. Head and neck are the most affected sites [2].

Embryonal rhabdomyosarcoma presenting as nasopharyngeal mass requiring emergency airway management has not been described in the literature. Only three cases of rhabdomyosarcoma arising from tongue have been reported for airway management [3-5]. This is an atypical presentation of a large tumor arising from nasopharynx abutting tongue and causing oral and nasal obstruction and respiratory distress in supine position in a small child. Challenges of securing airway further enhances due to collapsible nature of the airway and limited time to react in this age group.

As child was not able to lie supine, induction of anesthesia was done in semi-sitting position to prevent collapse of the airway. Agitation and anxiety can worsen respiratory distress in a child with upper airway obstruction. Pre-induction intravenous

line was secured after weighing the risks and benefits of a crying child with an irritable airway and upper airway obstruction requiring urgent resuscitation any time during induction due to sudden loss of patent airway. We did not prefer intravenous induction due to the possibility of difficulty in maintaining the oxygenation and ventilation in case of failed intubation. We preferred inhalational induction as chances of apnea are more with intravenous induction in comparison to graded inhalational induction. In the event of apnoea in a patient with anticipated difficult mask ventilation, a failed intubation would have been disastrous. Though inhalational induction maintains spontaneous respirations it depresses the tone of upper airway musculature which may aggravate tumor compression and worsen airway obstruction as happened in our case. Discussion with ENT surgeon and CT scan report suggested mass was not fragile and was compressing soft palate from nasopharynx with clear oropharynx and supraglottic airway, we gently inserted oral airway to bypass the obstruction and facilitate ventilation. In some cases turning the patient to lateral, semi-prone or prone position may also prove life-saving under anesthesia [6]. It relieves refractory airway obstruction by taking some weight of the tumor away from the airway.

Corticosteroids cause bronchodilation and have proven to be beneficial in edema and inflammation of upper airway caused by airway manipulation. Continuous positive airway pressure ventilation was used at the time of induction to assist oxygenation through obstructed airway.

C- Mac® video laryngoscope helped in obstructed airway in semi-sitting position as it does not require alignment of oral, pharyngeal, and laryngeal axis for successful visualization of glottis and the anesthesiologist can be at a distance from oral cavity in the COVID time [7]. Since upper airway obstruction was bypassed through tracheostomy child could be easily weaned off from ventilator within 2 days and chemotherapy started.

## Conclusion

In children with stridor, preoperative assessment should include aggravating and relieving factors for airway obstruction. In COVID-19 times, detailed anesthesia planning and effective communication with the entire team especially surgeon should be done for a successful outcome.

## References

1. Whitten CE. 10 Common Pediatric Airway Problems— and Their Solutions. *Anesthesiology News Airway Management*. 2019; 51-69.
2. Shern JF, Yohe ME, Khan J. Pediatric Rhabdomyosarcoma. *Crit Rev Oncog*. 2015; 20: 227-243.
3. Upadhya KR, Ramavakoda CY, Ravindra M, Ganigara A. Management of predicted difficult airway with conventional techniques in an infant with rhabdomyosarcoma of the upper lip. *IJA*. 2017; 61: 508-510.
4. Skelton VA, Goodwin A. Perinatal management of a neonate with airway obstruction caused by rhabdomyosarcoma of the tongue. *British Journal of Anesthesia*. 1999; 83: 951-955.
5. Mohan KK, Lal A. Congenital embryonal rhabdomyosarcoma of the tongue. *Anesth Analg*. 1992; 74: 930-931.
6. HarlessJ, Ramaiah R, Bhananker SM. Pediatric airway management. *Int J Crit Illn Inj Sci*. 2014; 4: 65-70.
7. Krishna SG, Bryant JF, Tobias JD. Management of the Difficult Airway in the Pediatric Patient. *J Pediatr Intensive Care*. 2018; 7: 115-125.