



Anaesthesia for Video Assisted Thoracoscopic Surgery in A 7 year Old Child

V Vishnu Teja¹; Sandeep Kadam²; KR Kulkarni³; Dypatil⁴

¹Department of Anaesthesia, 3RD Year PG Resident, Dr dypatil hospital and research centre, India.

²Department of Anaesthesia, Professor, Dr dypatil hospital and research centre, India.

³Department, Professor and HOD, Dr dypatil hospital and research centre, India.

⁴Department of Anaesthesia, Research Centre, Dr dypatil hospital and research centre, India.

***Corresponding Author(s): V Vishnu Teja**

Department of Anaesthesia, 3rd Year PG Resident,
Dr dypatil hospital and research centre, India.
Email: vishnuteja36@gmail.com

Received: Jul 01, 2022

Accepted: Aug 16, 2022

Published Online: Aug 17, 2022

Journal: Annals of Anesthesia and Pain Medicine

Publisher: MedDocs Publishers LLC

Online edition: <http://meddocsonline.org/>

Copyright: © Vishnu Teja V (2022). *This Article is distributed under the terms of Creative Commons Attribution 4.0 International License*

Introduction

Empyema thoracis is one of thoracic surgical entities that present with clinical challenges due to significant morbidity and even mortality. Its prevalence is increasing globally. [1,2] it most commonly occurs in the setting of bacterial pneumonia.

Open or VATS pleural decortication is an effective initial approach for advanced empyema. They are both equally effective as they allow to achieve the essential steps for full lung expansion, decortication of pleural peels, disruption of loculation, and fluid evacuationthor.

VATS decortication is feasible and safe alternative, as it provides a better visualization of the entire pleural cavity. It is associated with lower morbidity rate, lower cost, shorter hospital stay, and good postoperative functional, and cosmetic outcomes compared to standard thoracotomy approach.

Video-Assisted Thoracoscopic Surgery (VATS) is a less invasive approach for thoracoscopic surgery providing better visualization through minimal access. In addition, it offers less post-operative pain, fewer operative complications, and shortened hospital stay. These advantages make VATS ideal for the pediatric age group.

Case presentation

We report to you a 7year old child, 22kg came with chief complaints of breathlessness and high fever since 5 Days, child was diagnosed with b/l pneumonia with pleural effusion, needle drainage done, on repeated xray empyema was diagnosed later icd was placed to drain the collection, empyema on right was not subsiding for which the child was posted for thoracoscopic video assisted decortication.



Cite this article: Vishnu Teja V, Sandeep Kadam S, Kulkarni KR, Dypatil. Anaesthesia for Video Assisted Thoracoscopic Surgery in A 7 year Old Child. Ann Anesth Pain Med. 2022; 5(2): 1030.

Examination

Patient was conscious, active afebrile

Vitals: p – 120/min, BP- 90/60mmhg RR: 40/MIN

► **RS:** Air entry decreased on right side compared to left
TACHYPNEA+ b/l subcostal retractions+

► **CVS:** S1 S2 heard

Pallor +, no icterus cyanosis, clubbing, lymphadenopathy
b/l pedal edema +, with mild facial puffiness

Investigations

CBC: HB: 8.5

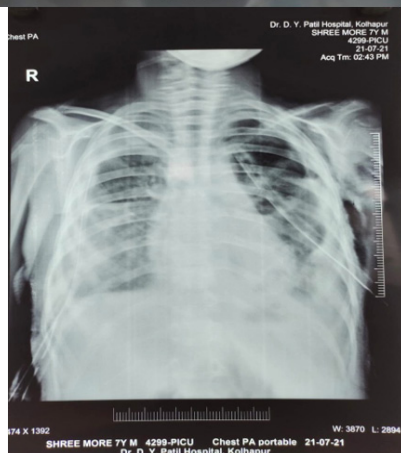
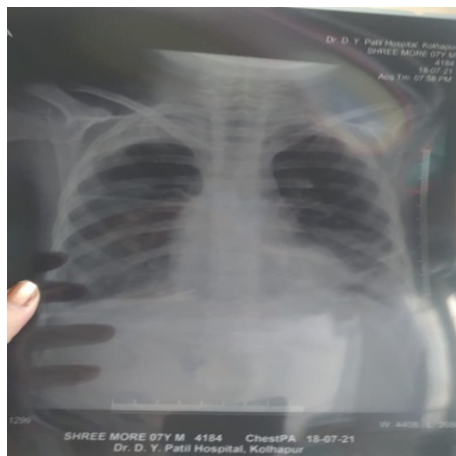TLC: 17,300

PLATELETS: 1,31,000 RBS: 98mg/dl

UREA: 21.4 CREAT: 1.3

S/E:134/3.8/108

- LFT: WNL.
- X-Ray Chest: Bilateral extensive aptchy consolidation with partial loss of lpower lobes.
- ECG: Sinus tachycardia.
- USG Chest: Bilateral pleural effusion with internal septations on right side and underlying partial collapse of both lower lobe.
- Ct Chest: Bronchopneumonia with right empyema with loculated pleural collection in right upper lobe and left lower.

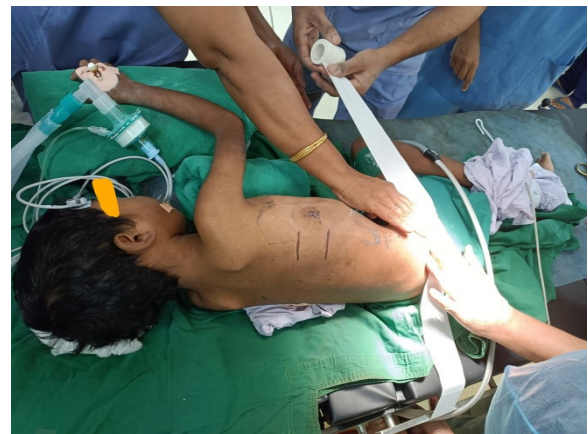

Management

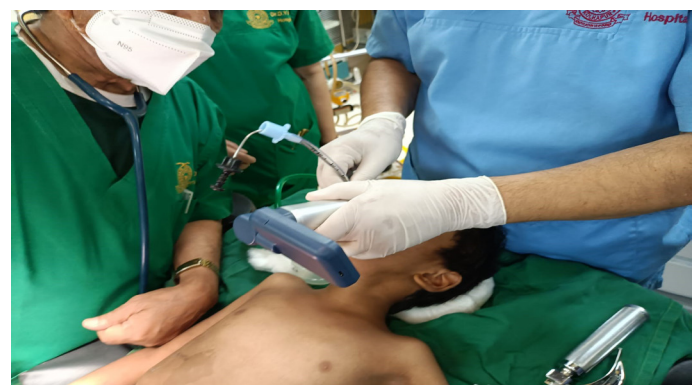Child was taken into operation theatre after adequate nbm and informed consent taken from parents and all multipara monitors attached.

- Difficult airway cart and emergency drugs were kept ready.
- Patient was given general anaesthesia as follows.
- The child was pre-medicated with IV Midazolam 0.05mg/kg and IV Glycopyrrolate 4ug/kg and anaesthesia was induced with 2ug/kg IV Fentanyl and 2 mg/kg IV Propofol. After confirming mask ventilation, pt was intubated with 5 no cuffed tube using video laryngoscope, b/l air entry checked and tube was fixed.
- Patient was ventilated with jackson reis circuit on o2 and air with sevoflurane and atracurium (0.5mg/kg).
- Patient was put in left lateral position for right lung decortication.
- Ports were introduced co2 insufflation done after which patient developed bradycardia and there was fall in saturation immediately co2 was stopped ,ports removed , patient ventilated with 100% o2 and later VATS on right side was converted to open, afterwhich surgery was uneventfull.
- Left side decortication was done through VATS which was uneventful.

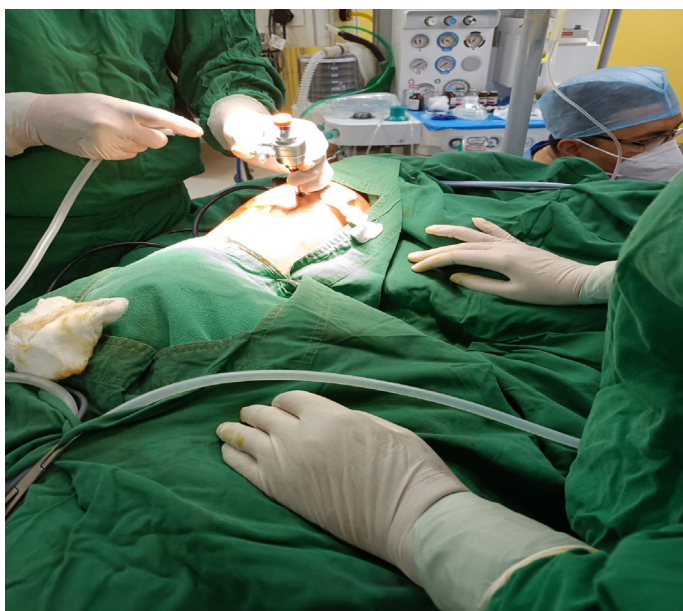For post operative pain management epidural catheter was placed on the right side at the surgical site between skin and muscle and a test dose with 0.25% bupivacaine was given, adequate analgesia achieved and erector spine block was given on left side for post operative pain management.



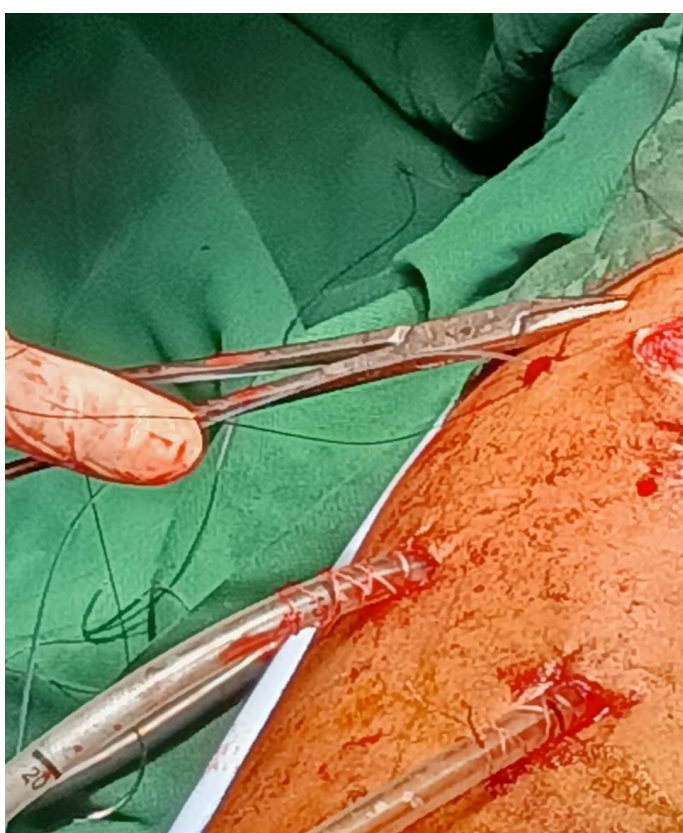
Final Position of Child



Child Video Laryngoscope



Epidural Catheter

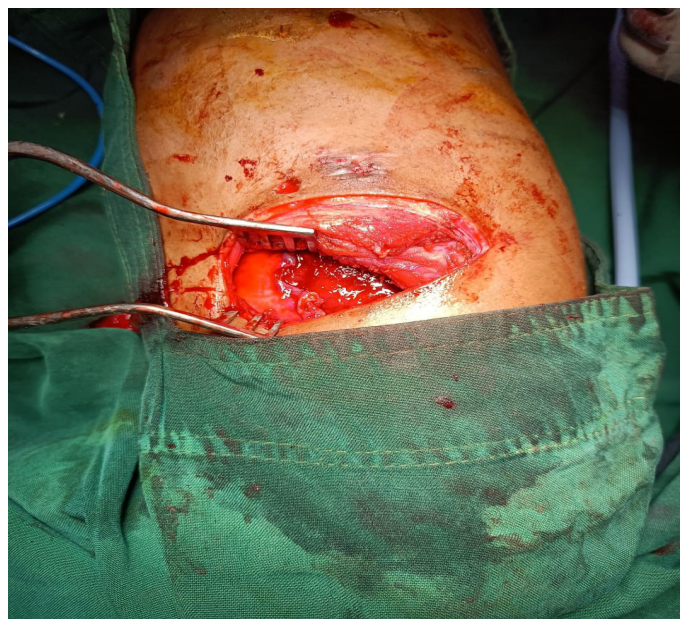

Discussion

The aim of surgical treatment for fibropurulent and organised phases of empyema thoracis is to drain all loculated collections and enable full lung re-expansion by removal of pleural peel from the lung surface. Antibiotics, pigtail insertion, and tube thoracostomy still play acceptable roles in the initial management of empyema. However, by these methods, minimal success is reported that (36-65%) of the patients are not cured, even with a prolonged hospital stay and morbidity

VATS, a procedure that is more effective than tube drainage, is an attractive alternative for treating empyema. Age, malignancy, chronic lung disease, chronic renal insufficiency, liver cirrhosis, polymicrobial infection, and positive bacterial culture are significant risk factors for mortality, while VATS can be performed on patients with all the comorbidities without much mortality

Main reason for failure of conservative methods is multiloculations, dense adhesion and restrictive pleural peel. Because of dense adhesions and technical difficulties conversion to open thoracotomy was done.



Conclusion

ONCLUSION Video assisted thoracoscopic surgery is a safe and effective procedure to treat empyema thoracis, when tube thoracostomy fails or if the empyema is loculated with dense pleura. All the stages of empyema can effectively and safely be treated by VATS. Empyema at later stages can be treated effectively with VATS. Open thoracotomy should be reserved when VATS fails as thoracotomy, as it leads to more morbidity and prolongs the hospital stay

Our experience in this case, leads us to conclude that appropriate choice of anaesthesia is essential for outcome of the patient. Epidural analgesia for thoracic surgeries in conjunction with general anaesthesia, is effective as it reduces surgical stress, decreases anaesthetic requirement, and helps extubation on table with faster recovery.

References

1. Di Napoli G, Ronzini M, Paradies G. VATS: First step in the parapneumonic empyema. *G Chir.* 2014; 35: 146-48.
2. Waller DA, Rengarajan A. Thoracoscopic decortication: A role for video-assisted surgery in chronic post pneumonic pleural empyema. *Ann Thorac Surg.* 2001; 71: 1813-1816.
3. Shin JA, Chang YS, Kim TH, Haam SJ, Kim HJ, Ahn CM, et al. Surgical decortication as the first-line treatment for pleural empyema. *J Thorac Cardiovasc Surg.* 2013; 145: 933-939.