



Combined lumbar-sacral plexus block for surgical anesthesia in high risk patients (ASA grade III/IV) undergoing lower limb surgeries

Rupal B Shah¹; Shruti B Desai^{2*}; Vidhi A Gajjar³; Dhvani Soni⁴; Vishal Prajapati⁵

¹Associate Professor, Department of Anesthesia, AMC MET Medical College, Ahmedabad, Gujarat, India

²Senior Resident, Department of Anesthesia, AMC MET Medical College, Ahmedabad, Gujarat, India

³Assistant Professor, Department of Anesthesia, AMC MET Medical College, Ahmedabad, Gujarat, India

⁴Second year Resident, Department of Anesthesia, AMC MET Medical College, Ahmedabad, Gujarat, India

⁵First year Resident, Department of Anesthesia, AMC MET Medical College, Ahmedabad, Gujarat, India

***Corresponding Author(s): Shruti B Desai**

301, suvidha park flats, opp. New madhavpura market,
 SHAHIBAG road, SHAHIBAG, Ahmedabad, Gujarat,
 India. Pin code- 380004
 Tel: +91-9429-525-791; Email: shru30791@gmail.com

Abstract

Background and aims: The use of peripheral nerve blocks has been an effective method of anesthesia and postoperative analgesia in high risk patients undergoing lower limb surgeries. The application of combined lumbar plexus and sacral plexus blocks for lower limb surgeries has been introduced with comparable efficacy to neuraxial anesthesia and with less complications, better homeostasis and hemodynamic control than the general anesthesia. This study aims to demonstrate the efficacy and safety of the use of combined lumbar and sacral plexus block in patients belonging to ASA grade III/IV for surgeries involving the lower limb.

Material and methods: 50 patients of age >18 years and weight \geq 50 kg belonging to American Society of Anesthesiologists(ASA) physical status III/IV posted for lower limb surgeries were selected. Each patient was given Inj. Bupivacaine 0.5% 12.5 ml + Inj. Lignocaine+adrenaline 1.5% 12.5 ml + Inj. Dexamethasone 4 mg in lumbar plexus block and Inj. Bupivacaine 0.5% 10 ml + Inj. Lignocaine+adrenaline 1.5% 10 ml + Inj. Dexamethasone 4 mg in sacral plexus block. The onset and duration of sensory and motor blockade for both blocks, intraoperative hemodynamic monitoring and duration of postoperative analgesia was observed in all the patients.

Results: The perioperative heart rate and mean arterial pressure were within 20% of baseline for all the patients and the duration of postoperative analgesia was 14 ± 2.17 hours.

Conclusion: Combined lumbar- sacral plexus block is a safe and efficient method of anesthesia for lower limb surgeries in high risk patients as it avoids the complications of general and neuraxial anesthesia and provides stable perioperative hemodynamics and prolonged postoperative analgesia.

Received: Jan 30, 2020

Accepted: Mar 01, 2020

Published Online: Mar 03, 2020

Journal: Annals of Anesthesia and Pain Medicine

Publisher: MedDocs Publishers LLC

Online edition: <http://meddocsonline.org/>

Copyright: © Desai SB (2020). *This Article is distributed under the terms of Creative Commons Attribution 4.0 International License*

Keywords: Lumbar plexus block; Sacral plexus block; Lower limb surgeries; High risk patients

Cite this article: Shah RB, Desai SB, Gajjar VA, Soni D, Prajapati V. Combined lumbar-sacral plexus block for surgical anesthesia in high risk patients (ASA grade III/IV) undergoing lower limb surgeries. *Ann Anesth Pain Med* 2020; 3(1): 1008.



Introduction

Conventionally, regional anesthesia is the most commonly used method of anesthesia for lower limb surgeries and the most common mode of regional anesthesia used is neuraxial anesthesia (spinal/epidural).

Studies have shown the benefits of using regional anesthesia in lower limb surgeries as compared to the use of general anesthesia in terms of a significant reduction in the number of complications like the airway instrumentation and manipulation, venous thromboembolism, respiratory complications and has advantage of early resumption of oral intake postoperatively which is critical in management of diabetic patients. However, neuraxial anesthesia itself has several disadvantages such as perioperative hemodynamic instability, urinary retention, epidural hematoma to name a few. Sometimes these may also lead to consequences like myocardial infarction, stroke and CNS infection. Neuraxial anesthesia may also not be appropriate in patients of ASA grade III/IV due to hemodynamic instability.

The use of peripheral nerve block is very popular for upper limb surgeries as the blockade of only brachial plexus can provide reliable anesthesia of the entire limb. However for lower limb two separate nerve plexuses namely the lumbar and sacral plexus need to be blocked, which are deep seated and require a larger volume of local anesthetics for reliable blockade. For this reason lower limb surgeries under peripheral nerve block was not a popular choice in the past.

However, with the use of newer techniques such as ultrasound and peripheral nerve stimulator in regional anesthesia, the scope of anesthesia has shifted from general and neuraxial anesthesia to peripheral nerve blocks for isolated limb surgery. Peripheral nerve blocks also provide postoperative pain relief which contributes to improved patient satisfaction, stable hemodynamics, early ambulation, decreased length of hospital stay and hospital cost.

Lumbar plexus block results in blockade of the femoral nerve, lateral femoral cutaneous nerve and the obturator nerve while the sacral plexus block results in blockade of the sciatic nerve, posterior cutaneous nerve of thigh, superior and inferior gluteal nerves, pudendal nerve, pelvic splanchnic nerve, inferior hypogastric plexus and the terminal portion of sympathetic trunk.

Thus, the use of combined lumbar plexus and sacral plexus blocks produces complete anesthesia of the ipsilateral lower limb with stable hemodynamics in the perioperative period and excellent postoperative analgesia.

Material and methods

After taking the written informed consent of the patients, 50 patients of ASA grade III/IV (age >18 years) and weight \geq 50 kg posted for unilateral limb surgeries were selected for the study.

Exclusion criteria:

- Patients age < 18 years
- Weight < 50 kg.
- Patients with allergy to local anesthetics
- Local infection at the site of the block

- Refusal of patient
- Patients having coagulopathy
- Patients undergoing bilateral lower limb surgery

All the patients were thoroughly examined and investigated on the day before the surgery and were explained the VAS score for the assessment of postoperative analgesia. Alternative plan of anesthesia was also explained to the patient in case of failure and those cases were excluded from the study.

All the patients were kept NBM for atleast 6 hours prior to the surgery.

After taking the patient inside the operation room an intravenous cannula was inserted and intravenous fluid started. The baseline vitals including the heart rate, blood pressure, SPO₂ were noted.

Before positioning, conscious sedation was achieved by giving titrated dose of iv Midazolam 0.02 mg/kg and iv Fentanyl 1 μ g/kg and supplemental oxygen was given by venti mask.

The patient was then positioned in the lateral decubitus position with the operative limb in the nondependent position.

After proper antiseptic and aseptic precautions the landmarks for the lumbar- sacral plexus blocks were marked with the help of a sterile marker and the skin was infiltrated with local anesthetic at the sites of needle entry. The plexus were located with the help of 20G 4 inch stimulating needle and peripheral nerve stimulator.

Capdevila's approach for lumbar plexus

In this first a line joining the spinous processes was drawn. Then the posterior superior iliac spine (PSIS) was marked and a line parallel to the first line was drawn cranially from the PSIS. Then the intercrystal line (line joining the highest point of the two iliac crests) was drawn. The junction between the medial two thirds and lateral one thirds of the segment of the intercrystal line between the first two lines is the point of entry for the lumbar plexus block. The stimulating needle was introduced at this point (with the nerve stimulator set at a current of 1.5 mA and 0.1 millisecond impulse duration at a 1 Hz frequency) till the transverse process was hit. The needle was then advanced not more than 1-2 cm deep to the transverse process either caudally or cranially by the "walked off" technique until the twitches of the quadriceps femoris muscle was obtained. The current in the nerve stimulator was gradually decreased to 0.5 mA. To avoid intraneural injection contractions provoked by < 0.3 mA were not accepted. Then Inj. Bupivacaine 0.5% 12.5 ml + Inj. Lignocaine+adrenaline 1.5% 12.5 ml + Inj. Dexamethasone 4 mg was given after negative aspiration at every 3 ml.

Approach for Sacral plexus block

It was performed with the patient in the same position. In this the stimulating needle was introduced perpendicular to the gluteal muscle at the junction of the upper one third and lower two thirds of the line joining the PSIS and the ISCHIAL TUBEROSITY and if it hits the sacral plate, the needle tip was not advanced more than 1.5-2 cm. The response was observed in the form of plantar/ dorsi flexion of the foot. Then Inj. Bupivacaine 0.5% 10 ml + Inj. Lignocaine+adrenaline 1.5% 10 ml + Inj. Dexamethasone 4 mg was given after negative aspiration.

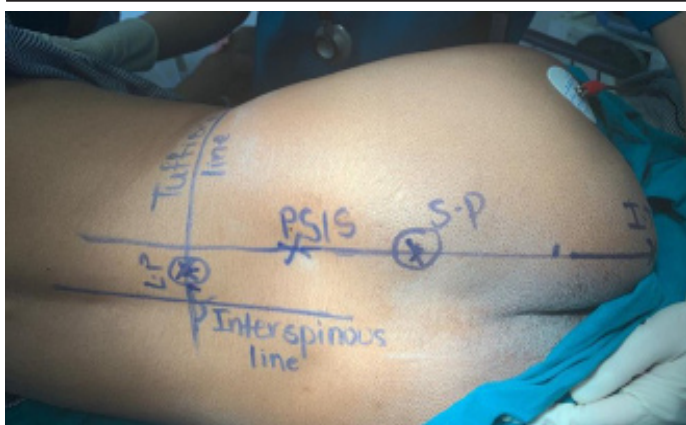


Figure 1: Anatomical landmarks of the lumbar plexus and sacral plexus block

Evaluation

Onset of sensory blockade was defined as the time from the injection of the study drug to the loss of pinprick sensation over the site of incision.

Onset of motor blockade was defined as the time from the injection of the study drug to the inability to extend the knee in case of lumbar plexus block and the inability to dorsi/plantar flex the ankle joint for the sacral plexus block.

The Sensory blockade was assessed over the operative limb at the site of incision by

3 point scale:

- Grade 0 = normal sensation
- Grade 1 = loss of sensation of pinprick (analgesia)
- Grade 2 = loss of sensation of touch (anesthesia)

The Motor blockade was assessed by:

For lumbar plexus block- inability of the patient to extend the knee joint

For sacral plexus block- inability of the patient to dorsiflex/ plantarflex the ankle joint

The patients were observed for intraoperative vitals and perioperative complications. Intraoperative vitals (HR, MAP, and SpO₂) were monitored every 5 minutes for 30 minutes and then every 10 minutes till the end of surgery.

The onset of sensory and motor blockade were noted.

The duration of surgery was also noted.

Postoperative hemodynamic parameters (HR, MAP, SpO₂) were monitored every half hourly till first 2 hours, then every 2 hourly for till 16 hours and then every 4 hourly till 24 hours after surgery.

Postoperative pain was assessed by VAS and rescue analgesia was given when VAS > 4. Duration of postoperative analgesia was noted.

Patients were observed for perioperative complications such as arrhythmia, hypotension, convulsion, intrathecal and epidural injections of the local anesthetic and neuropathy.

Observations and results

Table 1: Demographic data, ASA classification and duration of surgery

Data	Mean ± SD
Age	61.72 ± 15.05
Sex (M/F)	37/13
Weight	60.40 ± 10.58
ASA physical status(III/IV)	40/10
Duration of surgery	80.00 ± 31.93

Table I shows the demographic data, the ASA classification and the duration of surgery.

Table 2: Perioperative heart rate

Variation in heart rate from baseline (%)	Number of patients
Decrease by more than 20%	0
Decrease by 10 – 20 %	5
Within 10 % of baseline	43
Increase by 10 – 20 %	2
Increase by more than 20%	0

Table II shows the perioperative variation in the heart rate from the baseline.

Table 3: Perioperative mean arterial pressure (MAP)

Variation in the MAP from baseline (%)	Number of patients
Decrease by more than 20%	0
Decrease by 10 – 20 %	5
Within 10 % of baseline	44
Increase by 10 – 20 %	1
Increase by more than 20%	0

Table III shows the perioperative variation in the mean arterial pressure from the baseline.

Table 4: Block characteristics

Characteristics	Lumbar plexus	Sacral plexus
Sensory onset (minutes)	18.50 ± 5.30	16.20 ± 4.50
Motor onset (minutes)	20.50 ± 6.45	19.65 ± 4.30
Duration of motor blockade (hours)	11 ± 2.5	10 ± 2

Table IV shows the time of sensory onset, time of motor onset and the duration of motor blockade of the lumbar and sacral plexus blocks

The mean period of postoperative analgesia was found to be 14 ± 2.17 hours after which the patients experienced pain for which analgesics were given in the form of Inj. Tramadol 50 mg iv.

There were no perioperative complications except for the epidural injection of the local anesthetic in one patient for which the patient was managed accordingly and that patient was excluded from our study.

Discussion

High risk patients undergoing lower limb surgeries require more attention due to their physical status. General anesthesia and neuraxial anesthesia would result in higher complications due to the significant physiological changes and would also delay the postoperative recovery of these patients. Therefore, regional anesthesia in the form of combined lumbar and sacral plexus block provides effective unilateral limb anesthesia along with lesser physiological changes and better postoperative analgesia, making it a better alternative.

In the present study we have used combined lumbar and sacral plexus block as a method of anesthesia for the ASA grade III/IV patients undergoing unilateral lower limb surgery.

- **Safety and effectiveness**

Petchara et al [1] had concluded in the study that combined lumbar sacral plexus block is a safe and effective procedure for the perioperative pain control as a standard anesthetic method.

Adali et al [2] in their study had concluded that considering the possible co-morbidities, such as hypertension, diabetes mellitus, ischemic heart disease, chronic obstructive pulmonary disorder, chronic renal insufficiency etc, combined lumbar and sacral plexus block is a safe and effective method of anesthesia as compared to spinal anesthesia in these patients.

Ho et al [3] in their study on combined paravertebral lumbar plexus and parasacral sciatic nerve block for reduction of hip fracture in a patient with severe aortic stenosis also concluded that lumbar plexus can be used as the first choice in elderly, critically ill or hemodynamically compromised patients.

Malik et al [4] concluded that the combined use of psoas compartment and sciatic nerve block enabled early ambulation, decrease in the hospital costs and prevention of perioperative morbidity due to prolonged hospital stay.

- **Onset of sensory and motor block**

In our study the onset of sensory and motor block for lumbar plexus block was 18.50 ± 5.30 minutes and 20.50 ± 6.45 minutes respectively.

The onset of sensory and motor blockade in the study by Kundu et al [5] by psoas compartment block using nerve stimulation was 18.07 ± 2.165 and 33.22 ± 4.569 minutes respectively.

- **Complications**

Amiri et al [6] found that frequent negative aspiration during injection, suspension of injection against resistance and $<0.3\text{mA}$ twitch response are three important key factors to avoid major complications in lumbar plexus block. There was no evidence of any complication in our study.

Horasanli et al [7] in their study showed that contralateral extension of the analgesia suggesting an epidural spread of the local anesthetic is a well-recognized complication of the lumbar plexus block. In our study epidural spread of the local anesthetic occurred in one patient which was excluded from the study.

- **Postoperative analgesia**

Bansal et al [8] in their study showed that combined femoral and sciatic nerve block provides a postoperative analgesia of

about 12-13 hours which is comparable to our study where the postoperative analgesia is for 14 ± 2.17 hours.

Baddoo et al [9] also concluded that peripheral nerve block is an effective technique of anesthesia for lower limb amputation in diabetic patients providing cardiovascular stability and good postoperative analgesia.

- **Hemodynamic stability**

Macel et al [10] in their study concluded that a combined psoas compartment and sciatic nerve block did not affect or marginally affected (i.e. the values remained within an acceptable range of $< 10\%$ variability) the cardiac index and the hemodynamic parameters. In the present study, there was no sudden or intense variation in the hemodynamic parameters.

Adali et al [2] had concluded that combined lumbar plexus and sciatic nerve block causes limited hemodynamic effects compared to spinal anesthesia as it minimally affects the hemodynamic balance and does not affect the regional blood circulation in the extremity.

Diwan S et al [11] in their study on using combined lumbar and sacral plexus block for repair of hip fracture concluded that the combined block provides stable hemodynamics in the perioperative period and excellent postoperative analgesia.

Conclusion

Administration of anesthesia for any surgery should be such that it meets the demands of the surgery, patient comfort and proficiency of anesthetist. Combined lumbar and sacral plexus block is a simple, safe and efficient mode of anesthesia with the advantages of perioperative stable hemodynamics, prolonged postoperative analgesia, early mobilization, shorter hospital stay and lesser costs.

In nutshell, combined lumbar and sacral plexus block is a beneficial alternative to neuraxial and general anesthesia for high risk patients undergoing unilateral lower limb surgeries.

References

1. Petchara S, Paphon S, Vanlapa S. Combined lumbar sacral plexus block in high surgical risk geriatric patients undergoing early hip fracture surgery. *Malays Orthop J.* 2015; 9: 28-34.
2. Adali S, Erkalp K, Erden V, Colmeck M, Bulbul M, et al. Aldem T. Spinal anesthesia and combined sciatic nerve/lumbar plexus block techniques in lower extremity orthopedic surgery. *Acta Orthop Traumatol Turc* 2011; 45: 225-232.
3. Ho AM, Karmakar MK. Combined paravertebral lumbar plexus and parasacral sciatic nerve block for reduction of hip fracture in a patient with severe aortic stenosis. *Can J Anaesth* 2002; 49: 946-50.
4. Malik S, Krishna D, Malik S. Combined psoas compartment and sciatic nerve block for lower limb surgery: An alternative anesthetic option in high risk geriatric patients. *Karnataka Anesthesia Journal.* 2015; 1: 85-88.
5. Kundu S, Mukherjee M, Bhattacharya D. A comparative study of spinal bupivacaine and fentanyl versus combined lumbar plexus and sciatic nerve block in lower limb orthopedic procedures. *Indian J Pain* 2016; 30:189-93.
6. Amiri HR, Zamani MM, Safari S. Lumbar plexus block for management of hip surgeries. *Anesth Pain Med.* 2014; 4: e19407.
7. Horasanli E, Gamli M, Pala Y. A comparison of epidural anesthesia

-
- and lumbar plexus- sciatic nerve blocks for knee surgery. Clinics (Sao Paulo) 2010; 65: 29-34.
8. Bansal L, Joginder Pal Attari, Verma P. Lower limb surgeries under combined femoral and sciatic nerve block. Anesth Essays Res 2016;10: 432-436
 9. HK Baddoo. A preliminary report on the use of peripheral nerve blocks for lower limb amputations. Ghana Med J 2009; 43: 24-28.
 10. Macel de Leeuw, Slagt C, Hoeksema M. Hemodynamic changes during a combined psoas compartment – sciatic nerve block for elective orthopedic surgery. Anesth Analg 2011; 112: 719-724.
 11. Diwan S, Pradhan C, Patil A, Puram C, Sancheti P. Combined lumbar and sacral plexus block in geriatric high risk patients undergoing an awake repair of fracture intertrochanteric of femur. Journal of Anaesthesia and Critical care case reports 2018; 4: 21-30.